

## Original Research Article

# Experimental Model of Ligature-Induced Periodontitis in C57BL/6 Mice

García-Arévalo Fernando<sup>1\*</sup>, Serafín-Higuera A. Nicolás<sup>2</sup>, Gómez-Flores Mara<sup>1</sup>, Fuchen-Ramos Dulce Martha<sup>1</sup><sup>1</sup>Facultad de Odontología, Universidad Autónoma de Baja California, Mexicali, Zotoluca s/n, Calafia, 21040<sup>2</sup>Ciencias de la Salud, Universidad Autónoma de Baja California, Mexicali. Calle De La Claridad S/N, Col, Plutarco Elías Calles, 21376

## Article History

Received: 29.08.2024

Accepted: 07.10.2024

Published: 18.12.2024

## Journal homepage:

<https://www.easpublisher.com>

## Quick Response Code



**Abstract:** Periodontitis is a chronic inflammatory disease that leads to the destruction of the supporting structures of teeth, primarily due to bacterial infection and immune response. The ligature-induced periodontitis (LIP) model is commonly used to replicate this condition in experimental settings, facilitating the study of inflammation and bone loss as well as testing therapeutic strategies. In this study, we aimed to establish an experimental ligature-induced periodontitis model in mice and evaluate the extent of alveolar bone loss over a 10-day period and discuss advantages and limitations. Eight 10-week-old pathogen-free C57BL/6 male mice were divided into two groups: an experimental group (n=4) with ligature placement and a control group (n=4) without ligature. Under sedation, a silk suture (6-0) ligature was placed around the maxillary second molar (M2) of the experimental group to induce bacterial accumulation, gingival inflammation, and bone resorption over 10 days. Bone resorption was confirmed through microscopic analysis. The experimental group demonstrated a significant increase in alveolar bone loss compared to the control group. The average distance from the cemento-enamel junction (CEJ) to the alveolar bone crest (ABC) was greater in the ligature group, while no bone loss was observed in the control group ( $P < 0.05$ ). These results demonstrated a clear correlation between the experimental conditions and outcomes, highlighting the murine periodontitis model as a valuable tool for studying inflammatory conditions. These findings offer insights into bone loss mechanisms and may aid in developing targeted therapies for bone resorption in periodontitis.

**Keywords:** Periodontal disease, periodontitis, ligature, murine model, bone loss, inflammation.

**Copyright © 2024 The Author(s):** This is an open-access article distributed under the terms of the Creative Commons Attribution **4.0 International License (CC BY-NC 4.0)** which permits unrestricted use, distribution, and reproduction in any medium for non-commercial use provided the original author and source are credited.

## INTRODUCTION

Periodontal disease (PD) is an inflammatory condition that leads to significant patient morbidity and carries an important public health burden. It is characterized by gingival inflammation (Gingivitis) and the loss of both soft tissue attachment and bone support around the affected teeth (Periodontitis) [1].

The prevalence of periodontal disease begins in late adolescence, reaches its highest levels around the age of 55, and remains elevated into old age. Severe periodontitis ranks as the sixth most common condition worldwide, affecting approximately 10% of the adult population. If left untreated, periodontitis causes the gradual destruction of the structures supporting the teeth, ultimately leading to tooth loss, which negatively impacts oral function and overall quality of life [1, 2].

This process is driven by interactions between the oral microbiota and the host's innate immune system. PD is also linked to other systemic inflammatory diseases, such as diabetes, cardiovascular disease, and arthritis. Evidence indicates that the microbial component of PD is mediated by the dental biofilm. The biofilm is a structured, complex community of microorganisms that can exist in both symbiotic (healthy) and dysbiotic (destructive) states. Normally, the oral biofilm helps protect the host by preventing the establishment of pathogenic bacteria and maintaining optimal gingival tissue structure and function through regulation of the immune response. Disruptions in the balance between commensal organisms in the oral cavity and the host immune system can lead to tissue homeostasis alterations, resulting in dysbiosis and the

\*Corresponding Author: García-Arévalo Fernando

Facultad de Odontología, Universidad Autónoma de Baja California, Mexicali, Zotoluca s/n, Calafia, 21040

development of clinical and radiographic features of PD [1, 3].

Different factors involved in the pathogenesis of periodontitis, such as the interaction of polymicrobial synergy, dysbiosis, chronic inflammation, and genetic susceptibility, have made finding an ideal animal model for periodontitis particularly challenging. However, various researchers have successfully simulated the impact of these factors on periodontal disease progression by breaking the process down into distinct phases. These phases include biofilm formation, bacterial colonization and invasion of periodontal tissues, triggering an imbalanced immune response from the host, and subsequent degradation of soft tissues along with alveolar bone resorption [3, 4].

Murine models offer several advantages, including a well-characterized microbiome and immune system, access to numerous genetically modified strains, and a wide availability of reagents for studying newly discovered molecules. However, challenges such as the small size of their oral cavity require highly trained operators and a large number of animals. Despite these challenges, mouse models have been highly valuable in exploring biological hypotheses related to disease pathogenesis, host-microbe interactions, and potential treatments, as they are capable of partially replicating the clinical, molecular, and histological aspects of human periodontitis. Additionally, mice used in these models are cost-effective, easy to manage, have short reproductive cycles, and consistently develop reproducible periodontal inflammation [5].

Although increased osteoclastogenesis is recognized as a critical factor in alveolar bone destruction associated with periodontitis, the exact mechanisms driving this process remain poorly understood. The ligature-induced periodontitis (LIP) model has been extensively employed to investigate the molecular and cellular pathways underlying bone destruction in this disease. In this model, the increased bacterial load resulting from the accumulation of oral commensal bacteria around silk sutures is the primary cause of periodontitis, leading to significant alveolar bone loss. Initially developed in rats and dogs, the LIP model has since been successfully adapted to mice, overcoming technical challenges and benefiting from the availability of a wide array of genetically engineered strains and disease models. This has made mice a valuable tool in advancing our understanding of the pathogenesis of periodontitis [5, 6].

The LIP model is a reliable approach for triggering rapid and predictable alveolar bone loss in mice within a matter of days. The technique involves positioning silk, nylon or nickel-titanium ligatures around the molars of the upper or lower jaw while the animal is under anesthesia. These ligatures encourage bacterial buildup, leading to periodontal inflammation

and subsequent bone degradation. Observable differences in alveolar bone loss between control and ligated mice begin as early as day 5, with progressively larger discrepancies seen by days 10 and 15 [7].

Although this model has been widely employed in mice studies, the extremely small size of their oral cavity and the tiny interproximal spaces between the molars pose a technical challenge for proper ligature placement [8]. The aim of this study is to establish an experimental ligature-induced periodontitis model in mice and to evaluate the extent of alveolar bone loss over a 10-day period, as well as discuss the advantages and limitations of the model.

## MATERIALS AND METHODS

### Experimental Model of Ligature-Induced Periodontitis

Eight 10-week-old pathogen-free male C57BL/6 mice, weighing 20-25 g, with no clinical signs of active periodontal disease, were used for this study. The mice were housed under ad libitum light/dark cycles in the temporary animal facility. The mice were randomly divided into two groups: an experimental group with ligature placement (n=4) and a control group without ligature (n=4).

### Anesthesia Protocol and Ligature Placement

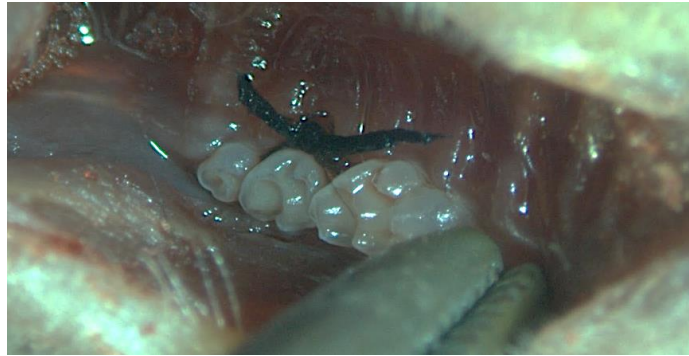To induce experimental periodontitis, the mice were anesthetized via intraperitoneal administration of a mixture of ketamine (100 mg/kg) and xylazine (10 mg/kg), ensuring rapid and reliable sedation for the duration of the procedure. A sterile 6-0 silk suture was carefully placed around the maxillary second molar (M2) of the experimental group under a stereomicroscope at 8x magnification (Image 1). This ligature was designed to promote bacterial accumulation, dysbiosis, gingival inflammation, and subsequent bone resorption. The control group did not receive any ligature.

### Postoperative Care and Monitoring

Following the procedure, the mice were monitored until full recovery from anesthesia, which was confirmed by the return of the righting reflex and ambulatory behavior. The mice were inspected daily for any signs of distress or complications, and food and water were provided ad libitum throughout the 10-day experimental period.

### Tissue Collection and Bone Loss Evaluation

After 10 days, all mice were euthanized by cervical dislocation according to the approved protocols of the Institutional Animal Care and Use Committee (FMM/CEI-FMM/014/2023-1). The maxillary jaws were dissected, and the soft tissues were carefully removed using mechanical means and treated with 30% hydrogen peroxide for 16 hours to completely clear any remaining soft tissue. The jaws were then stained with 3% methylene blue for 30 minutes to enhance the visibility of the alveolar bone.



**Image 1: A ligature composed of silk suture material (6-0) was placed around the maxillary second molar (M2) to induce bacterial accumulation and dysbiosis, resulting in gingival inflammation and bone resorption after 10 days. The ligature was observed under a microscope at 8x magnification**

### Bone Loss Quantification

Bone loss was quantified by measuring the linear distance between the cemento-enamel junction (CEJ) and the alveolar bone crest (ABC) at three points on each molar, both buccally and palatally. Measurement and images were obtained using a millimeter scale ruler under a stereomicroscope StemiDV4 (Zeiss) with a camera AxioCamERc5s (Zeiss) and the Blue Zen software (Zeiss). Image analysis was performed using ImageJ software to ensure accuracy in the quantification of bone loss.

### Statistical Analysis

The statistical analysis of bone loss was performed using GraphPad Prism 8.0.1 software. An unpaired two-tailed Student's t-test (parametric) was used to compare bone loss between the ligature and control groups. Asterisk indicates statistical significance ( $P < 0.05$ ).

## RESULTS AND DISCUSSION

Throughout the 10-day experimental period, all mice in both the control and ligature groups showed no signs of distress or complications. The experimental group with ligatures exhibited noticeable gingival inflammation by day 5, which continued to progress until the end of the study. In contrast, the control group

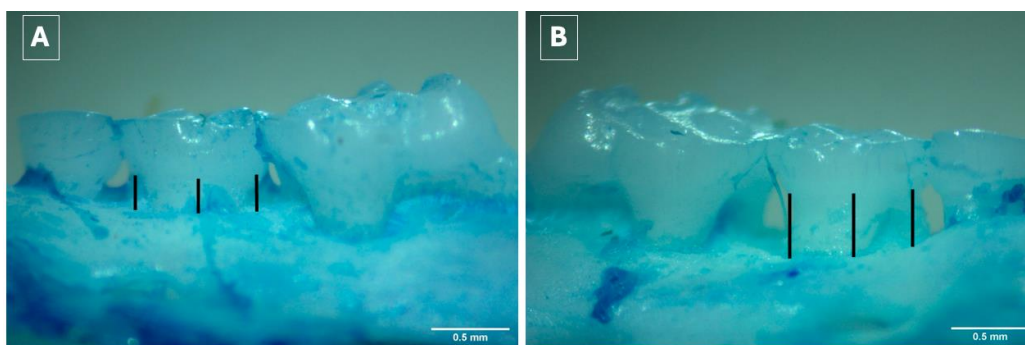
without ligatures showed no visible signs of inflammation or tissue damage.

### Microscopic evaluation of the maxillary molars

Microscopic evaluation of the maxillary molars using a stereoscope confirmed the clinical observations of bone resorption. In the control group, the alveolar bone remained intact, with minimal changes in height relative to the CEJ. In contrast, the ligature group showed clear signs of alveolar bone loss, with the bone crest significantly receded from the CEJ. Representative images of the stained maxillary bones are shown in (Image 2), where the extent of bone loss is clearly visible in the ligature group.

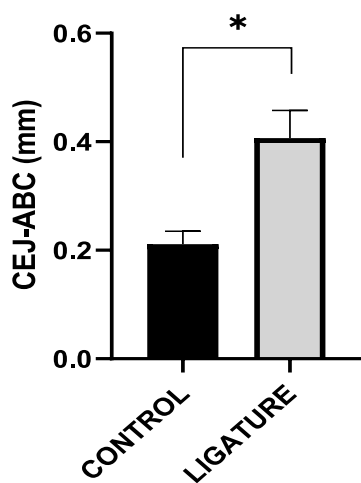
### Bone Loss and quantification

The bone loss was quantified by measuring the linear distance between the cemento-enamel junction (CEJ) and the alveolar bone crest (ABC) at three points for each molar. Mice in the ligature group demonstrated significant alveolar bone loss compared to the control group. On average, the distance from the CEJ to the ABC in the ligature group in the control group was  $0.406 \text{ mm} \pm 0.05$  (SD) compared to  $0.211 \text{ mm} \pm 0.23$  (SD) ( $P < 0.05$ , unpaired two-tailed Student's t-test). These findings confirm the effectiveness of the ligature-induced periodontitis model in promoting rapid alveolar bone degradation (Image 2 and 3).



**Image 2: Fig. A presents a palatal view (32x) of the murine maxilla without the experimental ligature, where the alveolar bone crest is at a normal level relative to the cemento-enamel junction, marked by lines. Fig. B, in contrast, shows a palatal view of the murine maxilla 10 days after the placement of an experimental ligature, with a clear reduction in alveolar bone height and horizontal bone loss relative to the cemento-enamel junction, as indicated by the lines**

The results demonstrated a statistically significant increase in bone resorption in the ligature group ( $P < 0.05$ ), confirming the impact of the ligature on periodontal destruction (Image 3).



**Image 3: Quantification of bone loss. CEJ, cemento-enamel junction. ABC, alveolar bone crest. mm, millimeters, Statistical significance set at \*  $P < 0.05$**

In this study, we utilized eight pathogen-free 10-week-old male C57BL/6 murine models, none of which exhibited clinical signs of active periodontal disease at baseline. The mice were housed in a temporary animal facility under ad libitum light/dark cycles to ensure appropriate acclimation before experimentation. The study design involved two groups: an experimental group ( $n = 4$ ) subjected to ligature placement and a control group ( $n = 4$ ) without ligature.

The combination of ketamine (100 mg/kg) and xylazine (10 mg/kg) provided rapid and reliable anesthesia, allowing us to perform the ligature placement without complications. This standardized protocol ensured that all subjects in both groups underwent the same preparation and handling, minimizing variability due to external factors [9, 10].

Increase in the cemento-enamel junction to alveolar bone crest (CEJ-ABC) distance was observed. These findings underscore the temporal relationship between osteoclast activity and bone loss in the murine ligature model of periodontal disease, providing valuable insights into the dynamic process of bone remodeling in response to periodontal stress. These results are consistent with previous studies, such as those by Kittaka [11], further emphasizing the complex mechanisms involved in periodontal bone changes.

In this study, we were able to observe the onset and development of periodontitis within a 10-day period, confirming the rapid progression of this disease in our model. We employed the well-established ligature-induced periodontitis (LIP) model, which has been

extensively documented in previous research. While other studies have introduced variables such as lipopolysaccharide (LPS) injections or used alternative materials besides silk, we deliberately chose not to include any additives or different ligature materials [14]. Silk was selected for its well-known capacity to be readily colonized by periodontopathogen bacteria, facilitating the rapid onset of inflammation and destruction of supporting tissues. This accelerated progression contrasts with the slower development of periodontitis observed in humans [14, 15].

The rapid progression of periodontitis observed in murine models, compared to humans, can be explained by key differences in immune responses and the composition of the oral microbiota. In mice, the immune system typically mounts a faster and more intense inflammatory response to bacterial accumulation, leading to more immediate tissue destruction and bone loss. Furthermore, the oral microbiota in mice may be more predisposed to support the growth of periodontopathogen bacteria, facilitating the swift development of periodontal disease. In humans, by contrast, periodontitis tends to progress more slowly due to the complex interplay of host immune responses, environmental factors, and lifestyle habits, which often result in a more gradual immune reaction. Additionally, the shorter lifespan and quicker metabolic rate of mice contribute to the condensed timeline of disease progression, making them an ideal model for studying the acute phases and early events of periodontitis over a relatively short experimental period [16].

The LIP model in mice is widely employed to investigate the mechanisms underlying periodontal disease. However, the progression of disease in mice may not fully mirror the pathophysiology of human adult periodontitis. While the LIP model successfully induces inflammation and bone loss by promoting plaque accumulation around ligated teeth, human periodontitis is a chronic condition that evolves over years, driven by a complex interplay between bacterial infection, host immune responses, and environmental factors. Furthermore, there are significant anatomical differences between murine and human periodontal tissues, variations in immune responses, and the shorter lifespan of mice, which all limit the extrapolation of findings from murine models to human periodontitis. Consequently, caution is needed when interpreting data from these models, and complementary studies are essential to fully understand the disease mechanisms in humans [5, 19].

Although murine models simulate key aspects of periodontal inflammation and bone loss, notable differences in immune response pathways such as cytokine and chemokine signaling and oral microbiota composition highlight the challenges of using these models for human disease. Additionally, the more acute disease progression in mice contrasts with the prolonged

and complex course of human periodontitis, which involves ongoing tissue destruction and immune dysregulation. Anatomical differences, particularly in the structure of the periodontal ligament and the capacity for alveolar bone regeneration, further complicate the direct translation of murine data to human periodontitis [18-20].

The induction of periodontitis in murine models holds significant importance for advancing our understanding of periodontal disease and its associated inflammatory processes. By successfully establishing a reliable and reproducible model, we are able to closely mimic the pathological features of human periodontitis, such as alveolar bone loss [17-19]. In the LIP model, bone loss occurs rapidly and predominantly in a horizontal manner. This contrasts with the bone loss observed in humans with periodontitis, which can progress more slowly and present both horizontal and vertical patterns.

The differences in the rate and pattern of bone resorption between the two species highlight the variability in periodontal disease progression and the importance of considering these factors when translating experimental findings from animal models to human clinical settings. This allows for detailed exploration of the molecular and cellular mechanisms driving the disease, offering critical insights into potential therapeutic targets for periodontitis [7].

Moreover, this murine model of inflammation extends beyond periodontal research. Chronic inflammation, as seen in periodontitis, is a hallmark of numerous systemic diseases, including cardiovascular disease, diabetes, and autoimmune disorders. The LIP model provides a controlled environment in which the inflammatory response can be studied and modulated. By targeting the pathways involved in the inflammation and bone resorption observed in periodontitis, researchers can explore novel therapeutic strategies that may have broader applications for other diseases characterized by similar inflammatory mechanisms. In this way, the murine model of periodontitis can serve as a platform for testing anti-inflammatory drugs, biologics, or other interventions aimed at reducing tissue destruction and improving disease outcomes, not only in periodontal disease but in other inflammatory conditions as well [19, 20].

## CONCLUSION

This murine model of periodontitis is a valuable tool for conducting experiments involving inflammatory conditions within a short time frame. The results support the relevance of this model to provide valuable insights into the underlying mechanisms of bone loss and could contribute to the development of targeted therapeutic strategies for conditions involving bone resorption in periodontitis.

**Acknowledgments:** The authors would like to thank CONAHCYT.

## REFERENCE

1. Isola, G., Santonocito, S., Lupi, S. M., Polizzi, A., Sclafani, R., Patini, R., & Marchetti, E. (2023). Periodontal health and disease in the context of systemic diseases. *Mediators of inflammation*, 2023(1), 9720947.
2. García-Arévalo, F., Leija-Montoya, A. G., González-Ramírez, J., Isiordia-Espinoza, M., Serafín-Higuera, I., Fuchen-Ramos, D. M., ... & Serafín-Higuera, N. (2024). Modulation of myeloid-derived suppressor cell functions by oral inflammatory diseases and important oral pathogens. *Frontiers in Immunology*, 15, 1349067.
3. Tzach-Nahman, R., Mizraji, G., Shapira, L., Nussbaum, G., & Wilensky, A. (2017). Oral infection with *Porphyromonas gingivalis* induces peri-implantitis in a murine model: Evaluation of bone loss and the local inflammatory response. *Journal of clinical periodontology*, 44(7), 739-748.
4. Li, S., Zeng, W., Liu, G., Zang, J., & Yu, X. (2023). Evaluation of morphological, histological, and immune-related cellular changes in ligature-induced experimental periodontitis in mice. *Journal of Dental Sciences*, 18(4), 1716-1722.
5. Lin, P., Niimi, H., Ohsugi, Y., Tsuchiya, Y., Shimohira, T., Komatsu, K., ... & Katagiri, S. (2021). Application of ligature-induced periodontitis in mice to explore the molecular mechanism of periodontal disease. *International journal of molecular sciences*, 22(16), 8900.
6. Wichienrat, W., Surisaeng, T., Sa-Ard-Iam, N., Chanamuangkon, T., Mahanonda, R., & Wisitrasameewong, W. (2024). Alveolar Bone Loss in a Ligature-Induced Periodontitis Model in Rat Using Different Ligature Sizes. *European Journal of Dentistry*, 18(3), 933-941.
7. Marchesan, J., Girnary, M. S., Jing, L., Miao, M. Z., Zhang, S., Sun, L., ... & Jiao, Y. (2018). An experimental murine model to study periodontitis. *Nature protocols*, 13(10), 2247-2267.
8. Kiani, A. K., Pheby, D., Henahan, G., Brown, R., Sieving, P., Sykora, P., ... & International Bioethics Study Group. (2022). Ethical considerations regarding animal experimentation. *Journal of preventive medicine and hygiene*, 63(2 Suppl 3), E255-E266.
9. David, E. M., Pacharinsak, C., Jampachaisri, K., Hagan, L., & Marx, J. O. (2022). Use of ketamine or xylazine to provide balanced anesthesia with isoflurane in C57BL/6J mice. *Journal of the American Association for Laboratory Animal Science*, 61(5), 457-467.
10. Hohlbaum, K., Bert, B., Dietze, S., Palme, R., Fink, H., & Thöne-Reineke, C. (2018). Impact of repeated anesthesia with ketamine and xylazine on the well-

- being of C57BL/6JRj mice. *PLoS one*, 13(9), e0203559.
11. Kittaka, M., Yoshimoto, T., Levitan, M. E., Urata, R., Choi, R. B., Teno, Y., ... & Ueki, Y. (2023). Osteocyte RANKL Drives Bone Resorption in Mouse Ligature-Induced Periodontitis. *Journal of Bone and Mineral Research*, 38(10), 1521-1540.
  12. Gerb, S. A., Dashek, R. J., Ericsson, A. C., Griffin, R., & Franklin, C. L. (2021). The effects of ketamine on the gut microbiome on CD1 mice. *Comparative Medicine*, 71(4), 295-301.
  13. David, E. M., Pacharinsak, C., Jampachaisri, K., Hagan, L., & Marx, J. O. (2022). Use of ketamine or xylazine to provide balanced anesthesia with isoflurane in C57BL/6J mice. *Journal of the American Association for Laboratory Animal Science*, 61(5), 457-467.
  14. Chipashvili, O., & Bor, B. (2022). Ligature-induced periodontitis mouse model protocol for studying Saccharibacteria. *STAR protocols*, 3(1), 101167.
  15. Holland, C., Numata, K., Rnjak-Kovacina, J., & Seib, F. P. (2019). The biomedical use of silk: past, present, future. *Advanced healthcare materials*, 8(1), 1800465.
  16. Dal Acqua, Y., Hernandez, C., Fogacci, M., Barbirato, D., & Palioto, D. (2022). Local and systemic effects produced in different models of experimental periodontitis in mice: A systematic review. *Archives of Oral Biology*, 143, 105528.
  17. Greene, A. C., Shehabeldin, M., Gao, J., Balmert, S. C., Ratay, M., Sfeir, C., & Little, S. R. (2022). Local induction of regulatory T cells prevents inflammatory bone loss in ligature-induced experimental periodontitis in mice. *Scientific Reports*, 12(1), 5032.
  18. Ribeiro, A. B., Santos-Junior, N. N., Luiz, J. P. M., de Oliveira, M., Kanashiro, A., Taira, T. M., ... & Salgado, H. C. (2020). Cardiovascular and autonomic dysfunction in murine ligature-induced periodontitis. *Scientific Reports*, 10(1), 6891.
  19. Rojas, C., García, M. P., Polanco, A. F., González-Osuna, L., Sierra-Cristancho, A., Melgar-Rodríguez, S., ... & Vernal, R. (2021). Humanized mouse models for the study of periodontitis: an opportunity to elucidate unresolved aspects of its immunopathogenesis and analyze new immunotherapeutic strategies. *Frontiers in Immunology*, 12, 663328.
  20. Shi, Y. T., He, J. M., Tong, Z. A., Qian, Y. J., Wang, Q. W., Jia, D. J. C., ... & Si, M. S. (2023). Ligature-induced periodontitis drives colorectal cancer: an experimental model in mice. *Journal of Dental Research*, 102(6), 689-698.

---

**Cite This Article:** García-Arévalo Fernando, Serafín-Higuera A. Nicolás, Gómez-Flores Mara, Fuchen-Ramos Dulce Martha (2024). Experimental Model of Ligature-Induced Periodontitis in C57BL/6 Mice. *EAS J Dent Oral Med*, 6(6), 117-122.

---