

## Original Research Article

## Metastatic Disease Patterns of Uterine Cervical Cancer on Computed Tomography at an Oncology Hospital in Cameroon: A Pilot Study

Joshua Tamba<sup>1, 2, 3\*</sup>, Yannick Onana<sup>4</sup>, Jean Roger Mouliom Tapouh<sup>5</sup>, Wilfried Mosse<sup>2</sup>, Vanessa Tongue<sup>6</sup>, Paul Mobit<sup>2</sup>, Emilienne Guegang<sup>7</sup>, Odile Zeh<sup>7</sup>, Boniface Moifo<sup>7</sup>

<sup>1</sup>Division of Radiology, Faculty of Health Sciences, University of Buea, Buea, Cameroon

<sup>2</sup>Cameroon Oncology Center, Douala, Cameroon

<sup>3</sup>Education and Health for All Foundation, Yaoundé, Cameroon

<sup>4</sup>Faculty of Medicine and Biomedical Sciences, University of Garoua, Garoua, Cameroon

<sup>5</sup>Faculté de Médecine et des Sciences Pharmaceutiques, University of Dschang, Dschang, Cameroon

<sup>6</sup>Faculté de Médecine et des Sciences Pharmaceutiques, University of Douala, Douala, Cameroon

<sup>7</sup>Faculty of Medicine and Biomedical Sciences, The University of Yaoundé I, Yaoundé, Cameroon

### Article History

Received: 25.03.2024

Accepted: 05.05.2024

Published: 30.12.2024

### Journal homepage:

<https://www.easpublisher.com>

### Quick Response Code



**Abstract:** Close to three-quarters (70%) of all cases of cervical cancer occur in countries with a low human development index where the burden of infections with human papilloma virus is high and screening uptake is low. The aim of this study was to assess the burden of metastatic disease from cervical cancer and the pattern of spread in a sub-Saharan African population. We extracted data from reports of computed tomography scans of the thorax, abdomen and pelvis (CT-TAP) of patients with histologically proven cervical cancer from a prospectively collected cancer imaging database from July 2022 to February 2024. Independent statistical associations were performed using Fisher's exact test whilst metastatic disease patterns were illustrated with a Sankey diagram. Data was extracted from 113 CT-TAP reports of patients. The mean age was  $59.9 \pm 12.21$  (range: 38 to 84 years). There was reported local, regional or distant spread in 53 out of 103 (46.39%) patients. Four out of 8 (50.00%) baseline scans for staging reported tumor spread, against 49 out of 105 (46.67%) follow-up scans ( $p=0.570$ ). Cancer spread was mostly local invasion than distant (59% vs. 41%). Parametrial invasion was reported in 41 cases (35.04%), followed by nodal tumor disease (32 cases; 27.35%) of which 75% was pelvic. Common sites for distant metastatic disease were the peritoneum (16 cases; 13.68%), spleen (12 cases; 10.26%) and pleurae (12 cases; 10.26%). Age-related trends in the occurrence of metastatic disease was significant with a peak at 40 to 49 years ( $p=0.001$ ). The high burden of cervical cancer spread suggests the need to intensify primordial, primary and secondary prevention strategies.

**Keywords:** Cervical cancer, metastases, patterns, computed tomography.

**Copyright © 2024 The Author(s):** This is an open-access article distributed under the terms of the Creative Commons Attribution 4.0 International License (CC BY-NC 4.0) which permits unrestricted use, distribution, and reproduction in any medium for non-commercial use provided the original author and source are credited.

## INTRODUCTION

Cancer of the uterine cervix is the fourth most common cancer globally and the fourth leading cause of all cancer-related deaths [1]. Close to 100% of all cervical cancers are linked to HPV infection, with HPV-16 and HPV-18 accounting for 70% of all cases [2, 3]. Seventy-percent of all cases occur in countries with a low human development index, low screening practices and high rates of human papilloma virus (HPV) infection [3]. The burden of cervical cancer is highest in sub-Saharan Africa (SSA) and women living with human immunodeficiency virus (HIV) infection are six times more likely to be diagnosed with cervical cancer than

those without HIV [3]. The age-standardized incidence and mortality rates vary considerably in SSA and have been either stable or increasing over the past decades [4, 5].

Imaging plays an important role in the management of cervical cancer, especially to assess tumor extent, the presence of metastatic disease and the monitoring of treatment. Ultrasonography (US), contrast-enhanced computed tomography (CT), magnetic resonance imaging (MRI) and positron-emission tomography are all used in the imaging of cervical cancer, however, with different diagnostic capabilities [6]. Computed tomography has proven to be

\*Corresponding Author: Joshua Tamba

Division of Radiology, Faculty of Health Sciences, University of Buea, Buea, Cameroon

very useful in cancer imaging. It is more accessible, quick to perform with a great diagnostic accuracy [7]. Despite its low soft tissue resolution that affects its accuracy in the assessment of local tumor spread, CT is excellent in the assessment of metastatic tumor disease [8].

Metastatic tumor spread is a predictor of poor disease prognosis [9]. Without a national screening program for HPV and hesitancy towards the recently introduced HPV vaccine in Cameroon, the incidence and mortality rates are comparably high [10]. Understanding the burden of metastatic disease in the study context can help redirect resources for the fight against cervical cancer and orientate treatment planning. The objective of this study was to assess the burden and describe the pattern of cervical cancer spread in a sub-regional one-stop-shop cancer center in Cameroon.

## METHODS

This study was a preliminary assessment of prospectively collected data on the imaging aspects of cancers at an integrated cancer-management health facility in Douala, Cameroon. Cameroon Oncology Center (COC) is a multi-faceted cancer management facility that combines both local and international expertise (United States of America, Europe and Asia) to provide the best possible care to cancer patients. The COC is a university-affiliated center for the training of residents in radiation oncology, medical and general oncology practice for all health professionals.

We extracted data from the cancer-imaging database from July 2022 to February 2024. This database consists of structured imaging reports of patients managed at the COC that are stored electronically. All CT reports of patients with a histologically proven uterine cervical malignancy during the study period were selected for review. Routinely, CT scans of the thorax, abdomen and pelvis (CT-TAP) are requested and performed either as baseline imaging (staging) or for the follow-up of treatment. All the CT scans were performed with a Philips Brilliance Big Bore 16-slice scanner. CT data acquisition was multiphasic with delayed phases. Given that data for the study was extracted from a prospectively gathered hospital record, ethical clearance was waived.

After retrieving eligible reports, duplicate studies were excluded. Just one study was selected per patient, and this was preferably the study with the most advanced disease stage. Only CT-TAP studies with

available images in digital imaging communications (DICOM) format were further selected for review.

A standardized data extraction form was created on a Microsoft Excel® spreadsheet. Variables of interest included the age of the patient, clinical indication for the scan, histologic type of the cancer, past and current treatment, and CT characteristics of the tumor (the absence or presence of local, regional or distant tumor spread). Metastatic tumor disease was assessed systematically across thirteen body organs [11]. To further confirm the findings on CT reports sample DICOM images were reviewed by two radiologists with over ten years of practice experience (YO, JRM) and the final decision was consensual. Characteristic target organ lesions were categorized as metastatic disease. For lymph node assessment, the new Response Evaluation Criteria in Solid Tumors (RECIST), version 1.1, was used [12].

We analyzed the data using the statistical software STATA® 12MP (STACORPS, TEXAS, USA). Categorical variables were summarized as counts and percentages. Statistical testing for independent association between age group as a variable and the presence of metastatic disease was done using Fisher's exact test (two-tailed), with a threshold for statistical significance set at 0.05. Metastatic disease pattern was illustrated using a Sankey diagram, with the nodes representing the relative frequency of metastasis to the specific organ.

## RESULTS

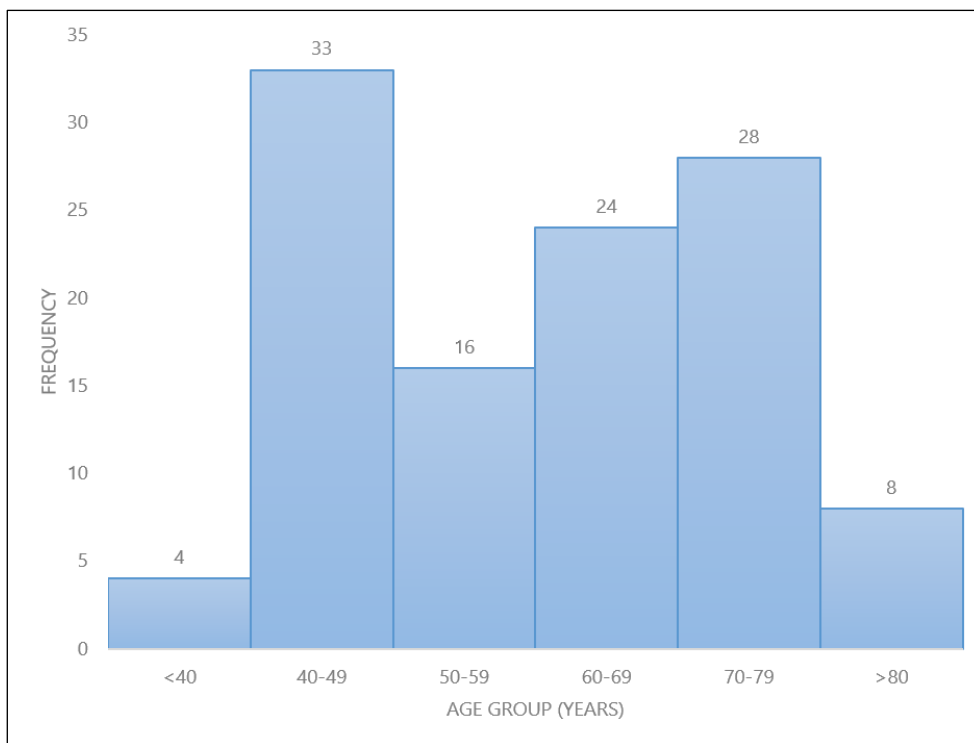
### *Age distribution*

The age distribution of the patients was generally parametric with a mean of 59.94 ( $\pm 12.21$ ) years and median of 60 years (range: 38 to 84 years). **Figure 1** shows the age distribution of the cervical cancer patients.

### *Burden and distribution of cancer spread*

Of all the 113 CT-TAP reports from which data was extracted, local or distant tumor spread was reported in 53 cases (46.90%).

Four out of the eight (50.00%) baseline scans for tumor staging showed evidence of local or distant tumor spread. For follow-up CT scans, 49 out of 105 (46.67%) showed at least a metastatic lesion. There was no statistical association in the occurrence of metastases at the baseline or follow-up CT scans ( $p=0.570$ ). The age-related trend of metastatic spread was significant (**Table I**).



**Figure 1: Age group distribution of patients with cervical cancer**

**Table I: Cervical cancer spread based on age distribution and clinical indication**

	Metastases present <i>n</i> (%)	Metastases absent <i>n</i> (%)	<i>p</i> value
Indication for CT			
Baseline	4 (50.00)	4 (50.00)	0.570
Follow-up	49 (46.67)	56 (53.33)	
Age group (years)			
<40	4 (8.16)	0 (0.00)	0.001
40-49	13 (26.53)	20 (33.33)	
50-59	12 (24.49)	4 (6.67)	
60-69	12 (24.49)	12 (20.00)	
70-79	8 (16.33)	16 (26.67)	
>80	0 (00.00)	8 (13.33)	
<i>p-values obtained using Fischer's exact test</i>			

**Pattern of cancer spread**

Local spread to the parametrium was reported in 41 cases (35.04%), followed by nodal tumor disease (32 cases; 27.35%). Nodal tumor spread was pelvic in 24

cases (75.00%), both abdominal and pelvic in 4 cases (12.5%), and a combination of thoracic, abdominal and pelvic in 4 cases (12.5%). Table II shows the frequency of organ involvement.

**Table II: Frequency distribution of cervical cancer spread**

Body organs	Metastasis present, <i>n</i> (%)	Metastasis absent, <i>n</i> (%)
Lung	8 (6.84)	109 (93.16)
Pleura	12 (10.26)	105 (89.74)
Nodes	32 (27.35)	85 (72.65)
Liver	4 (3.42)	113 (96.58)
Bone	4 (3.42)	113 (96.58)
Adrenal glands	0 (0.00)	117 (100.00)
Spleen	12 (10.26)	105 (89.74)
Peritoneum	16 (13.68)	101 (86.32)
Parametrium	41 (35.04)	76 (64.96)
Bladder neck/ureters	25 (21.37)	92 (78.63)
Rectum	4 (3.42)	113 (96.58)

There was a hypodense collection (hydrometra) within the uterine cavity in 28 cases (23.93%).

Local cancer spread was reported in 59% of the reports, and distant spread in 41%. Most of the distant

spread involved the peritoneum with ascites, the pleurae (with effusions) and spleen. Osseous and liver involvement were less frequent. Figure 2 illustrates the pattern of spread, whilst Figures 3 and 4 demonstrate imaging findings of metastatic tumor disease.

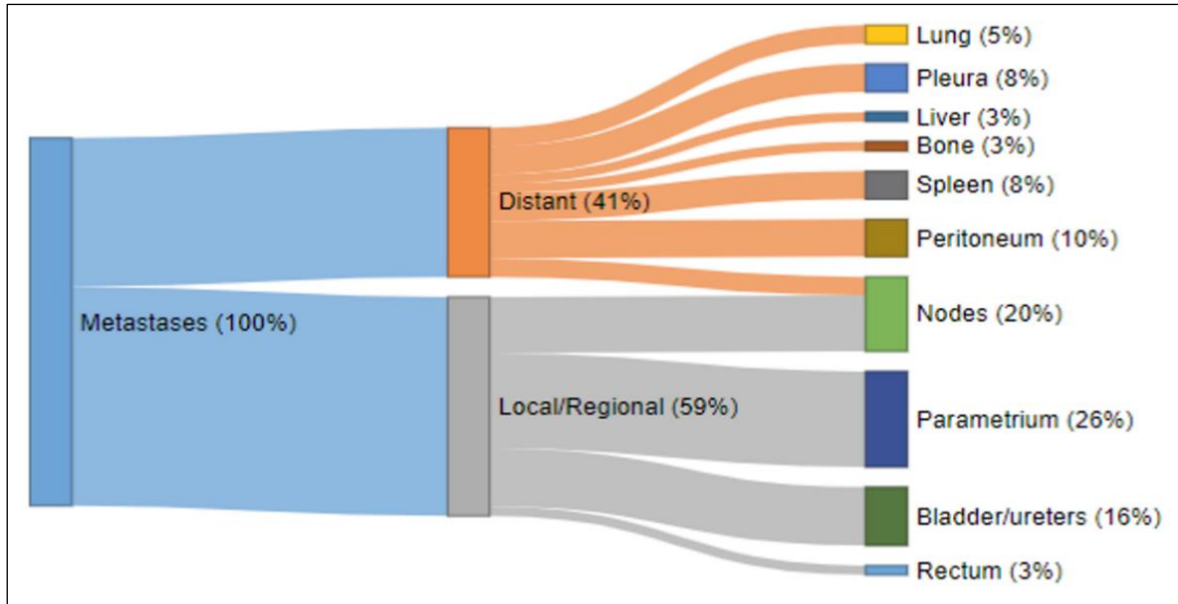


Figure 2: Sankey diagram illustrating the pattern of cervical cancer spread

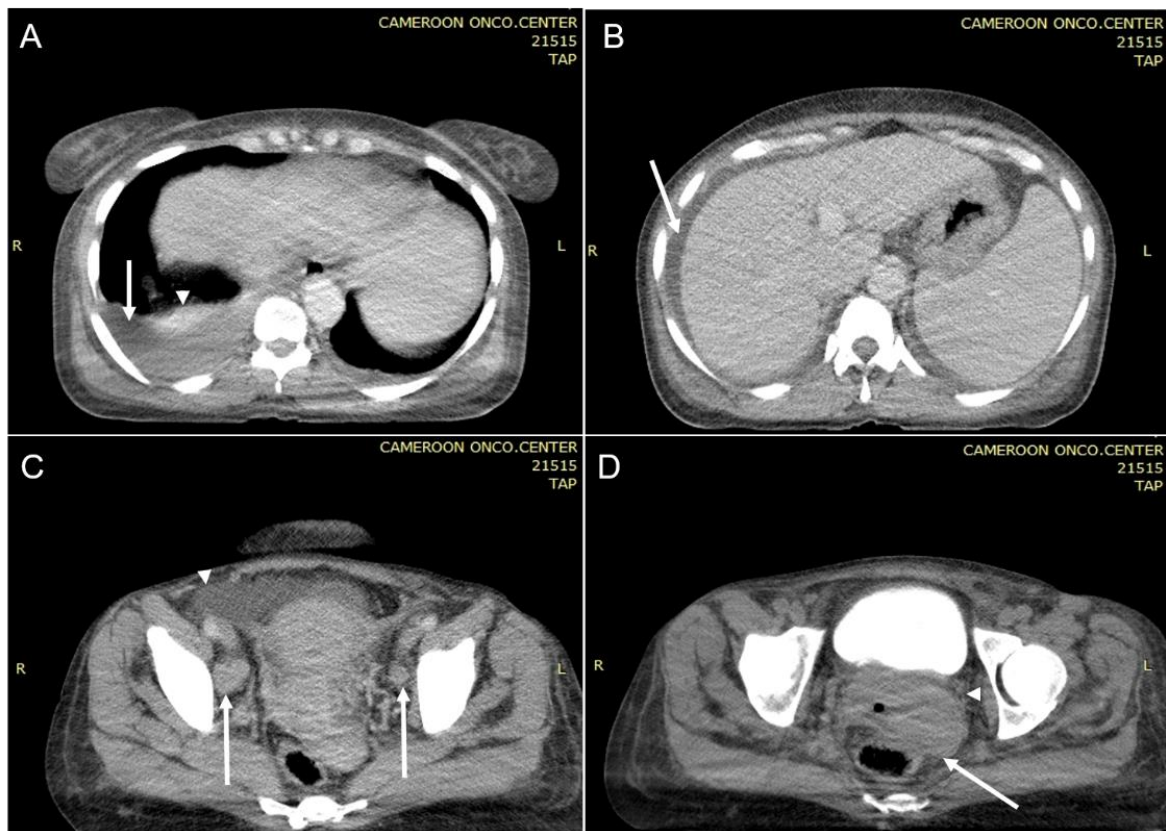
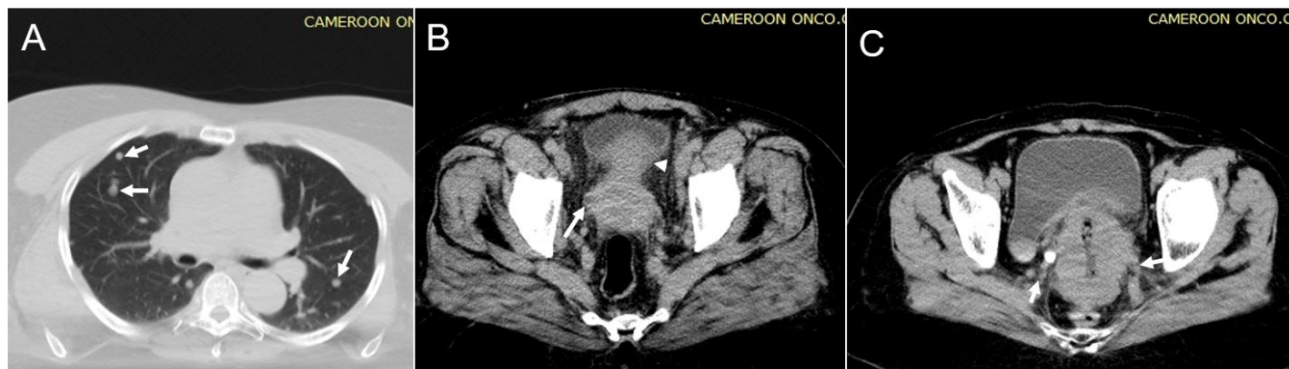
Figure 3: Staging contrast-enhanced axial CT of a 38-year-old patient with cervical cancer. A: Right pleural effusion (long arrow) with subpleural posterior-basal atelectasis (arrowhead). There is a thin layer of left pleural effusion. B: Ascites (arrow). C: Bilateral para-iliac bulky lymph nodes (long arrow) and ascites (arrowhead). D. Late phase showing a bulky uterine cervix with an eccentric left-sided mass (long arrow) and parametrial nodular thickening (invasion)



**Figure 4:** A: Axial CT scan of a 72-year-old woman with epidermoid carcinoma of the uterine cervix. Lung window shows disseminated lung nodules (arrows) of different sizes in a random distribution. B: Axial contrast-enhanced CT of a 62-year-old woman with epidermoid carcinoma showing a bulky uterine cervix with mixed attenuation and irregular margins. There is invasion of the bladder neck (arrowhead) and peri-ureteral fat (long arrows) with ureteral dilatation. C: Axial contrast-enhanced CT (late phase) of a 53-year-old woman with squamous cell carcinoma of the uterine cervix showing a bulky uterine cervix with irregular margins and nodular thickening of the parametrium (arrows)

## DISCUSSION

The findings of this study indicate a high burden of spread of cervical cancer at diagnosis and during follow up at the study setting. These suggest late diagnosis at advanced stage of disease and possibly a poor response to available treatment options. In a study carried out in Cameroon using MRI to assess patients with a clinical suspicion and those with histologically proven cervical cancer, there were no reported distant metastatic lesion [13].

In Cameroon, cervical cancer is the second most prevalent cancer in women with a reported 2,770 annual cases in 2022 and 1,787 deaths [10]. Globally, the overall survival at 5 years is approximately 92%, 65%, and 17% for early-stage, locally advanced and metastatic disease respectively [14]. Advanced age (> 65 years) has been reportedly associated with a late diagnosis and poor prognosis [15, 16]. This can be attributed to the absence of routine or national screening programs for women of this age group.

Medical imaging plays a primordial role in diagnosis, staging and in the follow up of treatment. However, these imaging modalities are not always present in local settings. Ultrasonography (US) has limited use in the management of cervical cancer. The transvaginal US technique has been suggested as an alternative to MRI in primary diagnostic work up of cervical cancer [8]. MRI, with an excellent soft tissue resolution is the ideal study to assess tumor size, depth of stromal invasion, parametrial and pelvic sidewall spread [9]. For advanced disease with therapeutic and prognostic consequences, CT or PET-CT are recommended for nodal and extra-pelvic spread [9, 17]. However, MRI is less available than CT whilst PET technology is inexistent in the national health system in Cameroon. Consequently, CT is often overly used in general [18], but rightly so in the hands of experts when it comes to cancer imaging, and is the main imaging modality to monitor the treatment of most cancers [12].

Given the lower soft tissue resolution compared to MRI, CT is poor in the assessment of local cervical cancer, as about 50% will appear isodense to the adjacent stroma [6]. It is also difficult to detect small tumors with CT. CT can thus underestimate vaginal, parametrial and pelvic sidewall invasion [19]. Some authors nevertheless reported the sensitivity for parametrial invasion in early stage disease to be as high as 94%, similar to MRI [7]. In another study, the sensitivity of CT scan in detecting bladder involvement was 100% compared to cystoscopy at 9.4% [20]. However, it is unclear what gold standard was used in this study.

Nodal disease was reportedly frequent, essentially pelvic and extra-pelvic. Lymph node assessment with CT relies on the size, heterogeneity and the presence of necrosis. In the CT-TAP reports, all lymph nodes with short axis greater than 10mm were reported. For this study, the RECIST 1.1 criteria which considers a short-axis diameter of at least 15mm as a measureable target lesion was used. It is therefore likely that smaller pathological nodes were not considered as nodal tumor disease.

The most common sites for distant metastases were the peritoneum with ascites and the pleurae with effusion. Zhou *et al.*, reported the lung as being the most common site for metastases, with patients with a single-site metastasis having a better prognosis than those with multi-site metastases [21]. This information, as applicable in the local setting, can help in imaging surveillance and treatment planning.

Despite the seemingly high burden of cervical cancer in most SSA countries the management is gradually improving. This is due to improved diagnostic and management capabilities [22]. At Cameroon Oncology Center there is a blend of local and international consultancy that collaborate in the management of every patient. This helps confront local realities with state-of-the-art recommendations and guidelines that guarantee improved and safe patient care.

This model can be reproduced in similar settings. Nevertheless, we opine that emphasis should be placed on primordial, primary and secondary prevention strategies if SSA countries aspire to curb the rising incidence and mortality due to cervical cancers.

This study was not without limitations. Firstly, the small sample size could hinder the drawing of meaningful conclusions that could apply to the wider population. Secondly, relying on CT reports exclusively for tumor spread could have underestimated local invasion, nodal and osseous tumor disease. The use of RECIST 1.1 criteria could also have further minimized nodal tumor spread reporting. The findings of this study therefore would reflect the minimum or a best case scenario of metastatic disease with very low possibility of false positive findings.

**Conflicts of interest:** The authors declare no competing interest.

**Funding:** None

**Acknowledgment:** The authors are grateful for the language editing and proofreading services of Mrs. Arabella Tambe BA, Med.

## REFERENCES

- World Health Organisation. Cervical cancer. [https://www.who.int/health-topics/cervical-cancer#tab=tab\\_1](https://www.who.int/health-topics/cervical-cancer#tab=tab_1). Accessed 25 March 2024.
- Pimple, S., & Mishra, G. (2022). Cancer cervix: Epidemiology and disease burden. *Cytojournal*, *19*, 21.
- Dzinamarira, T., Moyo, E., Dzobo, M., Mbunge, E., & Murewanhema, G. (2023). Cervical cancer in sub-Saharan Africa: an urgent call for improving accessibility and use of preventive services. *International Journal of Gynecologic Cancer*, *33*(4), 592-597.
- Yang, M., Du, J., Lu, H., Xiang, F., Mei, H., & Xiao, H. (2022). Global trends and age-specific incidence and mortality of cervical cancer from 1990 to 2019: an international comparative study based on the Global Burden of Disease. *BMJ open*, *12*(7), e055470.
- Jedy-Agba, E., Joko, W. Y., Liu, B., Buziba, N. G., Borok, M., Korir, A., ... & Parkin, D. M. (2020). Trends in cervical cancer incidence in sub-Saharan Africa. *British journal of cancer*, *123*(1), 148-154.
- Mansoori, B., Khatri, G., Rivera-Colón, G., Albuquerque, K., Lea, J., & Pinho, D. F. (2020). Multimodality imaging of uterine cervical malignancies. *American Journal of Roentgenology*, *215*(2), 292-304.
- Hricak, H., Gatsonis, C., Coakley, F. V., Snyder, B., Reinhold, C., Schwartz, L. H., ... & Mitchell, D. G. (2007). Early invasive cervical cancer: CT and MR imaging in preoperative evaluation—ACRIN/GOG comparative study of diagnostic performance and interobserver variability. *Radiology*, *245*(2), 491-498.
- Fischerova, D., Frühauf, F., Burgetova, A., Haldorsen, I. S., Gatti, E., & Cibula, D. (2024). The Role of Imaging in Cervical Cancer Staging: ESGO/ESTRO/ESP Guidelines (Update 2023). *Cancers*, *16*(4), 775.
- Haldorsen, I. S., Lura, N., Blaakær, J., Fischerova, D., & Werner, H. M. (2019). What is the role of imaging at primary diagnostic work-up in uterine cervical cancer?. *Current oncology reports*, *21*(9), 1-15.
- ICO/IARC Information Center on HPV and Cancer. Cameroon: Human Papillomavirus Infection and Related Cancers, Fact Sheet 2023. [https://hpvcentre.net/statistics/reports/CMR\\_FS.pdf](https://hpvcentre.net/statistics/reports/CMR_FS.pdf) %0A. Accessed 25 March 2024.
- Do, R. K., Lupton, K., Causa Andrieu, P. I., Luthra, A., Taya, M., Batch, K., ... & Hricak, H. (2021). Patterns of metastatic disease in patients with cancer derived from natural language processing of structured CT radiology reports over a 10-year period. *Radiology*, *301*(1), 115-122.
- Eisenhauer, E. A., Therasse, P., Bogaerts, J., Schwartz, L. H., Sargent, D., Ford, R., ... & Verweij, J. (2009). New response evaluation criteria in solid tumours: revised RECIST guideline (version 1.1). *European journal of cancer*, *45*(2), 228-247.
- Onana, Y., Mohamadou, A., Amvene, J. M., Ngaroua, D., Secvou, G. E., Guena, M. N., ... & Amvene, S. N. O. (2021). Contribution of MRI in Extension Assessment of Cervical Cancer in Yaoundé (Cameroon). *Open Journal of Radiology*, *11*(4), 151-159.
- Gennigens, C., Jerusalem, G., Lapaille, L., De Cuypere, M., Streef, S., Kridelka, F., & Ray-Coquard, I. (2022). Recurrent or primary metastatic cervical cancer: current and future treatments. *ESMO open*, *7*(5), 100579.
- Cooley, J. J., Maguire, F. B., Morris, C. R., Parikh-Patel, A., Abrahão, R., Chen, H. A., & Keegan, T. H. (2023). Cervical cancer stage at diagnosis and survival among women  $\geq$  65 years in California. *Cancer Epidemiology, Biomarkers & Prevention*, *32*(1), 91-97.
- Šavrova, A., Jaal, J., Nõmm, O., & Innos, K. (2023). Factors associated with advanced-stage diagnosis of cervical cancer in Estonia: a population-based study. *Public Health*, *225*, 369-375.
- Akin, O., Mironov, S., Pandit-Taskar, N., & Hann, L. E. (2007). Imaging of uterine cancer. *Radiologic Clinics*, *45*(1), 167-182.
- Tambe, J., Mbuagbaw, L., Nguefack-Tsague, G., Foyet, J., & Ongolo-Zogo, P. (2020). Multidetector computed tomography utilization in an urban sub-Saharan Africa setting: user characteristics, indications and appropriateness. *Pan African Medical Journal*, *37*(1). doi:10.11604/pamj.2020.37.42.21176.

19. Prasad, T. V., Thulkar, S., Hari, S., Sharma, D. N., & Kumar, S. (2014). Role of computed tomography (CT) scan in staging of cervical carcinoma. *Indian Journal of Medical Research*, 139(5), 714-719.
20. Agrawal, R., & Agarwal, R. (2024). Utility of CT Scan in Detecting Bladder Involvement Among Patients With Cervical Carcinoma. *Cureus*, 16(2). doi:10.7759/cureus.53670.
21. Zhou, S., & Peng, F. (2020). Patterns of metastases in cervical cancer: a population-based study. *International journal of clinical and experimental pathology*, 13(7), 1615-1623.
22. Burt, L. M., McCormak, M., Lecuru, F., Kanyike, D. M., Bvochora-Nsingo, M., Ndlovu, N., ... & Gaffney, D. K. (2021). Cervix cancer in sub-Saharan Africa: an assessment of cervical cancer management. *JCO Global Oncology*, 5(1), 173-182.

---

**Cite This Article:** Joshua Tambe, Yannick Onana, Jean Roger Mouliom Tapouh, Wilfried Mosse, Vanessa Tongue, Paul Mobit, Emilienne Guegang, Odile Zeh, Boniface Moifo (2024). Metastatic Disease Patterns of Uterine Cervical Cancer on Computed Tomography at an Oncology Hospital in Cameroon: A Pilot Study. *EAS J Radiol Imaging Technol*, 6(6), 127-133.

---