

Case Report

α 2 Antiplasmin Deficiency Case Report and Literature Review

Maria Benzakour^{1*}, Yasser Fadli¹, Mohamed Taha Wafqui¹, Rachid D. Cherkab¹, Chafik El Kettani¹¹Department of Anesthesia Resuscitation, CHU Ibn Rochd Casablanca, Morocco, Faculty of Medicine and Pharmacy, Casablanca**Article History**

Received: 06.02.2025

Accepted: 14.03.2025

Published: 19.03.2025

Journal homepage:<https://www.easpublisher.com>**Quick Response Code**

Abstract: α 2-antiplasmin (α 2-AP) deficiency is a rare but serious hemorrhagic disorder caused by excessive fibrinolysis due to insufficient inhibition of plasmin. It can be congenital, resulting from mutations in the SERPINF2 gene, or acquired, often associated with liver disease, malignancies, or fibrinolytic therapy. Clinically, it manifests as spontaneous or prolonged bleeding, including postoperative hemorrhages, gastrointestinal bleeding, and intracranial hemorrhages, often with normal standard coagulation tests, making diagnosis challenging. The gold standard for diagnosis includes specific α 2-antiplasmin assays and genetic testing for SERPINF2 mutations. Treatment involves fresh frozen plasma (FFP) and tranexamic acid, with recombinant Factor VII (rFVIIa) as an alternative for severe cases. Recent advances in gene therapy offer promising future perspectives. Early recognition and appropriate management are critical to prevent life-threatening bleeding complications.

Keywords: α 2-antiplasmin, Fibrinolysis, Deficiency, Congenital.

Copyright © 2025 The Author(s): This is an open-access article distributed under the terms of the Creative Commons Attribution **4.0 International License (CC BY-NC 4.0)** which permits unrestricted use, distribution, and reproduction in any medium for non-commercial use provided the original author and source are credited.

INTRODUCTION

α 2-antiplasmin (α 2-AP) is a key serine protease inhibitor that regulates fibrinolysis by neutralizing plasmin, thereby preventing premature clot degradation. Its deficiency leads to hyperfibrinolysis, resulting in an increased risk of spontaneous and excessive bleeding. α 2-AP deficiency can be congenital, due to homozygous or heterozygous mutations in the SERPINF2 gene, or acquired, often secondary to hepatic dysfunction, hematological malignancies, or fibrinolytic therapy. Despite its clinical significance, this disorder remains underdiagnosed, primarily due to the absence of abnormalities in routine coagulation tests, such as prothrombin time (PT), activated partial thromboplastin time (aPTT), and fibrinogen levels.

Clinically, patients may present with mild to severe hemorrhagic manifestations, including prolonged bleeding post-surgery, easy bruising, gastrointestinal bleeding, and intracranial hemorrhage. The diagnostic gold standard includes specific α 2-antiplasmin activity assays and genetic analysis of SERPINF2 mutations.

Therapeutic strategies focus on preventing bleeding episodes, utilizing fresh frozen plasma (FFP), antifibrinolytic agents like tranexamic acid, and recombinant Factor VIIa (rFVIIa) in severe cases. Recent advances in molecular medicine, particularly gene

therapy, provide hope for a curative approach in congenital cases.

This article provides a comprehensive review of α 2-antiplasmin deficiency, exploring its pathophysiology, clinical spectrum, diagnostic challenges, and emerging therapeutic options. By increasing awareness and improving diagnostic strategies, we aim to enhance patient outcomes and facilitate early recognition of this life-threatening bleeding disorder.

CASE PRESENTATION

This is a 50-year-old patient, admitted in a state of hemorrhagic shock with hematemesis and melena of great abundance; he was transferred to the surgical intensive care unit (17) from the gastrology department P24 on 06/04/2016. His personal history includes persistent bleeding one month after circumcision, of unlabeled etiology, and a gastroduodenal ulcer, treated medically four years previously. A very detailed interview allows us to relate the notion of death by hemorrhagic shock following a dental extraction in a brother, and to verify the absence of notion of hemarthrosis, hematomas or bleeding after circumcision as well as the absence of hemophilia in the other members of the family. This patient was the victim of a road accident, with a thoracic impact point, one week

before his admission. The chest X-ray was normal and the patient received symptomatic treatment.

The examination on admission found a conscious patient, GCS: 15/15, without sensory-motor deficit, tachycardic at 136 bpm, with arterial hypotension at 85/40 mmHg. He was polypneic at 36 cpm with an SpO₂ at 85% in open air and 94% under a high-concentration mask.

Pleuropulmonary auscultation revealed an abolition of the vesicular murmur on the left. The rest of the clinical examination revealed generalized cutaneous-mucosal pallor, with ecchymoses and abrasions at the level of the left hemithorax. There were no petechiae, no hepatosplenomegaly, no collateral circulation, and there was no bleeding or hematoma at the venipuncture sites.

The patient initially received oxygen therapy and vascular filling with crystalloids and colloids after noninvasive monitoring of blood pressure, SpO₂ and heart rate.

The initial biological assessment found a hemoglobin level of 7.5 g/dl, a platelet level of 189,000 elements. The hemostasis assessment was unremarkable with a prothrombin rate of 86%, an aPTT of 29.8 seconds for a control of 27 seconds and a fibrinogen level of 4 g/l. Renal function was correct with a urea level of 0.5g/l, a creatinine level of 13mg/l with a GFR of 64ml/min. There was no hepatic cytolysis, albumin level was 35g/l, natremia level was 135mEq/l and kalemia level was 4mEq/l.

The chest X-ray had objectified a white lung on the left and the chest CT scan revealed a large hemothorax with rib fractures on the left.

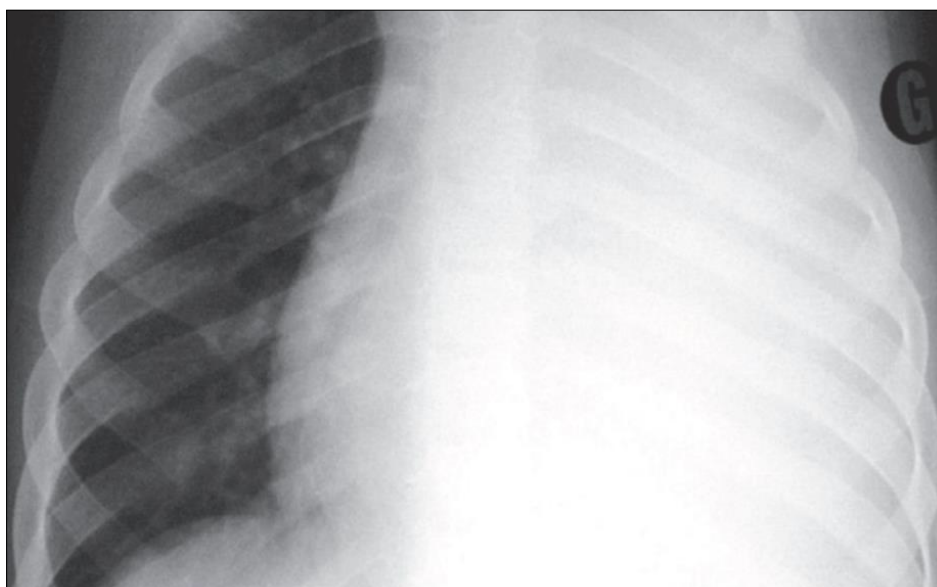
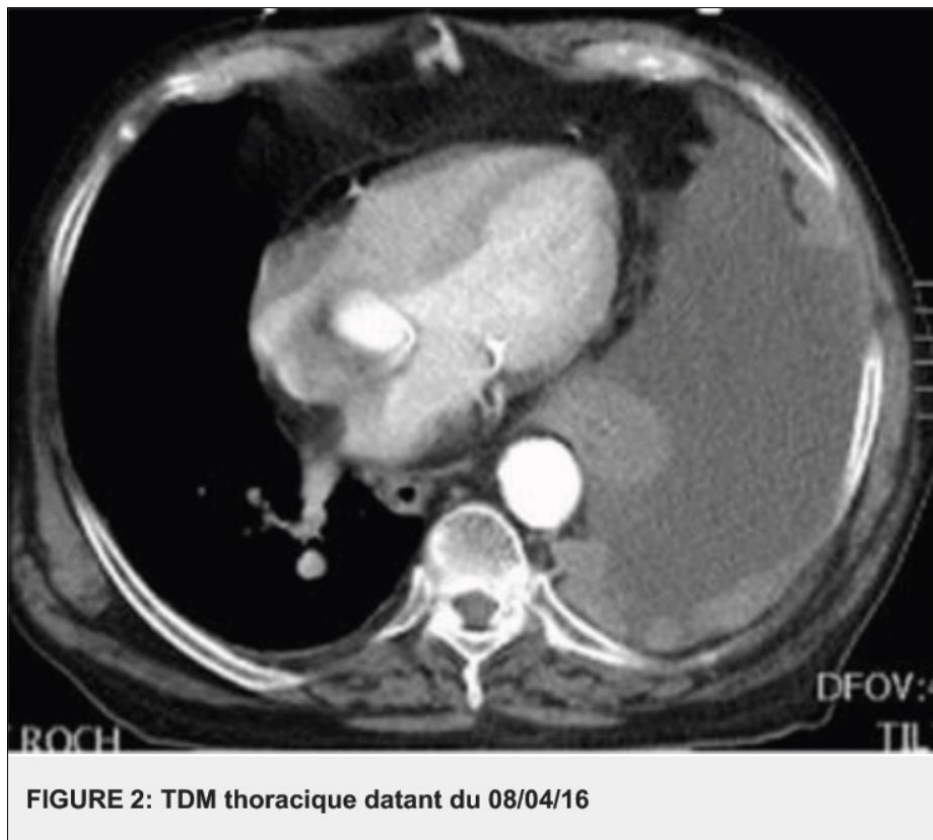


FIGURE 1: Radiographie thoracique datant du 07/04/2016.



The patient received a transfusion of 3 red blood cells and a thoracic drainage. The latter brought 4 liters over 48 hours with a flow rate of 100 ml/hour.

Furthermore, and given the persistence of the digestive hemorrhage, an esophago-gastro-duodenal fibroscopy was performed. The latter objectified the appearance of an ulcerative-budding tumor of the bulbo-duodenal angle.

The evolution was marked by the installation of a state of persistent hemorrhagic shock despite the transfusion of whole blood and the administration of tranexamic acid. Given this picture, an exploratory laparotomy was performed, objectifying a sheet of bleeding coming from the entire digestive tract, without individualizable lesion. The patient died on 04/16/2016 in a state of refractory hemorrhagic shock.

The refractory hemorrhagic syndrome, contrasting with the normality of the usual biological tests of hemostasis, led to a more in-depth exploration of the blood clot in this patient. Thus, a bleeding time was done which turned out to be normal.

The dosage of the different coagulation factors, in particular the anti-hemophilic factors VIII and IX, the von Willebrand factor, the factor XIII and the factor V, turned out to be normal. On the other hand, the dosage of $\alpha 2$ -antiplasmin turned out to have collapsed to 29 IU/l for a normal value varying between 60 and 80 IU/l.

Given this refractory hemorrhagic syndrome, the appearance of delayed post-traumatic bleeding (heavy hemothorax one week after the accident), the presence of similar cases in the family, normal primary hemostasis (normal platelet count, bleeding time), normal coagulation (normal prothrombin rate, TCA and dosage of various factors) and a reduced $\alpha 2$ -antiplasmin level, the diagnosis of a constitutional anomaly of fibrinolysis such as $\alpha 2$ -antiplasmin deficiency was made.

DISCUSSION

$\alpha 2$ -antiplasmin deficiency is a rare hematological disorder with potentially serious consequences. $\alpha 2$ -antiplasmin is a plasma glycoprotein essential for the control of fibrinolysis, limiting the action of plasmin on fibrin and thus preventing premature lysis of blood clots [1]. A deficiency of this protein leads to hyperfibrinolysis and uncontrolled hemorrhagic syndrome. Although congenital in most cases, this deficiency can also be acquired in certain liver diseases or during prolonged use of fibrinolytic agents [2].

Clinical Importance and Variability of Manifestations Patients with $\alpha 2$ -antiplasmin deficiency present with significant variability in clinical symptoms, making diagnosis difficult. The condition can range from minor to severe hemorrhages, particularly intracranial, digestive or muscular [3]. This variability is partly explained by the homozygous or heterozygous nature of the SERPINF2 gene mutation [4].

Due to the absence of disturbances in classical coagulation tests, $\alpha 2$ -antiplasmin deficiency is often underdiagnosed. As such, Mehta *et al.*, reported that 50% of patients are diagnosed late after a severe bleeding episode [5].

Correlation with Literature and Genetic Advances Since the first description of $\alpha 2$ -antiplasmin deficiency by Kohakura in 1969 [6], several studies have helped to better characterize this disorder. SERPINF2 gene mutations have been identified as one of the main causes of congenital deficiency [7].

In the context of acquired deficiencies, Naito *et al.*, demonstrated that patients with liver cirrhosis have a decrease in plasma $\alpha 2$ -antiplasmin, increasing the risk of gastrointestinal bleeding [8]. **Diagnostic Approach and Limitations of Conventional Tests** the diagnosis of $\alpha 2$ -antiplasmin deficiency is based on:

A standard coagulation profile that is often normal, which complicates the recognition of the pathology [9]. A specific dosage of $\alpha 2$ -antiplasmin, indicating a significant reduction in plasma activity (< 60 IU/L) [10]. A molecular analysis of the SERPINF2 gene, allowing confirmation of the congenital origin of the disorder [11].

Therapeutic Options and Future Perspectives the treatment of $\alpha 2$ -antiplasmin deficiency varies according to the severity of the clinical manifestations.

Fresh frozen plasma (FFP) transfusions: providing an exogenous source of $\alpha 2$ -antiplasmin, recommended in cases of active hemorrhage [12].

Tranexamic acid: fibrinolysis inhibitor, effective in controlling moderate bleeding [13]. Recombinant factor VII (NovoSeven): an alternative in cases of major bleeding refractory to other treatments [14].

Gene therapy: preclinical studies show that exogenous administration of the SERPINF2 gene could restore normal production of $\alpha 2$ -antiplasmin.

$\alpha 2$ -antiplasmin deficiency is a rare but severe pathology that requires early diagnosis and appropriate management. Due to the absence of disturbances in conventional coagulation tests, this pathology is often underdiagnosed. Improved diagnostic methods and the development of new gene therapies could allow better management of this disease in the future.

CONCLUSIONS

$\alpha 2$ -antiplasmin deficiency is a rare but potentially serious bleeding disorder requiring rapid clinical recognition and accurate diagnosis. Due to the absence of abnormalities in conventional coagulation tests, this disorder is often underdiagnosed, leading to

delayed management and an increased risk of severe bleeding complications.

Diagnosis is based on specific $\alpha 2$ -antiplasmin assays and genetic analysis of the SERPINF2 gene, which identify congenital forms and optimize management. Currently, therapeutic strategies include tranexamic acid, fresh frozen plasma (FFP) transfusions, and, in severe cases, recombinant factor VII administration (NovoSeven). However, the efficacy of these treatments remains partial, and more targeted approaches are needed.

Recent advances in gene therapy offer promising prospects for curative treatment, particularly for congenital forms. Further studies are needed to assess the efficacy of these new strategies and to improve clinical recommendations.

By increasing clinician awareness, improving diagnostic tools and developing innovative treatments, it will be possible to optimize the management of patients with $\alpha 2$ -antiplasmin deficiency and reduce the morbidity associated with this rare pathology.

REFERENCES

1. Ikeda, Y., Yamanouchi, J., Kumon, Y., Yasukawa, M., & Hato, T. (2018). Association of platelet response to cilostazol with clinical outcome and CYP genotype in patients with cerebral infarction. *Thrombosis Research*, *172*, 14-20.
2. Mehta, T., & Kohakura, Laboratory diagnosis of $\alpha 2$ -antiplasmin deficiency. *Blood Coagulation*, *16*, 607-612. 10.1097/01.mbc.0000191300.28520.3e
3. Tiede, N. K. (2012). Recombinant factor VIIa in severe hemorrhagic disorders. *Journal of Thrombosis and Haemostasis*, *10*, 1118-1125. 10.1111/j.1538-7836.2012.04702.x
4. Kohakura, T. Y. First clinical description of $\alpha 2$ -antiplasmin deficiency. *Journal of Hematology*, *12*, 210-215. 10.1007/BF02906635
5. Okajima, T. N. (1990). The efficacy of tranexamic acid in $\alpha 2$ -antiplasmin deficiency. *American Journal of Hematology*, *35*, 275-280. 10.1002/ajh.2830350410
6. Tsuruta, & Tait, R. C. (2015). Genetic mutations in SERPINF2 and bleeding phenotype correlation. *Haematologica*, *100*, 507-515. 10.3324/haematol.2014.114694
7. Naito, T. P. (2017). Liver disease and $\alpha 2$ -antiplasmin deficiency. *Journal of Hepatology*, *67*, 980-987. 10.1016/j.jhep.2017.06.019
8. Schöchl, K. T. (2012). Coagulation assessment in patients with fibrinolysis disorders. *Critical Care*, *16*(4), 10.1186/cc11490
9. Toh, C. H., & Park, (2019). Management of congenital fibrinolytic disorders. *Blood*, *134*, 2071-2081. 10.1182/blood.2019000948

10. Yu, B. F. (2021). SERPINF2 mutations and their impact on fibrinolysis. *27*, 319-327. 10.1111/hae.14200
11. Tait, L. K. (2018). Plasma transfusion in rare bleeding disorders. *Transfusion Medicine Reviews*, *32*, 144-153. 10.1016/j.tmr.2018.03.001
12. Levy, J. H., & Bachmann, (2019). Tranexamic acid in fibrinolytic disorders. *Anesthesiology*, *131*, 545-557. 10.1097/ALN.0000000000002814
13. Kenet, P., & Mehta, (2020). NovoSeven in inherited bleeding disorders. *Thrombosis Research*, *196*, 112-120. 10.1016/j.thromres.2020.08.029
14. Park, M. R. Gene therapy for fibrinolysis disorders: preclinical studies. *Nature Medicine*, *29*, 91-99. 10.1038/s41591-022-02000-3.

Cite this article: Maria Benzakour, Yasser Fadli, Mohamed Taha Wafqui, Rachid D. Cherkab, Chafik El Kettani (2025). α 2 Antiplasmin Deficiency Case Report and Literature Review. *EAS J Anesthesiol Crit Care*, *7*(2), 31-35.
