

## Case Series

## Patellar Tendon Rupture: Surgical Repair and Protection Using Semitendinosus–Gracilis Graft (DIDT) – Report of Two Cases

Charif M.<sup>1</sup>, Antar A.<sup>1\*</sup>, El Amraoui I.<sup>1</sup>, Laraichi A.<sup>1</sup>, Aguenauoe O.<sup>1</sup>, Fekhaoui M.R.<sup>1</sup>, Mekkaoui M.J.<sup>1</sup>, Bouffetal M.<sup>1</sup>, Bassir R.A.<sup>1</sup>, Kharmaze M.<sup>1</sup>, Lamrani M.O.<sup>1</sup>

<sup>1</sup>Department of Orthopedic and Traumatology, University Hospital Center (CHU) Rabat, Morocco

**Article History**

**Received:** 11.06.2025

**Accepted:** 15.08.2025

**Published:** 18.08.2025

**Journal homepage:**

<https://www.easpublisher.com>

**Quick Response Code**

**Abstract: Objective:** To describe the diagnostic and therapeutic aspects of patellar tendon rupture and to report two cases treated by primary suture protected with a semitendinosus–gracilis (DIDT) autograft frame. **Methods:** Two patients with traumatic patellar tendon rupture underwent surgery using the same technique: primary repair and protective autologous DIDT frame. A literature review was performed to define the role of this technique. **Results:** Both patients regained full active extension and satisfactory knee mobility at 6 months, without major complications. Literature data report a success rate above 90% with this method. **Conclusion:** Patellar tendon repair protected by a DIDT frame is a reliable technique, allowing early mobilization and reducing the risk of rerupture.

**Keywords:** Patellar Tendon Rupture, Suture, DIDT, Knee Surgery, Orthopedic Surgery.

**Copyright © 2025 The Author(s):** This is an open-access article distributed under the terms of the Creative Commons Attribution **4.0 International License (CC BY-NC 4.0)** which permits unrestricted use, distribution, and reproduction in any medium for non-commercial use provided the original author and source are credited.

## INTRODUCTION

The patellar tendon, a central element of the extensor mechanism, connects the lower pole of the patella to the tibial tuberosity [1]. Rupture, though rare, occurs mainly in young active adults, often due to high-energy trauma or sudden eccentric contraction of the quadriceps [2].

Loss of full active knee extension results in severe functional disability. Surgical treatment aims to restore tendon continuity and knee biomechanics [3]. Using an autologous semitendinosus–gracilis graft (DIDT) to protect the repair offers high mechanical resistance, enabling early rehabilitation and limiting the risk of repair failure [4].

## MATERIALS AND METHODS

### Case Reports

**Case 1:** A 32-year-old male with no medical history sustained a fall during a football match, landing on a flexed knee.

**Clinical Findings:** acute pain, functional impotence, loss of active knee extension, radiographic evidence of patella alta.

**Diagnosis:** confirmed by ultrasound showing complete rupture of the patellar tendon.

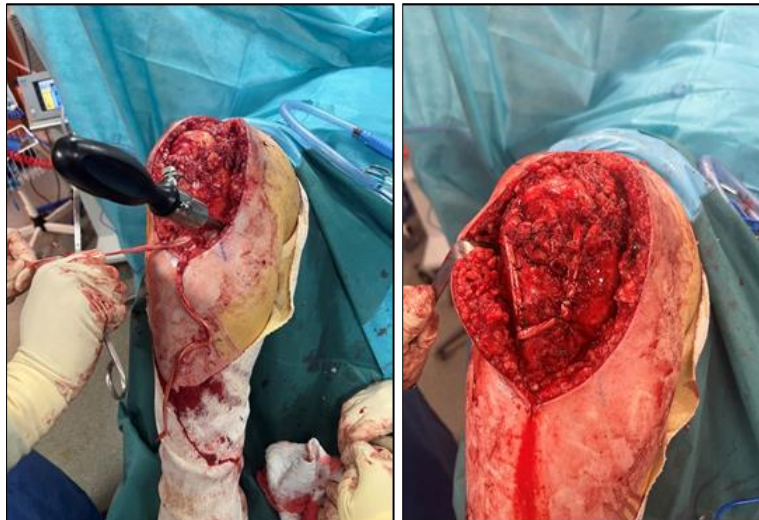
### Surgical Technique:

- Anterior midline incision centered on the patella.
- Debridement and primary suture with transosseous Krackow stitches.
- Harvest of semitendinosus–gracilis tendons from the medial knee.
- Protective graft looped around the patella and fixed to the tibial tuberosity with an interference screw.
- Postoperative immobilization in full extension for 4 weeks.

**Case 2:** A 41-year-old male sustained a direct blow to a flexed knee in a work accident.

**Clinical and Imaging Findings:** similar to Case 1.

**Surgical Technique:** identical to Case 1, with graft fixation to the tibia using staples.



**Figure: "Patellar Tendon Repair and Protection Using Semitendinosus–Gracilis (DIDT) Graft Frame**

## LITERATURE REVIEW

Data were extracted from articles indexed in PubMed and Google Scholar published between 2000 and 2025, including series using DIDT in protection or reconstruction. Selection criteria included clinical relevance, postoperative follow-up, and functional evaluation.

## RESULTS

### Case Outcomes

At 6 months follow-up:

- **Case 1:** range of motion 0–135°, full active extension, quadriceps strength 5/5, IKDC 92/100.
- **Case 2:** range of motion 0–130°, full active extension, strength 5/5, IKDC 90/100. No evidence of tendon elongation or laxity.

### Literature Data:

- Shelbourne *et al.*, [5], reported 93% good functional results at 2 years.
- Miskovsky *et al.*, [6], found greater initial strength with DIDT compared to metallic cables.
- Rupture risk is under 5% with proper protection [7].
- Early mobilization is possible from the 2nd postoperative week in several protocols [8].

## DISCUSSION

Primary repair is the gold standard for acute patellar tendon ruptures [3]. However, the initial weakness of the suture may lead to loosening, justifying the use of protective augmentation [9].

The DIDT offers several advantages:

- Autologous tissue with good biological tolerance.

- Sufficient mechanical strength to protect repair during healing [6].
- Allows earlier rehabilitation compared to simple transosseous sutures.

Limitations include donor-site morbidity (medial knee pain) and longer operative time [10]. Our two cases confirm the effectiveness of this method, with full recovery and no major complications.

## CONCLUSION

Patellar tendon repair protected by a DIDT autologous graft is a reliable technique, providing strong initial fixation, reducing rerupture risk, and enabling early functional recovery. It should be considered, particularly in active or athletic patients.

## REFERENCES

1. Siwek CW, Rao JP. Ruptures of the extensor mechanism of the knee joint. *J Bone Joint Surg Am*. 1981;63(6):932-937.
2. Clayton RA, Court-Brown CM. The epidemiology of musculoskeletal tendinous and ligamentous injuries. *Injury*. 2008;39(12):1338-1344.
3. Enad JG. Patellar tendon ruptures. *South Med J*. 1999;92(6):563-566.
4. Milankov M, *et al.*, Reconstruction of chronic patellar tendon ruptures with autogenous semitendinosus and gracilis tendons. *Acta Chir Belg*. 2003;103(3):333-337.
5. Shelbourne KD, Urch SE. Primary repair of patellar tendon rupture without augmentation. *Am J Sports Med*. 2008;36(2):316-323.
6. Miskovsky S, *et al.*, Reconstruction of patellar tendon ruptures using semitendinosus and gracilis tendon autograft. *Arthroscopy*. 2004;20(8):944-953.
7. Kasten P, *et al.*, Surgical repair of patellar tendon rupture: clinical results and return to sports. *Arch Orthop Trauma Surg*. 2001;121(7):356-361.

8. Zernicke RF, Garhammer J, Jobe FW. Human patellar-tendon rupture. *J Bone Joint Surg Am*. 1977;59(2):179-183.
9. Cadambi A, Engh GA. Use of a semitendinosus tendon autogenous graft for chronic patellar tendon rupture. *J Bone Joint Surg Am*. 1992;74(7):974-979.
10. Temponi EF, *et al.*, Reconstruction of chronic patellar tendon ruptures with semitendinosus autograft. *Arthrosc Tech*. 2015;4(2):e153-e156.

---

**Citation:** Charif M., Antar A., El Amraoui I., Laraichi A., Aguenaoe O., Fekhaoui M.R., Mekkaoui M.J., Bouffetal M., Bassir R.A., Kharmaze M., Lamrani M.O. (2025). Patellar Tendon Rupture: Surgical Repair and Protection Using Semitendinosus–Gracilis Graft (DIDT) – Report of Two Cases. *EAS J Orthop Physiother*, 7(4): 97-99.

---