EAS Journal of Dentistry and Oral Medicine
Abbreviated Key Title: EAS J Dent Oral Med
ISSN: 2663-1849 (Print) & ISSN: 2663-7324 (Online)
Published By East African Scholars Publisher, Kenya

OPEN ACCESS

Volume-8 | Issue-6 | Nov-Dec-2026 | DOI: https://doi.org/10.36349/easjdom.2026.v08i06.003

Case Report

Sealing Socket Abutment in Molar Immediate Implant Placement: A Case Report

Mahjoubi Bouthaina[1]*, Grira Ibtissem[2], Jlassi Sabrine[3], Jebali Ranym[3], Belkacem Raouaa[4], Omezzine Moncef[5], Douki Nabiha[6,7]

[1]Assistant Professor in Prosthodontics, Department of Dental Medicine, Moknine Hospital, Monastir, Tunisia
[2]Assistant Professor in Prosthodontics, Department of Dental Medicine, Sahloul Hospital, Sousse, Tunisia
[3]Resident in Prosthodontics
[4]Professor in Oral Medicine and Oral Surgery
[5]Professor in Prosthodontics
[6]Professor in Conservative Dentistry and Endodontics
[7]Head of Dental Department, Sahloul Hospital, Sousse, Tunisia

Article History
Received: 17.09.2026
Accepted: 09.11.2026
Published: 26.11.2026

Journal homepage:
https://www.easpublisher.com

Quick Response Code

Abstract: ***Introduction*:** Immediate molar implant placement is attractive but challenged by socket sealing, soft-tissue collapse, and the impossibility of immediate restoration in many posterior sites. Customized healing abutments have been proposed to seal the socket and preserve the original soft-tissue contour. ***Case Presentation*:** Two non-restorable mandibular molars (46, 47) were extracted atraumatically with maximal preservation of bony support, implants were placed with axis verification, and SSA abutments were modelled to the gingival contour of the socket with universal adhesive, flowable resin increments, and photopolymerization., seated with alveolar grafting, and followed by definitive full-zirconia crowns. ***Discussion*:** Randomized trials report significantly higher modified Pink esthetic score (PES) and patient satisfaction with PEEK SSAs versus titanium healing abutments at 6 months and 1 year, and less buccal volume loss at 1 and 4 months with customized abutments. However, a 2025 meta-analysis found no significant difference in buccal or total volume variation at 4 months or marginal bone loss at 6 and 12 months, and an earlier systematic review found marginal bone level statistically similar despite better papilla maintenance and probing depth. Titanium offers greater fibroblastic proliferation and bacterial sealing, whereas composite resin carries monomer cytotoxicity. ***Conclusion*:** The SSA is a non-invasive, predictable option that reduces treatment time, surgical episodes, discomfort, and cost, but its dimensional benefit over standard abutments is not consistently demonstrated and larger controlled trials are needed.

Keywords: Immediate Implant Placement, Sealing Socket Abutment, Customized Healing Abutment, Emergence Profile, Soft Tissue Preservation.

Copyright © 2026 The Author(s): This is an open-access article distributed under the terms of the Creative Commons Attribution **4.0 International License (CC BY-NC 4.0)** which permits unrestricted use, distribution, and reproduction in any medium for non-commercial use provided the original author and source are credited.

INTRODUCTION

Immediate implant placement (IIP) is increasingly proposed as a time-efficient, cost-effective, and patient-centred alternative to delayed protocols, yet post-extraction alveolar remodelling can compromise long-term success through insufficient primary stability or parafunctional loading [1, 2]. Tooth extraction is followed by loss of the periodontal ligament and bundle bone, and the resulting volumetric changes affect both hard and soft tissues [3, 4].

When immediate loading is not indicated, the challenge is to close the socket without a flap while preserving the emergence profile established by the natural tooth [3, 2].

The sealing socket abutment (SSA) addresses this: a provisional, screw-retained device placed at surgery that seals the socket, supports the peri-implant soft tissue, and preserves the emergence profile, eliminating the need for a second surgery [1]. It acts as a mechanical barrier between the socket and the oral cavity, guides emergence-profile healing, and prevents

***Corresponding Author:** Dr Mahjoubi Bouthaina
Assistant Professor in Prosthodontics, Department of Dental Medicine, Moknine Hospital, Monastir, Tunisia

the mucosal closure that disorganizes soft-tissue architecture and underlying bone remodelling in the first two weeks [3]. It also protects and contains bone-graft material without sutures and avoids the micromotion and cement leakage of immediate restoration [5-7]. Customization is achieved chairside with flowable composite or digitally by CAD/CAM, and digital workflows have made the process more precise and reproducible [5-10].

This case report describes an immediate molar implant sealed with a CAD/CAM custom healing abutment (SSA) and discusses the technique against the current evidence base.

CASE PRESENTATION

A patient presented with a non-restorable mandibular first molar (46) and a fractured second molar (47) (figure.1); Both were extracted atraumatically with maximal preservation of bony support (figure.2), Drilling and axis verification were performed using a position indicator before implant insertion then implants were placed (figure 3,4).

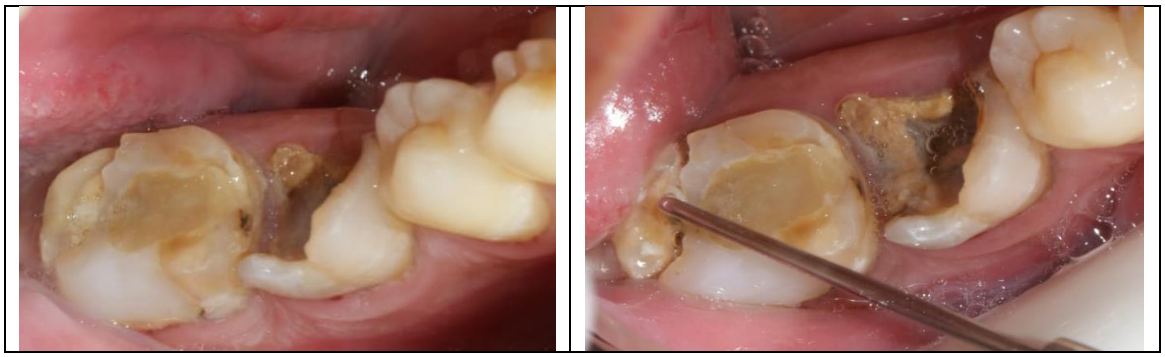

Fig. 1: Initial state: The patient presented with a severely compromised mandibular right first molar (tooth 46**) and a fractured mandibular right second molar (**tooth 47**). Both teeth were non-restorable**

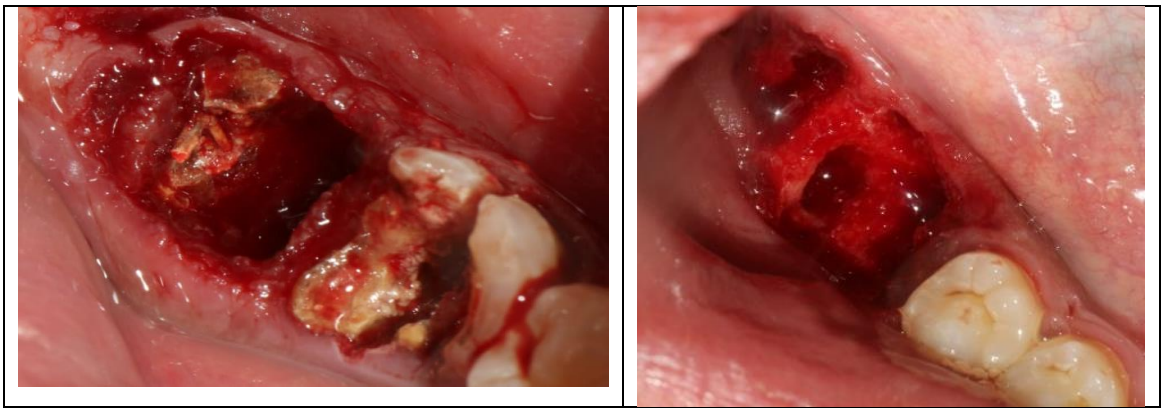

Fig. 2: Teeth 46 and 47 were extracted atraumatically, with particular attention to preserving the surrounding alveolar bone

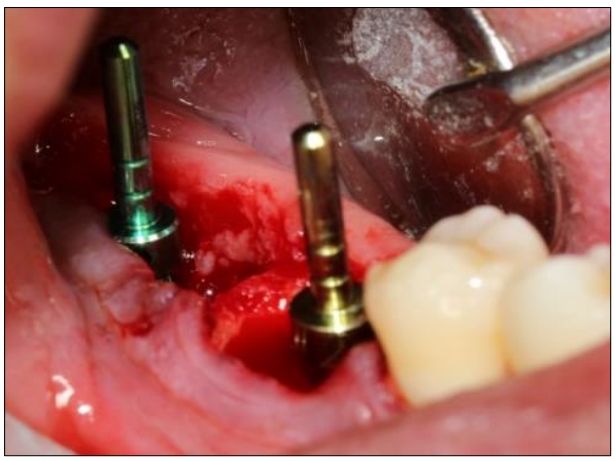

Fig. 3: The implant osteotomies were prepared, and implant axes were verified using a direction indicator

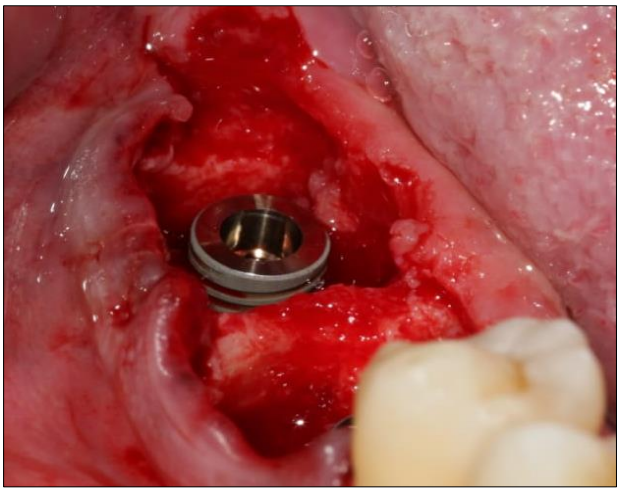

Fig. 4: Implant placement

The SSA abutments were modelled to follow the gingival contour of the extraction socket: a layer of universal adhesive is applied and a bead of flowable resin deposited, followed by successive resin increments and photopolymerization to build the emergence profile (figure 5), and the abutments were seated (figure 6). The rationale for a provisional device connected to the implant is to preserve the emergence profile established by the natural tooth and to ensure closure and seal between the extraction socket and the intraoral environment.

The emergence profile is then visible after removal of the SSA abutments (figure.7).

Definitive implant abutments are placed, and two definitive full-zirconia crowns are cemented on the conditioned tissue, achieving esthetic, periodontal, and occlusal integration (Figure. 8).

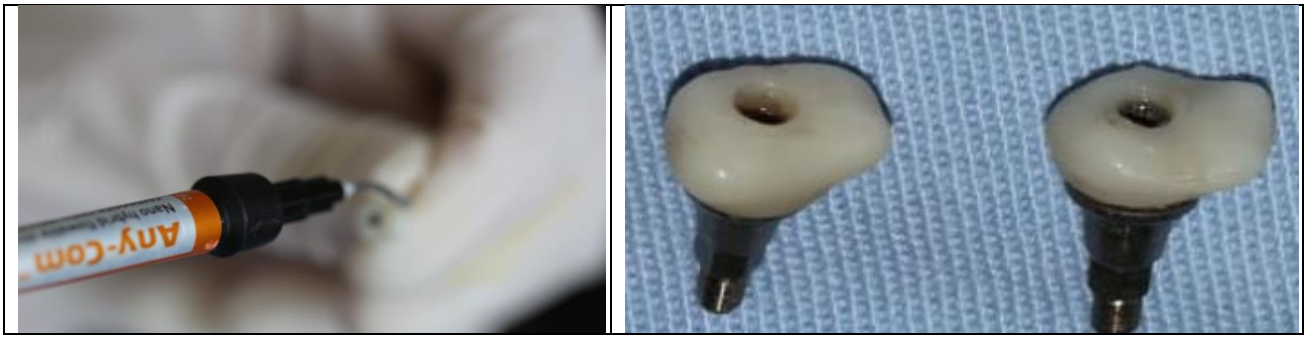

Fig. 5: SSA abutments were anatomically shaped following the gingival contours of the dental alveolus to support peri-implant soft tissue healing; Composite resin was applied in successive layers, with light curing performed after each increment



Fig. 6: Placement of two SSA abutments at the 46 and 47 sites

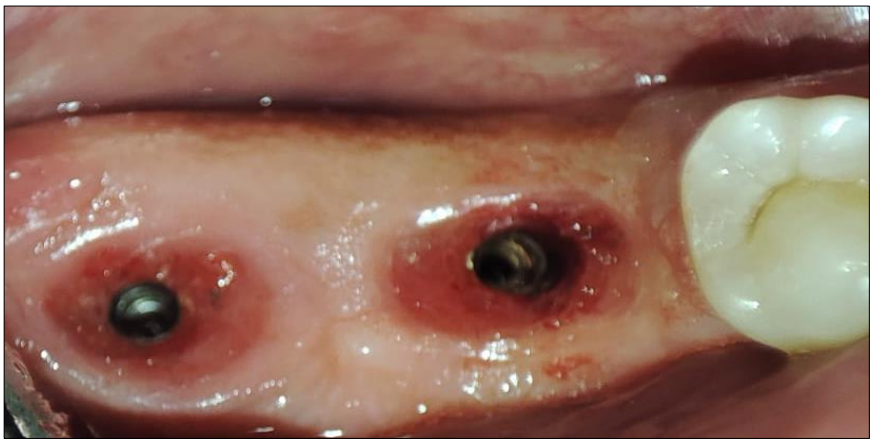

Fig. 7: Emergence profile after removal of the SSA abutments

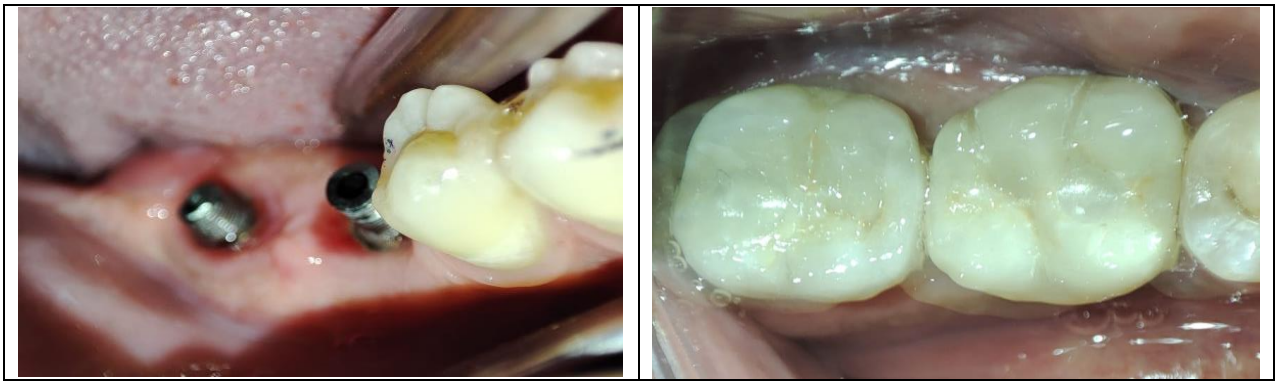

Fig. 8: Placement of the definitive implant abutments and definitive cementation of two monolithic zirconia crowns



Fig. 9: Esthetic, periodontal, and occlusal integration of two implant-supported crowns

DISCUSSION

The evidence supports the SSA as a predictable but not consistently superior option: it improves early soft-tissue contour and esthetic, while dimensional hard-tissue gains over standard abutments remain unproven. The attached technical report frames the SSA as a non-invasive means of achieving primary socket closure to optimize the transmucosal biological response, and the broader literature both supports and qualifies that claim.

The SSA functions as a mechanical barrier between the socket and the oral cavity, a guide for emergence-profile healing, and a means of preventing the mucosal closure that otherwise disorganizes soft-tissue architecture and underlying bone remodeling in the first two weeks. This rationale is echoed in the literature: the SSA seals the socket, supports peri-implant soft tissue, and preserves the emergence profile, eliminating the need for a second surgery [1-11].

The SSA was developed according to the esthetic biological contour (EBC) principle, aiming to reproduce the natural emergence profile of the extracted tooth. Its design incorporates a 4-mm-high flat-to-concave-to-convex contour, corresponding to the soft tissue thickness within the transition zone, thereby providing effective socket sealing (figure.10) [8].

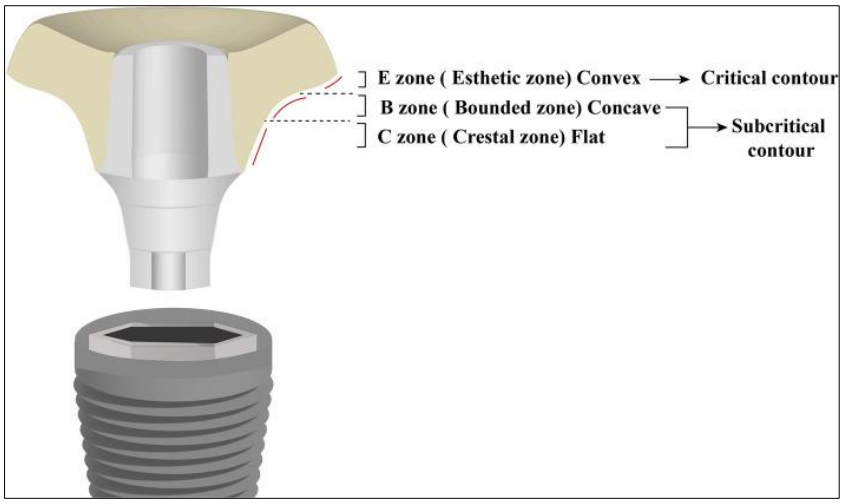

Fig. 10: Design of socket sealing abutment based on EBC concept [8]

Evidence on Tissue Outcomes

A randomized trial in posterior immediate implants found significantly higher modified Pink esthetic scores (PES) and patient satisfaction with PEEK SSAs versus titanium healing abutments at baseline, 6 months, and 1 year [8]. A second RCT comparing chairside composite versus prefabricated zirconia SSAs found comparable supra-platform tissue stability, with zirconia yielding shallower probing depths and composite less volumetric shrinkage [12]. In a prospective molar series combining SSA with peri-implant socket filling, survival was 95%, bone change 0.19 mm, and mid-buccal recession 0.07 mm at one year [13]. A two-year molar series reported minimal hard and soft tissue change with CAD/CAM SSAs [14].

Customized abutments reduced early volumetric loss compared with collagen matrices at one month, though differences disappeared by one year and thin bone phenotypes drove variation [7]. A systematic review concluded customized abutments are effective for sealing immediate sockets, particularly with thin bone phenotypes [15]. Customized titanium abutments-maintained peri-implant mucosa with only 0.63 mm buccal margin reduction over six months [4]. A 2025 meta-analysis of six studies found no significant differences in buccal or total volume variation at 4 months, midfacial height at 12 months, or marginal bone loss at 6 and 12 months [16]. An earlier systematic review reached a similar split: papilla maintenance and probing depth favored customized abutments, but mean marginal bone level was statistically similar [17]. A five-year pilot did report sustained soft-tissue stabilization [9], and a molar series with SSA plus socket grafting showed 95% survival, 0.19 mm bone change, and 0.07 mm mid-buccal recession at one year [1].

Material and Fabrication Trade-offs

Material choice remains unresolved. Titanium surfaces provide greater fibroblastic proliferation, bacterial sealing, and soft-tissue integration, whereas composite resin releases monomers with cytotoxic effects on proliferation and viability that can interrupt wound healing [4]. Chairside composite customization shortens the visit count but lengthens intraoperative time and risks socket contamination from excess resin [2-5]. Digital workflow intraoperative optical scanning, contralateral mirroring, and 3D printing of biocompatible resin make customization more precise and reproducible [10-18]. A recent classification distinguishes standard, anatomical, and customized abutments, with directly fabricated customized types enhancing soft-tissue stability and minimizing recession [19]. Digital workflows now allow preoperative design based on the natural emergence profile, including low-cost 3D-printed and mirrored designs [10-21].

Case Selection and Evidence Limits

The SSA is best indicated where immediate restoration is not feasible: insufficient primary stability, posterior sites with a large occlusal table, or sockets that cannot be sealed without a flap [1-5]. It avoids micromotion and cement leakage while retaining graft material [3-7]. Clinicians should weigh abutment material, implant depth and 3D position, mucosal height, and patient compliance beyond contour alone [8]. The evidence base is dominated by case series and a few small RCTs, and reviewers consistently call for larger trials with longer follow-up [3-23].

CONCLUSION

The SSA protocol reduces treatment time, surgical episodes, postoperative discomfort, and cost, and is best reserved for cases selected for adequate primary stability and favorable anatomy. Immediate restoration is often inadvisable in posterior single sites because of micromotion and occlusal load, which the SSA avoids by providing a non-loaded seal.

Limitations include the case-report design, small samples, and heterogeneity in materials and protocols; the evidence base remains dominated by case series and a small number of RCTs, and controlled

studies with standardized measurement and longer follow-up are still required. Clinicians should weigh abutment material, implant depth and 3D position, mucosal height, and patient compliance beyond the abutment contour alone.

REFERENCES

1. Akhondi, S et al, (2025). The Effect of the Sealing Socket Abutment (SSA) on Hard and Soft Tissue Healing Following Molar Post-Extraction Immediate Implant Placement. *Forum Implantologicum*. https://doi.org/10.63580/iti.fi.45768
2. Mohammad, M et al, (2025). Custom vs Stock Healing Abutments on Peri-Implant Tissue Integrity in Immediate Implant: A Randomized Controlled Study. *Journal of Pharmacy & Bioallied Sciences, 17*, S3719 - S3721. https://doi.org/10.4103/jpbs.jpbs_431_25
3. Yotsova, R. et al, (2022). Immediate implant placement using customized healing abutments as a method of hard and soft tissue preservation. A review article. *Scripta Scientifica Medicinae Dentalis*. https://doi.org/10.14748/ssmd.v8i2.8518
4. Lertwongpaisan, T et al (2023). Soft tissue dimensional change using customized titanium healing abutment in immediate implant placement in posterior teeth. *BMC Oral Health, 23*. https://doi.org/10.1186/s12903-023-03060-5
5. Chokaree, P et al (2024). Effect of Customized and Prefabricated Healing Abutments on Peri-Implant Soft Tissue and Bone in Immediate Implant Sites: A Randomized Controlled Trial. *Journal of Clinical Medicine, 13*. https://doi.org/10.3390/jcm13030886
6. Ruales-Carrera, E. et al (2019). Peri-implant tissue management after immediate implant placement using a customized healing abutment.. *Journal of esthetic and restorative dentistry : official publication of the American Academy of Esthetic Dentistry ... [et al.]*. https://doi.org/10.1111/jerd.12512
7. Fernandes, D et al (2021). Effect of customized healing abutments on the peri-implant linear and volumetric tissue changes at maxillary immediate implant sites: A 1-year prospective randomized clinical trial.. *Clinical implant dentistry and related research*. https://doi.org/10.1111/cid.13044
8. Elgendi, M et al (2025). Peri-implant soft tissue conditioning of immediate posterior implants by CAD-CAM socket sealing abutments: a randomized clinical trial. *BMC Oral Health, 25*. https://doi.org/10.1186/s12903-024-05417-w
9. De Francesco, M. et al, (2024). Soft-Tissue Management Dental Implants with Digitally Customized Healing Abutments: A Pilot Study. *Prosthesis*. https://doi.org/10.3390/prosthesis6030042
10. Guo, Z. et al, (2026). Reconstruction of emergence profile using a digital mirroring technique in a custom biological definitive abutment and interim restoration in immediate implant placement in esthetic area: A clinical report with 4-year follow-up.. *The Journal of prosthetic dentistry*. https://doi.org/10.1016/j.prosdent.2026.04.002
11. Song, Y. et al, (2024). Peri-implant soft tissue management with commercial healing abutment and customized sealing socket abutment after immediate implantation on upper molars: A case report of profilometric analysis. *The Journal of The Korean Dental Association*. https://doi.org/10.22974/jkda.2024.62.9.003
12. Gnusins, V et al, (2025). Chairside vs Prefabricated Sealing Socket Abutments for Posterior Immediate Implants: A Randomized Clinical Trial.. *Clinical implant dentistry and related research, 27 4*, e70076. https://doi.org/10.1111/cid.70076
13. Lilet, R et al, (2021). Immediate implant placement combining socket seal abutment and peri-implant socket filling. A prospective case series.. *Clinical oral implants research*. https://doi.org/10.1111/clr.13852
14. Finelle, G et al, (2021). Sealing Socket Abutments (SSAs) in Molar Immediate Implants with a Digitalized CAD/CAM Protocol: Soft Tissue Contour Changes and Radiographic Outcomes After 2 Years.. *The International journal of periodontics & restorative dentistry, 41 2*, 235-244. https://doi.org/10.11607/prd.4579
15. Mosharraf, R et al, (2025). Customized versus titanium healing abutments for preimplant tissue healing in fresh socket implants: A systematic review. *Dental Research Journal, 22*. https://doi.org/10.4103/drj.drj_479_23
16. Tamim, H. et al, (2025). Clinical outcome of custom healing abutments in immediate implant placement: A systematic review and meta-analysis.. *The Journal of prosthetic dentistry*. https://doi.org/10.1016/j.prosdent.2025.09.038
17. Lenz, U. et al,(2023). Peri-implant Outcomes from Customized Healing Abutments Using Immediate Implants: A Systematic Review.. *The International journal of oral & maxillofacial implants, 38 5*, 985-995. https://doi.org/10.11607/jomi.10311
18. Georgiou, C. et al, (2025). A simple technique to create emergence profile in immediate posterior implant placement using guided surgery and 3D printed customized healing abutment. *Digital Dentistry Journal*. https://doi.org/10.1016/j.ddj.2025.100052
19. Manfredini, M et al. (2026). Healing Abutment Classification in Implant Dentistry and Effect on Hard and Soft Tissues: A Systematic Review.. *The International journal of prosthodontics, 0 0*, 1-39. https://doi.org/10.11607/ijp.9443
20. Ramadan, R. et al, (2025). Fully digital workflow for a CAD-CAM custom healing abutment with an optimal emergence profile: A dental technique.. *The Journal of prosthetic dentistry*. https://doi.org/10.1016/j.prosdent.2024.09.033

21. Pozza, M. et al,(2022). Digital workflow for low-cost 3D-printed custom healing abutment based on emergence profile CBCT segmentation.. *The Journal of prosthetic dentistry*. https://doi.org/10.1016/j.prosdent.2022.10.019
22. Bharathi, M.et al, (2026). Customized Healing Abutments for Peri-Implant Soft Tissue Stability: Biological Rationale and Clinical Outcomes: A Narrative Review. *International Journal of Dental Materials*. https://doi.org/10.37983/ijdm.2026.8303
23. Ruhstorfer, M. et al,(2024). Systematic review of peri-implant conditions and aesthetic outcomes of customized versus conventional healing abutments. *International Journal of Implant Dentistry, 10*. https://doi.org/10.1186/s40729-024-00581-8

Cite This Article: Mahjoubi, B., Grira, I., Jlassi, S., Jebali, R., Belkacem, R., Omezzine, M., & Douki, N. (2026). Sealing Socket Abutment in Molar Immediate Implant Placement: A Case Report. *EAS J Dent Oral Med, 8*(6), 218-224. https://doi.org/10.36349/easjdom.2026.v08i06.003