EAS Journal of Dentistry and Oral Medicine
Abbreviated Key Title: EAS J Dent Oral Med
ISSN: 2663-1849 (Print) & ISSN: 2663-7324 (Online)
Published By East African Scholars Publisher, Kenya

OPEN ACCESS

Volume-8 | Issue-6 | Nov-Dec-2026 | DOI: https://doi.org/10.36349/easjdom.2026.v08i06.004

Case Report

Fully Digital Fabrication of Intraradicular Axial Attachments for a Mandibular Root-Supported Overdenture Using Scan Posts: A Case Report

Dorra Zayani[1]*, Yosra Mabrouk[2], Ines Saadellaoui[2], Zied Fedaoui[3], Hiba Triki[4], Lamia Mansour[5]

[1]Resident Dentist, Removable Partial Denture Department, ABCDF Laboratory, Faculty of Dental Medicine, University of Monastir, Tunisia, Mail: Nabeul, 8050
[2]Associate Professor, Removable Partial Denture Department, ABCDF Laboratory, Faculty of Dental Medicine, University of Monastir, Tunisia, Mail: Monastir, 5000
[3]Assistant Professor, Departement of Fixed Prosthodontics, Research Laboratory of Occlusodontics and Ceramics, Faculty of Dental Medicine, University of Monastir, Tunisia, Mail: Monastir, 5000
[4]Professor, Removable Partial Denture Department, ABCDF Laboratory, Faculty of Dental Medicine, University of Monastir, Tunisia Mail: Monastir, 5000
[5]Professor, Removable Partial Denture Department, ABCDF Laboratory, Faculty of Dental Medicine, University of Monastir, Tunisia Mail: Monastir, 5000

Article History
Received: 28.09.2026
Accepted: 16.11.2026
Published: 28.11.2026

Journal homepage:
https://www.easpublisher.com

Quick Response Code

Abstract: Managing subtotal mandibular edentulism is challenging because of the limited denture-bearing surface, which may compromise prosthesis retention and stability. Preserving strategic residual roots and using them to support auxiliary retention systems can improve prosthetic outcomes. This case report describes a fully digital workflow for fabrication of ball attachments in a root-supported overdenture**.** A 40-year-old patient with subtotal mandibular edentulism and maxillary Kennedy Class I edentulism consulted for a prosthetic rehabilitation. The treatment plan consisted of a maxillary conventional removable partial denture and a mandibular root-supported overdenture retained by two intraradicular axial attachments. A fully digital workflow using Computer-Aided Design / Computer-Aided Manufacturing (CAD/CAM) technology was used to fabricate axial attachment copings. The mandibular canines were prepared and scanned with an intraoral scanner (IOS), both without and with scan posts to capture their supragingival morphology and intraradicular anatomy, respectively. The scan of both jaws and a digital bite registration were also obtained. The datasets were processed using CAD softwares to design the attachment components, which were manufactured as wax patterns and cast in cobalt-chromium alloy. The copings were clinically tried in to assess their fit and adaptation before cementation. Scan posts provided a stable geometric reference for intraoral acquisition of the prepared post spaces, facilitating the transfer of intraradicular anatomy and enhancing the accuracy and reproducibility of attachments fabrication. The integration of IOS, scan posts and CAD/CAM technology offers a predictable and efficient alternative for fabricating axial attachments, overcoming the limitations of conventional techniques like distortions and volumetric changes.

Keywords: Overdenture, Ball Attachment, Residual Roots, Intraoral Scanner, Digital Impression, Scan Post, CAD/CAM.

Copyright © 2026 The Author(s): This is an open-access article distributed under the terms of the Creative Commons Attribution **4.0 International License (CC BY-NC 4.0)** which permits unrestricted use, distribution, and reproduction in any medium for non-commercial use provided the original author and source are credited.

INTRODUCTION

Managing subtotal edentulism with a conventional removable prosthesis remains particularly challenging in the mandible because reduced denture-bearing surface area, advanced alveolar bone resorption, and the influence of the tongue and surrounding structures often compromise prosthesis retention and stability [1].

***Corresponding Author:** Dorra Zayani
Resident Dentist, Removable Partial Denture Department, ABCDF Laboratory, Faculty of Dental Medicine, University of Monastir, Tunisia, Mail: Nabeul, 8050

In this context, preserving strategic tooth roots to support intraradicular axial attachments or bar-retained overdentures improves retention while maintaining the alveolar ridge, limiting bone resorption, preserving proprioception, and enhancing masticatory function and patient comfort [2].

Intraradicular axial attachments can be fabricated using either conventional or digital workflows. Conventional techniques are technique-sensitive and labor-intensive, whereas digital workflows enable the fabrication of customized restorations with greater precision and a simplified clinical and laboratory workflow [3].

Nevertheless, further clinical evidence is required to determine which approach provides the greatest long-term stability and clinical success.

Initially, Computer-Aided Design / Computer-Aided Manufacturing (CAD/CAM) fabrication of intraarticular posts relied on scanning of conventional silicone impressions or plaster models [4]. Recent advances have enabled direct intraoral scan of post-space, supporting a fully digital workflow validated by in vitro studies.

However, the accurate acquisition of the intra-radicular space remains a major challenge in intraoral scanning. An indirect approach, involving the digitalization of an impression with the post positioned within the root canal, has demonstrated acceptable accuracy. In contrast, the use of dedicated scan posts has been associated with significantly improved clinical outcomes, providing more accurate digital capture of the post space and facilitating the subsequent design and fabrication of the definitive restoration.

This case report presents the rehabilitation of a subtotal mandibular edentulism with a tooth-supported overdenture retained by two axial attachments fabricated by a fully digital workflow using scan posts.

CASE REPORT

Clinical Examination

A 40-year-old female patient with no significant medical history presented to the Department of Removable Partial Prosthodontics at the Dental Clinic of Monastir for prosthetic rehabilitation to restore oral function.

Intraoral examination revealed the presence of teeth 11, 12, 13, 18, 21, 22, and 23 in the maxillary arch, all without clinical mobility. Tooth 23 was restored with a porcelain-fused-to-metal crown, while teeth 11 and 21 presented with composite restorations. Tooth 18 exhibited a peg-shaped morphology. The maxillary residual ridge was moderately high and wide, with firm, healthy mucosal coverage (Figure 1).

In the mandibular arch, a subtotal edentulism was observed, with both canines remaining. The residual ridge presented a moderately favorable osteomucosal conditions (Figure 2).

Radiographic examination revealed favorable radiographic crown-to-root ratios (less than 1) for maxillary teeth 11, 12, 13, 21, and 22, whereas tooth 23 exhibited a less favorable ratio greater than 1.

In the mandibular arch, both canines demonstrated satisfactory periodontal support, with radiographic crown-to-root ratios of 1 and no clinical mobility. (Figure 3)

Occlusal analysis suggested a potentially altered occlusal vertical dimension (OVD), although it appeared clinically preserved. An irregular occlusal plane and inadequate anterior guidance were also identified. Nevertheless, the available prosthetic space was considered sufficient for the planned restorations.

The treatment plan consisted of a conventional maxillary removable partial denture and a mandibular tooth-supported overdenture retained by two intraradicular axial attachments. A fully digital workflow was adopted for the design and fabrication of the attachments, using scan posts to transfer the intraradicular anatomy into the digital workflow.



Figure 1: Endobuccal view of the mandibular arch



Figure 2: Endobuccal view of the maxillary arch



Figure 3: Panoramic radiography: the two mandibular canines presented radiographic crown/radiographic root ratio =1

Considering the patient's limited financial resources, implant-supported rehabilitation was excluded. A more affordable treatment approach was therefore selected, consisting of a removable partial denture in the maxilla and a mandibular tooth-supported overdenture retained by two axial attachments.

The treatment involved the fabrication of two custom root copings incorporating ball-type male attachments on teeth 33 and 43. The corresponding female components were incorporated into the fitting surface of the mandibular overdenture.

Prior to treatment, a diagnostic tooth arrangement was performed on articulated study casts. The mandibular canines were virtually reduced on the casts to evaluate the available prosthetic space and confirm the feasibility of incorporating the attachment system.

Pre-Prosthetic Phase:

After hygiene motivation and extraction of tooth 18, a hermetic endodontic treatment was performed on both mandibular canines.

Prosthetic Phase:

The prosthetic construction began with the preparation of the crown and root of the canines. The crowns were first cut off 2 mm above the gingival margin.

Following crown reduction, the occlusal surface of each root was shaped into a flat platform following the contour of the gingival margin. The preparation consisted of a gently sloping buccal surface toward the gingival margin and a horizontal lingual platform. A juxtagingival circumferential chamfer finish line with slight axial wall convergence (Figure 4). The post space was prepared to approximately two-thirds of the root length while preserving a 3–5 mm apical seal of root canal filling material (Figure 5).

A fully digital workflow was implemented to assess the feasibility of intraoral scanning and computer-aided design and manufacturing (CAD/CAM) for the fabrication of custom intraradicular attachment copings. Scan posts were used to register the prepared post spaces.



Figure 4: Preparation of the cervical plate according to Richmond recommendations

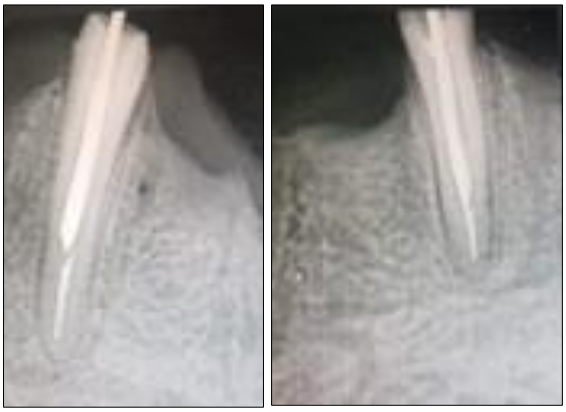

Figure 5: Preparation of the two third of the root

The mandibular canines were scanned using an intraoral scanner (TRIOS; 3Shape).

Each abutment was scanned twice. The initial scan was performed without a scan post to capture the supragingival tooth morphology. Afterward, a scan post was passively inserted into the prepared root canal to record the intraradicular anatomy. The scanner captured the scan post's upper surface, which incorporates identifiable geometric patterns that facilitate accurate alignment of the acquired datasets during the design process. (Figure 6,7)

Throughout scanning, moisture control was maintained using cotton rolls and high-volume suction to ensure optimal intraoral conditions for digital image acquisition. Full-arch scans of both jaws and digital bite registrations were also obtained (Figure 8,9,10).

The digital datasets were imported into CAD software (3shape Dental System for the post and Exocad for the coronal part of the attachment), where the male part of the attachments were designed.

The mandibular arch scan and the corresponding scan post datasets were imported in Standard Tessellation Language (STL) format. The prepared mandibular canines (teeth 33 and 43) were

identified, and their respective limits were defined to guide the subsequent design procedures (Figure 11).

Following segmentation, the software performs an automatic best-fit alignment between the scanned mandibular arch and the scan posts seated on the prepared natural abutment teeth (33 and 43) (Figure 12). The scanned scan posts, were matched against the appropriate virtual scan post from the library within the software database to ensure accurate three-dimensional positioning relative to the prepared roots and allow the software to automatically generate a deep morphology of the post space (Figure 13). The aligned segments were subsequently isolated and exported as independent digital objects for further processing (Figure 14).

For the coronal part of the attachment, the digital scan of the maxilla and mandibular arch with the prepared abutments and axial framework component and the digital bite registration were imported into the "Exocad" software (Figure 15). A virtual prosthetic project simulation was done to evaluate the available prosthetic space and determine the feasibility of incorporating axial attachments into the mandibular overdenture (Figure 16).

After manually refining the scanned surface around the prepared natural abutments, the abutment tooth zones were defined and margin lines were detected (Figure 17, 18). The coronal parts of the attachments were then designed. The male components were selected from the library:" Rhein83" and aligned parallel to one another to establish a common path of insertion (Figure 19, 20).

Finally, the completed attachment designs were exported in STL format and were manufactured using CAM technology as wax patterns and subsequently cast in cobalt-chromium alloy using the conventional lost-wax technique (Figure 22).

Following fabrication, the metal copings were clinically evaluated. Passive seating, retention, absence of rocking, and marginal adaptation to the remaining tooth structure were carefully assessed before proceeding with definitive cementation (Figure 23).



Figure 6: Passive insertion of scan post

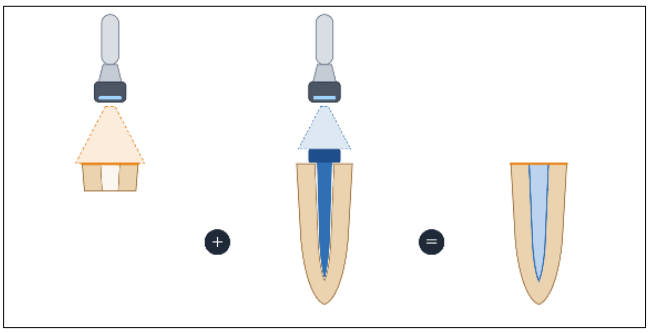

Figure 7: Schematic illustration of a scan post application: The intraoral scanner initially captures the prepared abutment and the coronal part of the post space, followed by scanning of the cylindrical head of the scan post



Figure 8: Occlusal view of scanned maxillary arch

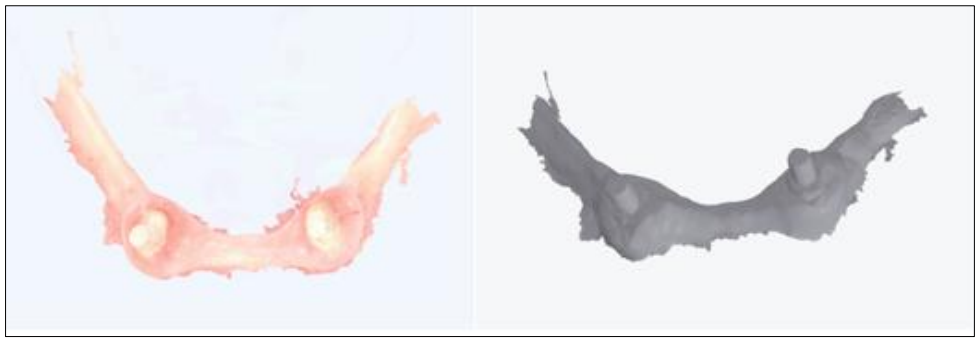

Figure 9: Occlusal view of scanned mandibular arch with scan posts inserted into the prepared teeth



Figure 10: Scanned bite registration using occlusal rims



Figure 11: Digital acquisition and segmentation of the mandibular arch with



Figure 12: Automatic alignment of the scanned arch following segmentation with the scan post copings seated on the prepared natural abutment teeth



Figure 13: Matching of the virtual library -based scan post with the scanned scan post



Figure 14: Extraction and isolation of the aligned axial framework component

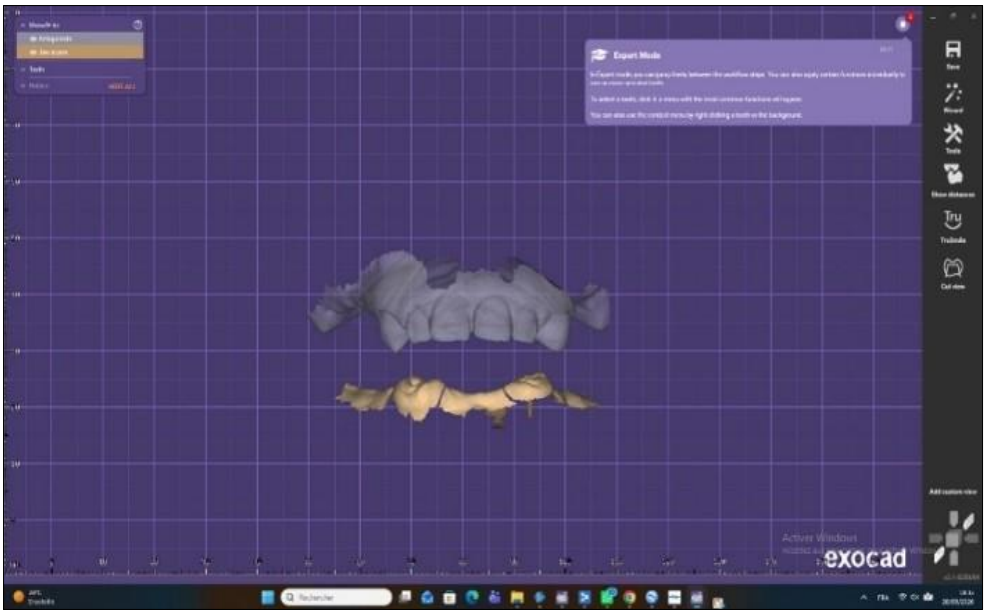

Figure 15: Raw digital scan of the maxillary and mandibular arch with the prepared abutments: teeth 33 and 43

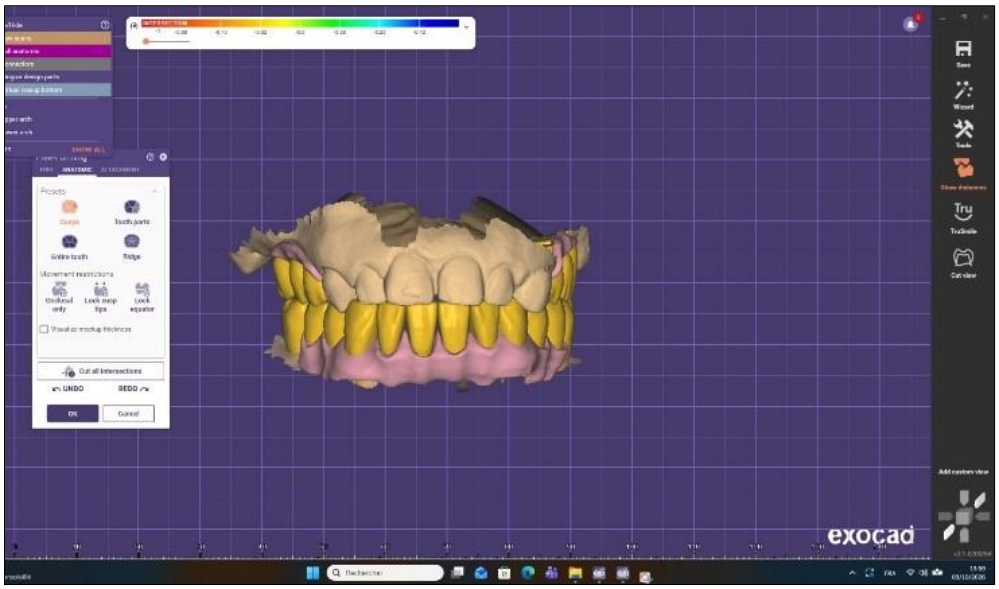

Figure 16: Prosthetic project simulation

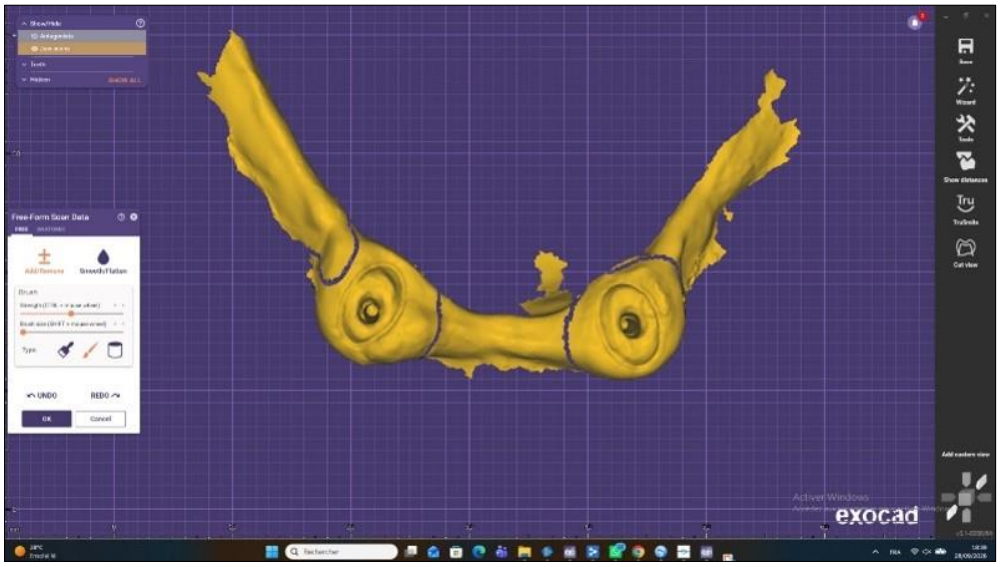

Figure 17: Manual refinement of the scanned surface around the prepared natural abutments

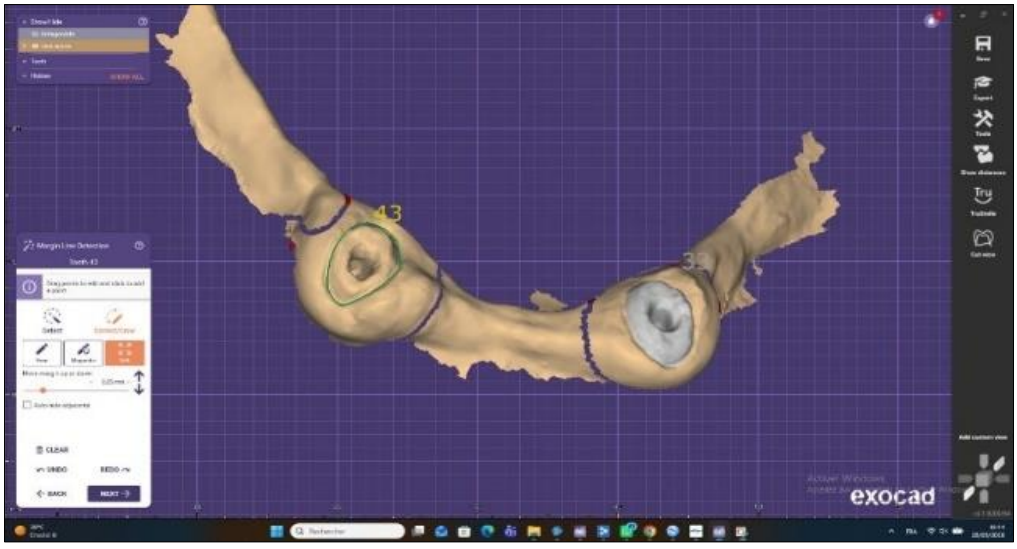

Figure 18: Definition of the abutment tooth zones and margin line detection



Figure 19: Positioning of the male component after choosing the attachment from the library:" Rhein83"



Figure 20: Parallelization of the axial attachments

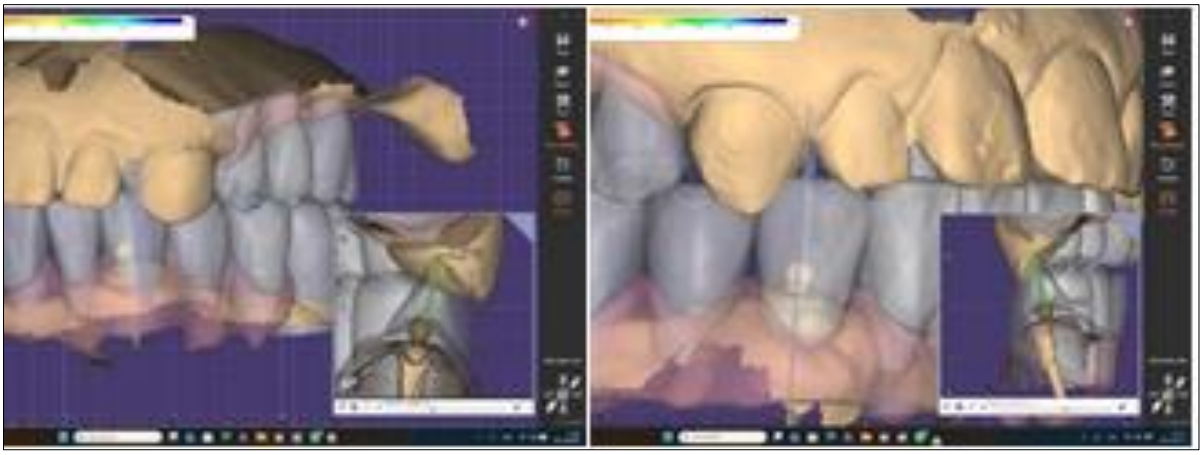

Figure 21: Verification of occlusal prosthetic space



Figure 22: The customized male part of the axial attachments



Figure 23: Try-in of the metal copings

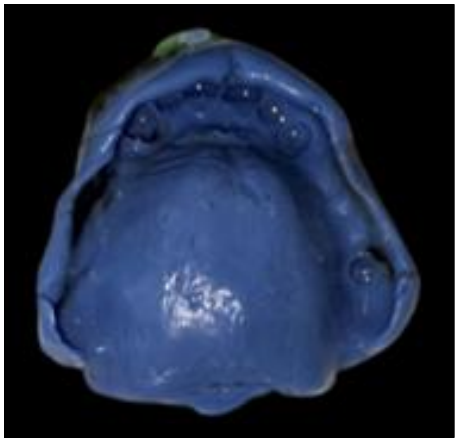

Figure 24: Anatomo-functional impression of the maxillary arch



Figure 25: Situational impression of the mandibular arch

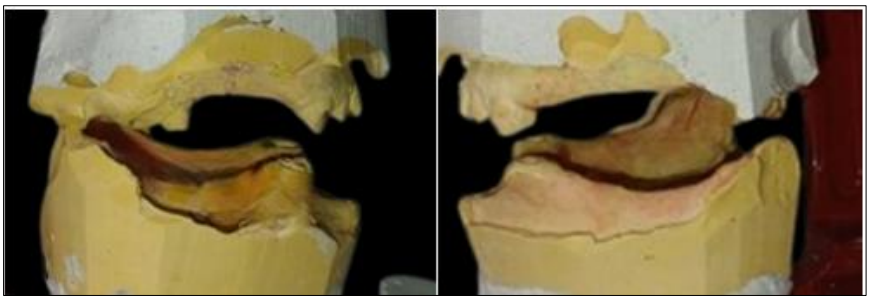

Figure 26: Occlusal registration



Figure 27: The sealing of the axial attachments and positioning of the female components



Figure 28: Spacing with a rubber dam sheet before placement of the female components



Figure 29: Incorporation of the female components into the prosthetic intaglio



Figure 30: Final view

A definitive anatomo-functional and situational impression was obtained using a custom tray and silicone impression material. The copings were incorporated into the impression, allowing simultaneous recording of the denture-bearing mucosa and the remaining dental structures.

Maxillomandibular relationships were recorded in centric relation and in a correct occlusion vertical dimension (OVD).

In the laboratory, the artificial teeth were mounted on wax bases, and a wax try-in was performed to assess aesthetics, occlusion, and phonetics.

Following clinical approval, the complete denture was processed using heat-polymerized acrylic resin. The copings carrying the axial attachments were permanently cemented onto the prepared abutment roots. The intaglio surface of the complete denture was recessed in front of the attachments. Occlusal contacts were verified, and selective occlusal adjustments were performed to achieve balanced occlusion.

The female components of the axial attachments were subsequently picked up directly into the denture base using autopolymerizing acrylic resin under controlled occlusal pressure, ensuring accurate positioning and optimal adaptation.

At the three-month follow-up, the patient reported satisfaction regarding both functional performance and aesthetic outcome. Clinical and radiographic examinations revealed no evidence of periapical pathology or other biological complications.

DISCUSSION

Several treatment options were considered, including a clasp-retained removable partial denture, implant-supported overdenture, and tooth-supported overdenture. The removable partial denture was considered unfavorable because of potential rotational movement and limitations in prosthetic tooth arrangement, while the implant-supported option was excluded due to financial constraints. A supra-radicular overdenture was therefore selected as a conservative alternative.

The use of axial attachments in overdentures for the rehabilitation of subtotal edentulism represents an interesting approach that reconciles function, aesthetics and biomechanical balance.

Preservation of strategically positioned residual tooth roots helps maintain alveolar bone and periodontal proprioception [5].

The decision of root preservation requires adequate periodontal health with sufficient attached gingiva, a hermetically sealed root canal filling, sufficient bone support, and a favorable position within the dental arch [5, 6].

This article discusses the application of a digital method for fabricating axial attachments in root-supported overdentures through a case report.

Ball attachments are considered among the simplest retention systems for clinical use. Compared with bar attachments, they are less bulky, require less vertical prosthetic space, and facilitate oral hygiene maintenance [5].

Through their design, axial attachments offer a mechanical push-button connection that ensures retention of the prosthesis on residual roots. This retention is mediated by frictional resistance between the male and female components of the attachment, which remain entirely concealed within the prosthesis.

The predictable outcome of axial attachment systems relies largely on impression accuracy, since this directly determines the fit between the post and the root canal and, consequently, the long-term prosthetic stability [3].

Conventional elastomeric impression techniques are highly technique-sensitive and may be affected by distortion, material retention, and volumetric changes, compromising the accuracy of post–root canal adaptation and bonding. These limitations have encouraged the development of more accurate and less operator-dependent digital alternatives [7].

Early CAD-CAM protocols relied on semi-direct workflows, scanning plaster models or polyvinylsiloxane (PVS) post space impression to mill the male part of the attachment. However, these multiple steps carry a higher risk of procedural error [4].

In contrast, the direct intraoral scanning of the post space offers superior trueness and precision [8].

In fact, the protocol described in this case report, involving direct intraoral scanning of the post space, is based on previous in-vitro research demonstrating the feasibility of this approach within a fully digital workflow for post and core fabrication.

Nevertheless, an in vitro study indicates that direct intraoral scanning is unreliable for post spaces deeper than approximately 14 mm, a limitation particularly relevant for shallow root canals. To overcome this limitation, using scan posts that provide predefined data allows for an accurate and complete digital impression of the post space [9].

As a result, the male part of axial attachments can be fabricated to match the root canal anatomy. The procedure consists of scanning the tooth both without

and with a scan post inside the post space that is prepared with specific compatible drills. This approach enables the IOS to directly capture the wider coronal portion of the root canal entrance, while the scan post facilitates accurate mapping of the prepared canal walls in deeper sections [8].

Indeed, the use of scan posts enhances the accuracy and reproducibility of digital impressions by providing a stable reference for capturing the geometry of the prepared root canal, particularly in deep or anatomically complex areas [8]. This results in a precisely fitting restoration with a thin, uniform cement layer, which may improve restoration longevity and reduce the risk of root fracture [7]. In another hand, the technique increases procedural complexity and requires accurate seating of the scan post to avoid scanning errors [8].

Compared with conventional techniques, the fully digital approach eliminates the need for plaster models, reduces material consumption, laboratory and chairside time, lowers costs, improves patient comfort, and enables permanent digital storage of impression data for easy retrieval and reuse [7]. Building upon the findings of post and core fabrication, Lee, has demonstrated that CAD/CAM fabrication of custom post-and-core restorations reduces technical sensitivity and treatment time while achieving favorable clinical outcomes [10].

CONCLUSION

Preserving residual roots for overdenture therapy offers valuable prosthetic benefits through the use of root-supported attachments. Successful treatment relies on appropriate root selection, careful attachment choice, and rigorous clinical execution and maintenance.

The integration of IOS with CAD/CAM technology, supported by scan posts provides a predictable efficient, and accurate alternative that addresses many of the limitations of conventional techniques.

Further in vitro investigations and clinical case series are warranted to validate, optimize, and standardize this technique for routine clinical use.

REFERENCES

1. Abdelkoui, A., Fajri, L., & Abdedine, A. (2012). Racines naturelles et implants au service de l'équilibre prothétique en prothèse amovible complète. *Cah de proth*, *12*, 159.
2. Tokar, E., Uludag, B. (2018). Novel Fabrication Technique for Root-supported Overdentures: A Case Report. West Indian Med J, 67(1), 89.
3. Shen, J., Chen, S., Chen, R., Zheng, Z., & Lin, J. (2026). Evaluation of the accuracy of direct digital impressions versus conventional silicone impressions for post-and-core with different root space diameters: a preliminary study in vitro. *BMC Oral Health*, *26*(1), 251.
4. Moustapha, G., AlShwaimi, E., Silwadi, M., Ounsi, H., Ferrari, M., & Salameh, Z. (2019). Marginal and internal fit of CAD/CAM fiber post and cores. International journal of computerized dentistry, 22(1).
5. ABDELKOUI A, ROKHSSI H, BENFDIL F, ME RZOUK N. Maîtriser les facteurs d'échec en prothèse amovible complète supra-radiculaire. Strat Proth. 2021(1), 58-65.
6. BOURAOUI S, MANSOUR L, TRABELSI M, CHA TER M. Exploitation des racines naturelles et artificielles en prothèse adjointe: Cas cliniques. Afr J Dent Implantol.2015, 23-35.
7. Lin, L., Cai, P., Zheng, Z., Zheng, Z., & Lin, J. (2025). Digital Impressions for Customized Post-and-Core Restorations in Deep and Narrow Canals: A Case Report Utilizing Scan Posts. *Case Reports in Dentistry*, *2025*(1), 4939176.
8. Lin, L., Lin, J., Shen, J., Chen, R., & Zheng, Z. (2026). Evaluation of the accuracy of two full-digital versus half-digital techniques for post-and-core with different root canal entrance diameters. *Journal of Prosthodontic Research*, *70*(1), 43-50.
9. Elter, B., Diker, B., & Tak, Ö. (2022). The trueness of an intraoral scanner in scanning different post space depths. *Journal of Dentistry*, *127*, 104352.
10. Lee, D. J. H. (2014). Accelerated techniques for a post and core and a crown restoration with intraoral digital scanners and CAD/CAM and rapid prototyping. *The Journal of prosthetic dentistry*, *112*(5), 1024-1029.

Cite This Article: Zayani, D., Mabrouk, Y., Saadellaoui, I., Fedaoui, Z., Triki, H., & Mansour, L. (2026). Fully Digital Fabrication of Intraradicular Axial Attachments for a Mandibular Root-Supported Overdenture Using Scan Posts: A Case Report. *EAS J Dent Oral Med, 8*(6), 225-236. https://doi.org/10.36349/easjdom.2026.v08i06.004