

Research Article

Significance of Panoramic Radiographic Examination of Edentulous Patients Prior To Denture Fabrication - A Survey

Dr. Shridevi Adaki^{1*}, Dr. Amol Karagir¹, Dr. Kaushal Shah¹, Dr. Raghavendra Adaki¹

¹Associate Professor, Dept of Oral Medicine and Radiology B. V. D. U. Dental College, Sangli – 416414, India

*Corresponding Author
 Dr. Shridevi Adaki

Abstract: **Aim:** The purpose of this study was to determine the frequency of significant radiographic findings in edentulous jaws and analysis of those findings for age, sex and location of their occurrence by the panoramic radiograph taken before denture fabrication. **Materials and methods:** 170 edentulous patients were randomly selected who are without any clinical signs and symptoms of pain or any infection. Panoramic radiograph of all samples were taken and evaluated for findings like root stumps, impacted teeth, radiolucencies, radiopacities, and also the space between the alveolar crest and maxillary sinus and mental foramen. The findings were then analyzed for the sex and region of their occurrence. **Results:** out of 170 patients 68 (40%) showed positive radiographic findings. Out of 40% (n=68), 22.05% (n=15) patients had one or more remaining root fragments, 11.76% (n=8) had impacted teeth, 4.41% (n=3) demonstrated radiopacities, 2.94% (n=2) demonstrated radiolucencies, 27.94% (n=19) mental foramina was near the crest of the residual alveolar ridge, 39.88% (n=21) maxillary sinus was close the crest of the residual alveolar ridge. Application of the Chi-square test has shown that root fragments, maxillary sinus and mental foramen was a highly significant entity in comparison to the other entities. **Conclusion:** Considering all the above factors, panoramic radiographic evaluation done prior to denture fabrication gives the better treatment outcome. Rather than facing the problems after treatment it is better to evaluate before treatment which reduces patient's discomforts after denture insertion.

Keywords: Impacted teeth, mandibular canal, maxillary sinus.

INTRODUCTION:

Benefits from dentures can be achieved by denture's stability and retention which is because of good foundation support. Thus the alveolar bone should be free from the pathologies that can be either intrabony or soft tissue pathosis. The early diagnosis of such pathologies of the jaws, which are otherwise asymptomatic, can only be achieved through radiographic examination. Healthy looking mucosa covering alveolar ridges of an edentulous patient are usually not suspected of harboring any pathology (Jindal, S. K. *et al.*, 2011).

The panoramic imaging is a radiologic technique for producing a single image of the facial structures including both the maxillary and mandibular arches and their supporting structures (White, S.C., & Pharoah, M.J. 2000) and it is best imaging modality which can be used to screen edentulous patients before complete denture therapy.

With recent concern about the cumulative effects of radiation exposure, routine radiographic examination of edentulous patients is being questioned. But the discovery of potentially complicating conditions indicates radiographic examination of edentulous patients. Moreover the radiographic guidelines titled "The Selection of Patients for X-Ray Examination" developed in 1987 by a panel of dental experts convened by the Center for Devices and Radiological Health of the U.S. Food and Drug Administration (FDA) and endorsed by the American Dental Association recommends a full mouth intraoral or panoramic radiographic examination for newly edentulous patients (Bohay, R. N. *et al.*, 1998). In contrast European Guidelines on Radiation Protection in Dental Radiology doesn't recommend radiographic examination in case of healthy edentulous patients (Martínez Beneyto, Y. *et al.*, 2007). On the other hand, some investigators recommended the use of the

Quick Response Code



Journal homepage:

<http://www.easpublisher.com/easjdom/>

Article History

Received: 22.11.2019

Accepted: 06.12.2019

Published: 18.12.2019

Copyright © 2019 The Author(s): This is an open-access article distributed under the terms of the Creative Commons Attribution 4.0 International License (CC BY-NC 4.0) which permits unrestricted use, distribution, and reproduction in any medium for non-commercial use provided the original author and source are credited.

DOI: 10.36349/easjdom.2019.v01i06.004

radiographic examination when necessary, when there are symptoms or only when the needs call (Al-Faleh, W. *et al.*, 2005). In addition, the radiographic examination may reveal anatomic variations that could influence prosthetic treatment and their outcome, such as the location of the mandibular canal, the position of the mental foramen and maxillary sinus, and relative thickness of the soft tissue covering the edentulous ridge.

Considering all the above factors this study was planned to quantify the frequency of positive radiographic findings in edentulous arches by panoramic imaging and the findings were analyzed for the sex and region of their occurrence.

MATERIALS AND METHODOLOGY:

The study was conducted at BVDUDCH, Sangli and 170 completely edentulous patients were selected randomly from the out-patient Department of Oral Medicine, Diagnosis and Radiology. Informed consent of all the participants was taken. Patients with systemic disorders like Diabetes Mellitus, Hypertension, Malignancies, Blood Dyscrasias, Kidney Disorders or long standing infections were excluded from the study. Intraoral examination of the patients was done for completely edentulous arches with absence of findings like pain or tenderness over the arches, root stumps, swelling.

Sample Size Was Calculated By Using the Formula As Mentioned Below

$p = 47.6\%$ (considered by review of literature) – positive percentage

$q = 100 - p = 52.4\%$

$\alpha = 5\%$ - level of significance.

$Z\alpha = 2.58$

$d = \text{error} = 10\%$

$$n = \frac{Z\alpha^2 \cdot pq}{d^2}$$

$$= 166.02 \sim 170$$

Once the clinical examination was completed the panoramic radiograph for all patients was taken using Panoramic machine (Vatech digital X-ray imaging system, model PCH 2500, 2014, Made in Korea) with kVp of 65 – 90 and standard 10 mA provided with a total filtration of 2.8mm aluminium. Exposure parameters selected were 65 kVp and 10 mA. Exposure time was 18 seconds.

The radiographs were evaluated by Oral Radiology specialists for the following clinically significant radiographic findings: Retained root fragments, impacted teeth, Radiolucencies like cysts, Radiopacities like localized sclerotic bone formation, Location of the mental foramen near to the alveolar crest, and Location of the maxillary sinus close to the crest of the ridge. These positive findings are correlated with the sex and location of the occurrence.

RESULTS

Out of the 170 patients, 40% patients (n=68) showed positive findings on panoramic radiograph. Among them 35 (51.47%) were male patients and 33 (48.53%) were female patients with a mean age of 61years (48-74 years of age). Out of 40% (n=68), 22.05% (n=15) patients had one or more remaining root fragments, 11.76% (n=8) had impacted teeth, 4.41% (n=3) demonstrated radiopacities, 2.94% (n=2) demonstrated radiolucencies, 27.94% (n=19) mental foramina was near the crest of the residual alveolar ridge, 39.88% (n=21) maxillary sinus was close to the crest of the residual alveolar ridge (Table 1). Application of the Chi-square test has shown that root fragments, maxillary sinus and mental foramen was a highly significant entity in comparison to the other entities.

Table I: Number and percent of radiographic entities

RADIOGRAPHIC ENTITY	NO OF CASES	%
Root fragments	15	22.05%
Impacted teeth/embedded teeth	8	11.76%
Radiolucencies And mixed lesions	2	2.94%
Radiopacities	3	4.41%
Mental foramina near the crest of the residual ridge	19	27.94%
Maxillary sinus close to the crest of the residual ridge.	21	39.88%
Total	68	

Table II: Distribution of cases according to gender

RADIOGRAPHIC ENTITY	MALE	FEMALE	NO OF CASES
Root fragments	9	6	15
Impacted teeth/embedded teeth	5	3	8
Radiolucencies And mixed lesions	0	2	2
Radiopacities	2	1	3
Mental foramina near the crest of the residual ridge	10	9	19
Maxillary sinus close to the crest of the residual ridge.	9	12	21

Total	35	33	68
-------	----	----	----

Table III: Distribution of cases according to the location of their occurrence

RADIOGRAPHIC ENTITY	Max	Mand	NO OF CASES
Root fragments	7	8	15
Impacted teeth/embedded teeth	2	6	8
Radiolucencies And mixed lesions	0	2	2
Radiopacities	1	2	3
Mental foramina near the crest of the residual ridge	-	19	19
Maxillary sinus close to the crest of the residual ridge.	21	-	21
Total	31	37	68

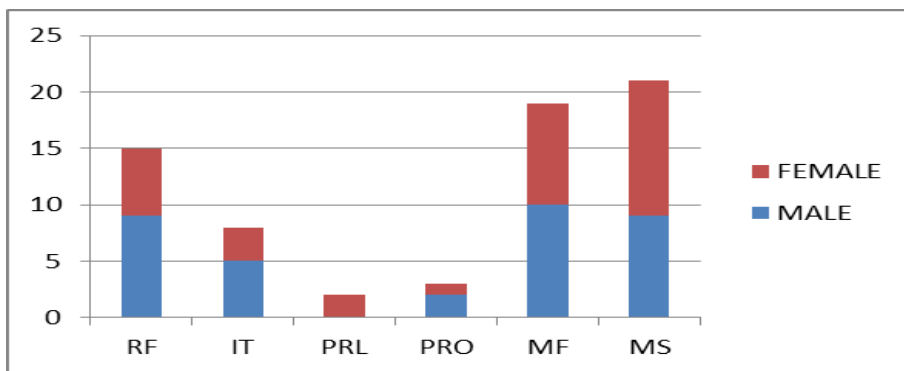


Fig 1: Graph showing the number of positive findings along with distributing them according to the gender

RF- root fragments

IT- impacted teeth

PRL- pathologic radiolucency

PRO- pathologic radiopacity

MF- Mental foramina near the crest of the residual ridge

MS- Maxillary sinus close to the crest of the residual ridge

Root Stumps

A total of 32 root stumps were found in (n=15) patients. Single root was found in 5 patients, two roots were found in 7 patients and 3 roots were found in 3 patients. Maximum number of root stumps found was four which were found in 1 patient. Out of 15 positive cases 40% (n=6) were females and 60% (n=9) were males (Table 2, Fig 1). Most of the roots were located in maxillary right quadrant (n=12) followed by maxillary left quadrant (n=9), mandibular left quadrant (n=7) and mandibular right quadrant (n=4). Statistically there was no significant difference found in the ratio of retained root stumps in all the four quadrants.

Impacted Teeth

A total of 14 embedded teeth were found in (n=8) patients. Single embedded tooth was found in 7 patients and two embedded teeth were found in 2 patients. Maximum number of embedded teeth found was three which were found only in 1 patient. Out of 8 positive cases 37.5% (n=3) were females and 62.5% (n=5) were males (table 2, 3). Most of the embedded

teeth were located in the mandibular left quadrant (n=5) followed by mandibular right quadrant (n=4) and maxillary right quadrant (n=3). Maxillary left quadrant was found to harbor 2 embedded teeth. Statistically there was no significant difference found in the ratio of impacted teeth in all the four quadrants.

Radiolucencies

A total of 3 radiolucencies were found in 2 patients. Out of 2 positive cases all were found in females. and Out of these 3 radiolucencies 2 were diagnosed as residual cysts, and 1 as osteoporotic areas.

Radiopacities

A total of 3 radiopacities were found in 3 patients. Out of 3 positive cases 66.66% (n=2) were males and 33.33% (n=1) was female. Out of these radiopacities were diagnosed as osteosclerosis.

Mental Foramen Near To the Crest of Residual Alveolar Ridge

In patients the mental foramen was situated near to the crest of the residual alveolar ridge. Out of 19 positive cases 47.36% (n=9) were females and 52.63% (n=10) were males.

Maxillary Sinus Was Close To The Crest Of The Residual Alveolar Ridge.

In patients the maxillary sinus was situated close to the crest of the residual alveolar ridge. Out of 21 positive cases 57.14% (n=12) were females and 42.85% (n=9) were males.

DISCUSSION

In the present study, the panoramic radiographic examination of 170 completely edentulous

patients revealed positive radiographic findings in 40%. This prevalence rate is similar to the value noted in previous study by Massod *et al.*, (2007).

The present study revealed 22.05% of root stumps on radiograph. So it is beneficial if we take radiograph before and after extraction of teeth to avoid this. Retained root stump can lead to periapical infections causing complication for denture fabrication. But there is controversy for removal of retained root stumps also. Because the root stump helps in maintaining the integrity of bone as bone resorption rate slows down in presence of root when compared to edentulous arch.

Prevalence of impacted teeth is 11.76% in the present study which is topic of discussion even in dentulous patients. As impacted teeth can have infection around the crown in follicular spaces leading to formation of cyst and tumors if left untreated. Some impacted teeth never erupt and will remain embedded within bone throughout life without any pathology. So there is controversy in advising extraction for impacted teeth. But studies (Adaki, S. R. *et al.*, 2013) have shown incidence of pathologies in impacted teeth. In edentulous patients forces applied on denture are transmitted to bone above impacted tooth leading to resorption of bone and exposure of tooth to oral cavity. This causes problems in wearing dentures and possibilities leading to refabrication of dentures. To avoid such problems it is better to take radiograph before fabrication of dentures.

The present study revealed 2 radiolucencies which are of residual cyst. Residual cyst is one which was retained after removal of affected tooth. Residual cyst may remain latent, can get enlarged or infected. In such cases denture wearing becomes difficult for patients.

3 radio-opacities are seen, 2 in men and 1 in women in the present study. These radiopacities were diagnosed as osteosclerosis. These less likely progress and cause some problem. But early diagnosis and periodic follow up should be done in such cases.

After the teeth extraction, the maxillary sinus drifts down leaving no space between the floor of antrum and crest of the ridge. This causes difficulty in cases where implant supported dentures are planned. This also depends on the duration of the edentulism. As duration increases the space reduces. So patient's

awareness in such cases helps for better treatment outcomes.

Similarly in the mandible, space between the mental foramen and crest of alveolar ridge reduced as duration of edentulism increases. This also depends on the rate of bone resorption which in turn is dependent on systemic health of the patient.

CONCLUSION

Considering all the above factors, panoramic radiographic evaluation done prior to denture fabrication gives the better treatment outcome. Rather than facing the problems after treatment it is better to evaluate before treatment which reduces patient's discomforts after denture insertion.

REFERENCES

1. Jindal, S. K., Sheikh, S., Kulkarni, S., & Singla, A. (2011). Significance of pre-treatment panoramic radiographic assessment of edentulous patients--a survey. *Med Oral Patol Oral Cir Bucal*, 16(4), e600-6.
2. White, S.C., Pharoah, M.J. (2000). *Oral Radiology Principles and Interpretation, ed 4. Philadelphia: Mosby:205-6.*
3. Bohay, R. N., Stephens, R. G., & Kogon, S. L. (1998). A study of the impact of screening or selective radiography on the treatment and postdelivery outcome for edentulous patients. *Oral Surgery, Oral Medicine, Oral Pathology, Oral Radiology, and Endodontology*, 86(3), 353-359.
4. Martínez Beneyto, Y., Alcaráz Baños, M., Pérez Lajarín, L., & Rushton, V. E. (2007). Clinical justification of dental radiology in adult patients: a review of the literature. *Medicina Oral, Patología Oral y Cirugía Bucal (Internet)*, 12(3), 244-251.
5. Al-Faleh, W., Mansour, S., & Ibrahim, M. E. (2005). The value of pre-operative radiographic examination Of edentulous patients prior to denture construction: The risk versus the benefit. *Egyptian Dental Journal*, 51, 1853-1857.
6. Masood, F., Robinson, W., Beavers, K. S., & Haney, K. L. (2007). Findings from panoramic radiographs of the edentulous population and review of the literature. *Quintessence International*, 38(6).
7. Adaki, S. R., Yashodadevi, B. K., Sujatha, S., Santana, N., Rakesh, N., & Adaki, R. (2013). Incidence of cystic changes in impacted lower third molar. *Indian Journal of Dental Research*, 24(2), 183.