

## Research Article

# Improving Medical Diagnostic Tactics and Surgical Treatment of Chronic Generalized Periodontitis

E. Gaybullaev

Tashkent State Dental Institute

### Article History

Received: 04.01.2020

Accepted: 21.02.2020

Published: 28.02.2020

### Journal homepage:

<https://www.easpublisher.com/easjdom>

### Quick Response Code



**Abstract:** This article presents data on the effect of osteotropic materials on the course of chronic generalized periodontitis and features of the surgical tactics of treating this disease. Data on 3-D computed dental tomography are presented taking into account the determination of bone mineral density, which may become a priority in radiology and surgical dentistry. The effectiveness of using the T-criterion of densitometric analysis as a kind of marker in the assessment of both short-term and long-term forecasts of surgical treatment is confirmed. The results are presented, the corresponding conclusions are made.

**Keywords:** 3-D computed dental tomography; densitometry; osteotropic material; chronic generalized periodontitis.

**Copyright © 2020 The Author(s):** This is an open-access article distributed under the terms of the Creative Commons Attribution **4.0 International License (CC BY-NC 4.0)** which permits unrestricted use, distribution, and reproduction in any medium for non-commercial use provided the original author and source are credited.

## RELEVANCE

With the progress of civilization, the prevalence of periodontal diseases has risen sharply and has gained importance as general medical and social problems. This is due to the fact that periodontitis leads to tooth loss, and foci of infection in periodontal pockets adversely affect the body as a whole. The cause of inflammatory periodontal diseases can be various factors, the main of which is recognized as microbial. A genetic predisposition for the development of periodontal diseases was revealed and their dependence on somatic diseases was proved (Button, T. M. *et al.*, 1999; Cho, P.S. 2015; Clifton, T. L.1998; Danesh-Meyer, M. J. *et al.*, 2002; & De Smet, E. *et al.*, 2002). According to recent studies (Anderson, T. 2019; Bayoumi, S. 2014; & Berkhout, W. E. R. *et al.*, 2002), the universal basic mechanism for the development of all pathological processes is excessive lipid peroxidation in response to the damaging effect of an infectious agent. Emerging with the development of dental technology to optimize the treatment process, new progressive techniques can improve the quality of life of patients with inflammatory periodontal diseases. The problem of the effectiveness of the diagnostic process in the 21st century will be solved by introducing the PARODONTAL LIFE automated system into the periodontal patient examination process, which allows monitoring the course of the disease in dynamics, eliminating the need for repeated x-ray

examination, confirming the effectiveness of treatment measures, while motivating the patient to improve oral hygiene. The study of the mechanisms of etiopathogenesis of periodontal diseases substantiates the need to search and include in complex therapy methods that eliminate the negative effects of oral microflora, effectively eliminate the effects of impaired metabolism in periodontal tissues as soon as possible, and also increase the quality of life of patients with inflammatory periodontal diseases.

In modern dentistry, the role of the X-ray method cannot be called auxiliary. This was facilitated by significant advances in dental science and practice, progress in the development of x-ray and computer technology over the past three decades.

Success in the treatment and rehabilitation of patients with disorders of the dentofacial system is due to the widespread use of unique high-tech technologies, the latest specialized equipment materials, equipment, instruments that meet the highest requirements. The possibilities of clinical diagnosis of diseases and injuries of the dentition are in many cases limited due to the non-specificity of the symptoms and the fact that more than 50% of the surface area of the teeth is not visible during external examination and can only be studied radiographically. In this case, defects and errors in the treatment of diseases of hard tissues of the teeth,

periodontal and periodontium in the absence of x-ray control or its irrational use reach 40-75% (Abeloos, J. 2017; Analoui, M. 1999; & Bahrami, G. *et al.*, 2003).

Therefore, the creation of automated monitoring of the state of bone tissue is becoming relevant today.

#### **Purpose of the study:**

Conduct a randomized study to assess in the short and long term the determination of bone mineral density based on clinical, functional and radiological research methods.

## **MATERIALS AND METHODS:**

To achieve this goal, the results of examination and treatment of 220 patients with varying degrees of severity of chronic generalized periodontitis were analyzed. Written informational consent was obtained from each patient to participate in the experiment. Of 220 patients - 116 men and 104 women. The age of patients is 22-65 years. The median age was 43.5 years. All examined patients were divided into 2 groups: group 1 - the main group, which consisted of 124 patients with varying severity of clinical manifestations of chronic generalized periodontitis of moderate and severe degree, who were evaluated by x-ray examination on a 3-D computer i-SCAT dental tomograph, which Bone mineral density was also determined using the Lunar Prodigy Advance densitometric device. T and Z criteria were taken into account. The control group included 96 patients with various clinical manifestations of chronic generalized periodontitis, who underwent only orthopantomography. Easy graft was used as an osteotropic material to replace a bone defect in the main group which is  $\beta$ -3 calcium phosphate. Closed curettage was performed in the control group. Treatment methods included clinical and radiological.

Clinical examination of patients began with the identification of complaints, a history of life and disease. Particular attention was paid to studying the features of the onset of the disease and its development before treatment, the number and nature of relapses, the timing of reduction and disappearance of bleeding gums, the presence and nature of detachable from periodontal pockets. When examining the oral cavity, we determined: the type of occlusion, the presence of

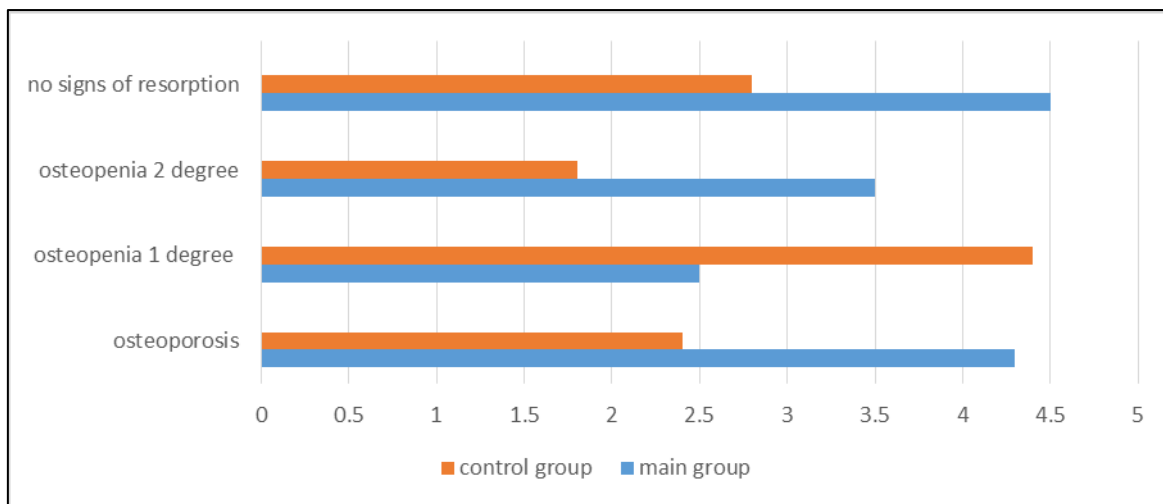
deformations and shortening of the frenum of the upper and lower lips, the state of the vestibule of the oral cavity was assessed, the presence of supracontacts, trauma to the gums with fillings and prostheses, the degree of tooth mobility and the severity of the destruction of periodontal bone tissue in the area of each tooth using sensing. To determine the condition of periodontal tissues, as well as to evaluate oral hygiene in a clinical setting, an index study was performed.

For an operation according to Widmann-Neumann, an incision was made after anesthesia, departing 0.5-1 mm from the gingival margin at an angle of 30-35 ° to the crest of the alveolar arch, while maintaining the scalloped gingival margin. When performing this section, the pocket epithelium and part of the infiltrated connective tissue were cut off from the surrounding tissues. At the same time, the marginal gum becomes thinner, which contributes to the correct reposition of the flap after surgery. Then, using the elevator, the flap was thrown back to expose the alveolar process. A second incision was made along the gingival sulcus around each tooth. In this case, the pocket epithelium and connective epithelium are separated from the root surface. A horizontal incision serves the accurate and atraumatic release of periodontal tissue and granulation. The altered tissue of the gingival margin, granulation, tartar deposits were removed. The surface of the roots of the teeth was mechanically and medically treated. Osteoplastic material was placed in a bone defect. Statistical research methods included the Student-Fisher test, the non-parametric Mann-Winy test.

## **THE RESULTS OF THE STUDY:**

The study of bone mineral density showed that in women of the main group, as a percentage of the age norm, it was  $79.34 \pm 1.88\%$  ( $p \leq 0.05$ ), and in individuals of the comparison group -  $98.95 \pm 1.51\%$ . BMD values relative to the age peak of mineralization in patients with chronic generalized periodontitis also decreased from the control to the main group: the lowest bone mineral density was in the main group and amounted to  $77.65 \pm 1.97\%$  ( $p \leq 0.05$ ), persons of the comparison group -  $97.13 \pm 1.63\%$  In the figure №1.

The results of densitometric studies are presented. It should be noted that severe forms of bone tissue pathology (osteoporosis and grade III osteopenia) did not occur.



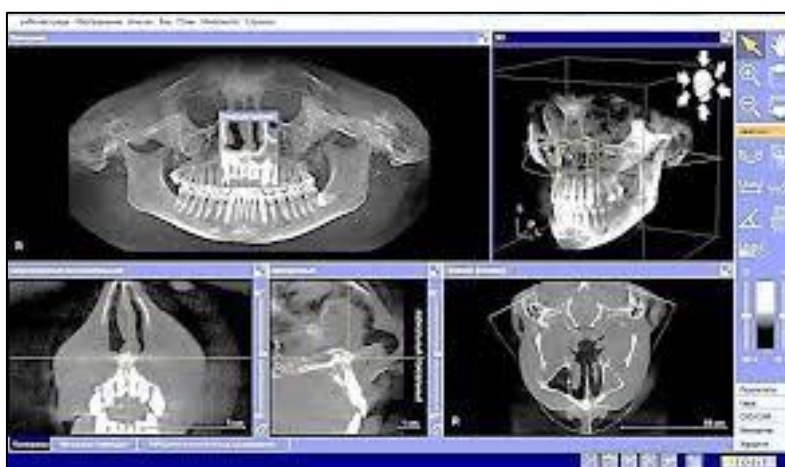
**Fig. 1.** The frequency of osteoporosis and osteopenia in patients with chronic generalized periodontitis in the main and control groups.

Based on the data in the group of patients who used  $\beta$ -three calcium phosphate during surgical treatment, the reduction in the depth of periodontal pockets occurred much faster than in the comparison group. On the orthopantomogram in terms of 2 and 12 months in the main group and the comparison group, there was a tendency to normalize the bone pattern and to increase the bone level, which is explained by the normalization of metabolic processes due to a decrease in inflammatory phenomena, as well as ongoing regenerative processes. At the same time, a number of differences were revealed between the main and the comparison group. In the period of 2 months, despite the presence of periodontal pockets, with moderate severity of chronic generalized periodontitis in the main group on the orthopantomogram, restoration of the cortical plate contour was noted in many areas. In the

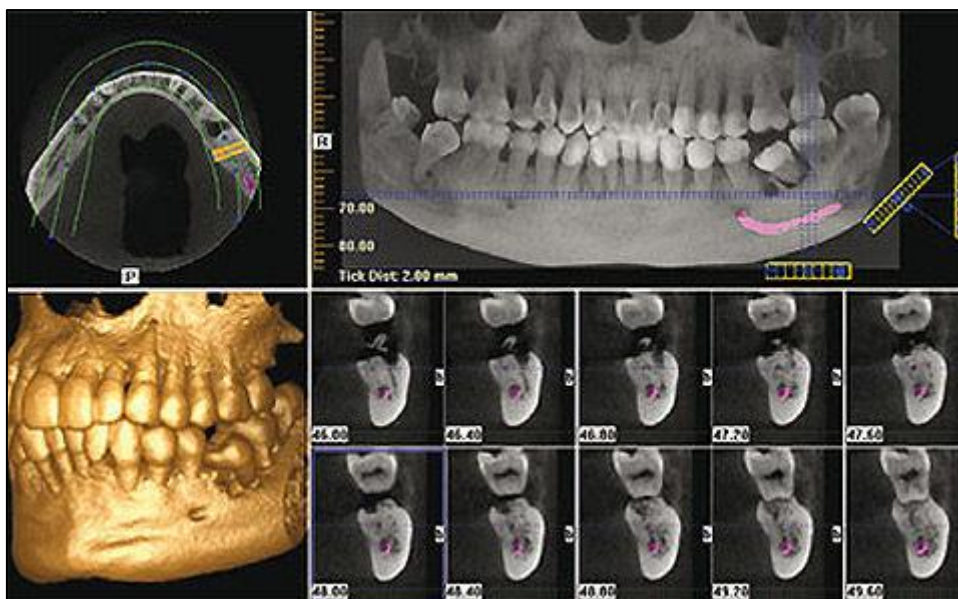
comparison group on the panoramic radiograph, no significant changes were noted. In patients with severe periodontitis in the main and comparison subgroups, the same trends were detected, but less pronounced due to the greater prevalence and intensity of the inflammatory process. After 12 months, a repeated X-ray examination showed, with the use of  $\beta$ -three calcium phosphate and OTP, a pronounced stabilization of the process both in chronic generalized periodontitis of moderate severity and in severe forms of this disease. The bone pattern has a finely looped structure, there is a clearly defined cortical plate. There are no bone pockets, an increase in the level of bone tissue is observed. In patients undergoing surgical treatment, where xenogenic apatite was used in combination with OTP, insignificant positive trends were noted at the same time.

On 3-D computerized dental tomography (Fig. 2), the zone of granulation of bone tissue is visible in the main group, foci of bone tissue appear, gum recession decreases by 87.6% ( $p \leq 0.05$ ), areas of the

leukocyte shaft appear, which indicates body response to osteoplastic material. But, after 12 months, the zone of inflammation disappears, a trabecular plate of bone tissue appears, lacunar resorption disappears



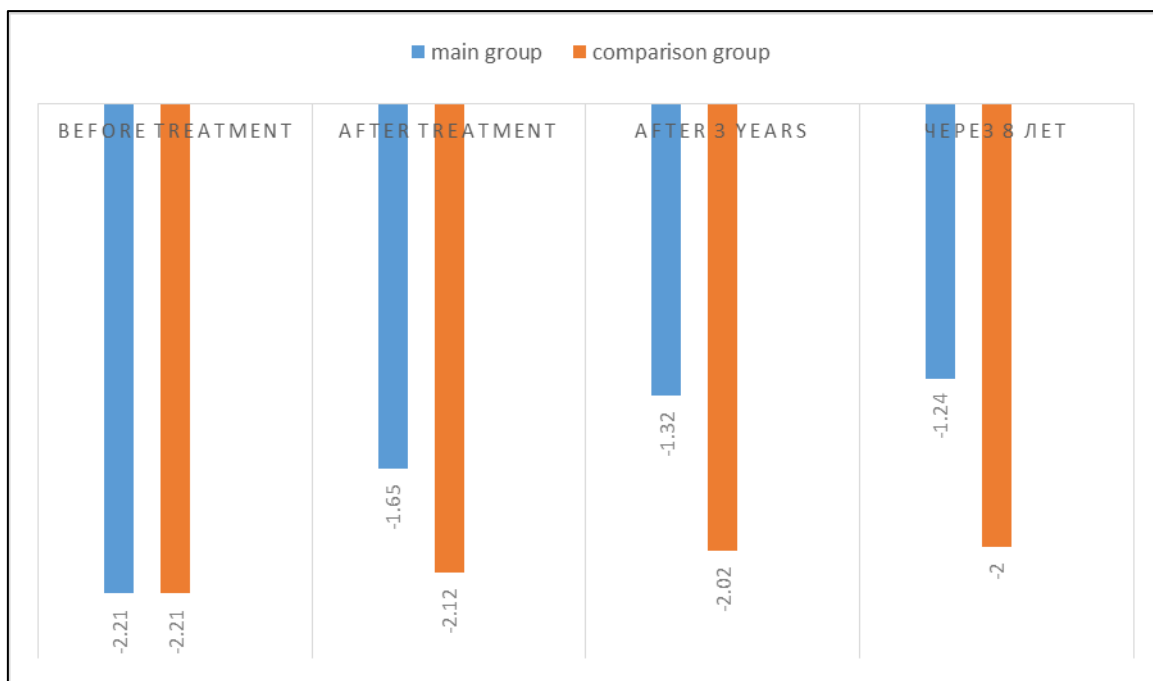
**Fig. 2.** Data 3-D computed tomography in patients with chronic generalized periodontitis of the main group



**Fig. 3.** Application and analysis of the PARODONTAL LIFE program for 3-D visualization of the alveolar ridge

In patients with various degrees of severity of chronic generalized periodontitis, differences with the level of the T-criterion were revealed: in patients with moderate severity, the indicator of X-ray absorptiometry is 2.13 -0.37; severe severity average x-ray absorptiometry -2.51. These data show a reliable relationship of osteodystrophic processes with certain degrees of severity of chronic generalized periodontitis.

Based on the data presented, it is possible to note the positive effect of surgical treatment of inflammatory and dystrophic periodontal lesions as part of the diagnostic algorithm in patients with signs of osteopenia. So, in the main group, the improvement of the T-criterion from -2.21 to -1.32 ( $p \leq 0.001$ ) was observed in almost all patients (98.7%). Whereas in the comparison group the improvement of the T-criterion was not reliably determined (-2.21 to -2.12,  $p \leq 0.001$ ).



**Fig. 4.** The dynamics of the data of x-ray absorptiometry of the forearm in patients with chronic generalized periodontitis before, after and after 3 and 8 years.

## FINDINGS

1. The use of the surgical method for the treatment of chronic generalized periodontitis using various osteoplastic materials has been proven as a modern treatment method.
2. The use of osteoplastic materials has led to an increase in bone mineral density in the main group to improve the T-criterion, which both in the short and long term is of certain importance in the form of reducing osteoporosis, which is manifested in reducing the number of fractures and improving wound healing, which gives reason to recommend this method of treatment as the main method of treatment of inflammatory and dystrophic periodontal lesions.

## BIBLIOGRAPHY:

1. Abeloos, J. (2017). Patient-Specific Reconstruction Plating. / J. Abeloos, T. Clijmans, F. Gelaude, M. Mommaerts, J. Vander Sloten. // XXth congress of the European Association for Cranio-Maxillo-Facial Surgery. - Bruges, Belgium.-P. 117.
2. Akesson, L., Rohlin, M., & Håkansson, J. (1989). Marginal bone in periodontal disease: an evaluation of image quality in panoramic and intra-oral radiography. *Dentomaxillofacial Radiology*, 18(3), 105-112.
3. Analoui, M. (1999). Digital diagnostic imaging: today and tomorrow. *Dentomaxillofacial Radiology*, 28(1), 56-58.
4. Anderson, T. (2019). Dental radiology for the new millennium. / T. Anderson // J Colo Dent Assoc. # 78 (2). - P. 25-30:
5. Bahrami, G., Hagström, C., & Wenzel, A. (2003). Bitewing examination with four digital receptors. *Dentomaxillofacial Radiology*, 32(5), 317-321.
6. Bayoumi, S. (2014). Does Magnetic Resonance Imaging Of The Temporomandibular Joint Have Any Impact On Treatment Decisions? / S. Bayoumi, J. Stocker, N. Hedley // XXth congress of the European Association for Cranio Maxillo-Facial Surgery. Bruges, Belgium, P. 186-187.
7. Bedard, A., Davis, T. D., & Angelopoulos, C. (2004). Storage phosphor plates: how durable are they as a digital dental radiographic system. *J Contemp Dent Pract*, 5(2), 57-69.
8. Bell, D.J. (2018). Multidetector CT in the investigation of vocal cord palsy. / DJ. Bell; E.K. Woo // 21st Annual Meeting and Postgraduate Course of the European Society of Head and Neck Radiology (ESHNR). CICG, November 6-8,-P. fifteen.
9. Berkhout, W. E. R., Sanderink, G. C. H., & Van der Stelt, P. F. (2002). A comparison of digital and film radiography in Dutch dental practices assessed by questionnaire. *Dentomaxillofacial Radiology*, 31(2), 93-99.
10. Button, T. M., Moore, W. C., & Goren, A. D. (1999). Causes of excessive bitewing exposure Results of a survey regarding radiographic equipment in New York. *Oral Surgery, Oral Medicine, Oral Pathology, Oral Radiology, and Endodontology*, 87(4), 513-517.
11. Cho, P.S. (2015). Cone-beam CT for radiotherapy applications. / P.S. Cho, R.H. Johnson, T.W. Griffin // Phys. Med. Biol. - V. 40. - P. 1863.
12. Clifton, T. L., Tyndall, D. A., & Ludlow, J. B. (1998). Extraoral radiographic imaging of primary caries. *Dentomaxillofacial Radiology*, 27(4), 193-198.
13. Danesh-Meyer, M. J., Chen, S. T., & Rams, T. E. (2002). Digital subtraction radiographic analysis of GTR in human intrabony defects. *International Journal of Periodontics & Restorative Dentistry*, 22(5). 441-449.
14. De Smet, E., Jacobs, R., Gijbels, F., & Naert, I. (2002). The accuracy and reliability of radiographic methods for the assessment of marginal bone level around oral implants. *Dentomaxillofacial Radiology*, 31(3), 176-181.