

Case Report

“Short Copings Overdenture”

Nadeem Yunus¹, Noopur Rathi^{*2} & Nishant Gaba³

¹Professor, Department of Prosthodontics, JMI dental college, JMIU

²Reader, Department of Prosthodontics, DJ College of dental sciences, BRAU

³Senior lecturer, Inderprastha dental college and hospital, CCSU

Article History

Received: 19.02.2020

Accepted: 02.03.2020

Published: 03.04.2020

Journal homepage:

<https://www.easpublisher.com/easjdom>

Quick Response Code



Abstract: Natural teeth are vital to the preservation of residual alveolar ridge. Conservative and preventive principles of prosthodontics are practiced when natural teeth are retained rather than extracted. The use of overdenture is an exemplary example of such principles. Overdenture with copings is not routinely prescribed. We present a case of an elderly male patient who presented with missing teeth. A tooth supported overdenture that involved both coping and non coping designs was fabricated.

Keywords: endodontic, tooth supported, immediate dentures, coping, amalgam.

Copyright © 2020 The Author(s): This is an open-access article distributed under the terms of the Creative Commons Attribution 4.0 International License (CC BY-NC 4.0) which permits unrestricted use, distribution, and reproduction in any medium for non-commercial use provided the original author and source are credited.

INTRODUCTION

Retention of teeth or its roots under a complete denture was recognized in the nineteen sixties which saw the launching of the concept of overdenture (Ledger, E. 1856; & Atkinson, W.H. 1861). The retaining of natural teeth provides all the biological advantages that the tooth possesses except those involving occlusal contacts. These include the control over bone resorption, directional sensitivity and psychological well-being (Morrow, R. *et al.*, 1969; & Crum, R., & Rooney, G. 1978). A tooth supported overdenture can be of different types which are broadly categorized into a coping retained or a non-coping retained overdenture (Renner, R.P., & Levy, M. 1977). The purpose of the coping in the overdenture is primarily to minimize the wear between two different surfaces, namely the natural tooth structure and the overlying denture acrylic resin. When one coping is placed on the tooth and the other within the denture, the surfaces being same in nature do not wear thus maintaining the vertical dimensions of

the denture. The purpose of this article is to present a case of overdenture where only one coping was possible due to limitations in complete denture design.

CASE REPORT

An elderly male patient aged 59 years reported to the department of prosthodontics with a chief complaint of inability to chew food since last two years due to absence of teeth. Medical history revealed the patient was a known diabetic and hypertensive since last five years and was taking medicines regularly for controlling both conditions. Extra oral examination revealed normal clinical features (**Fig 1a**) while intra oral examination revealed presence of maxillary right second premolar while mandibular anterior teeth were present along with one posterior tooth on each side. After thorough clinical history recording.

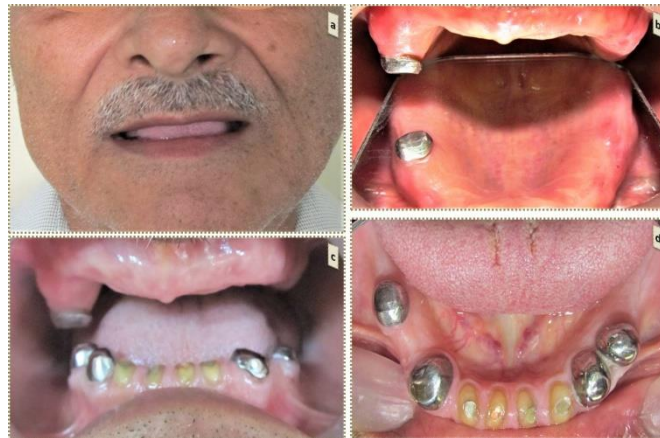


Figure 1: (a) Extra oral view (b) Maxillary coping (c) Mandibular copings (d) Mandibular incisors with amalgam plugs.

Radiographic and biochemical investigations the treatment options presented to the patient included overdenture prosthesis as the most conservative choice, immediate complete denture for maxillary arch and a cast partial denture for mandibular arch. Extraction of teeth followed by conventional complete denture was the least recommended choice. The patient consented for the overdenture treatment of both arches. All remaining teeth were required to undergo oral prophylaxis, pocket elimination procedures, endodontic

treatment and fabrication of amalgam stops. The overdenture treatment was initiated after ten weeks of completion of endodontic treatment. For maxillary denture a single coping was fabricated (**Fig 1b**) while for mandibular overdenture four short copings (two canines, left first premolar and right molar) were fabricated and cemented in place (**Fig 1c**). Mandibular incisors were incorporated within the overdenture using silver.

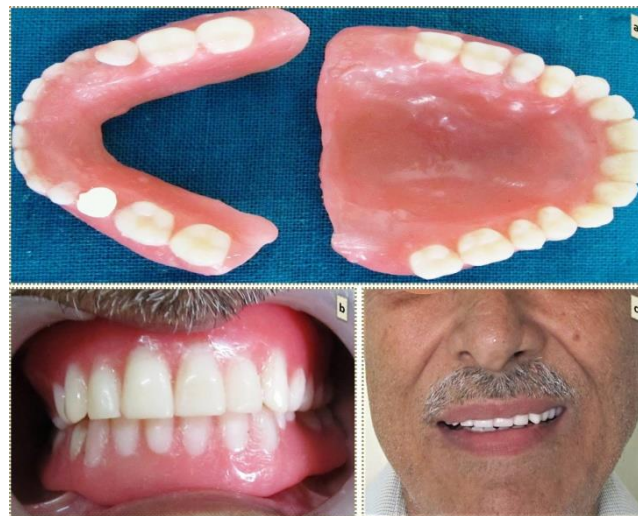


Figure 2: (a) Finished complete overdenture prosthesis (b) Occlusal view (c) Post insertion extra oral view

Amalgam stops (**Fig 1d**). Routine clinical and laboratory procedures for fabrication of complete overdenture were done except one exception. The mandibular denture did not have the customary coping within the denture (**Fig 2a**). On the day of denture insertion, the occlusion was corrected using a clinical remount procedure (**Fig 2b**) and post insertion instructions were given to the patient. On subsequent follow up visit, the patient expressed his satisfaction with the prosthesis. (**Fig 2 c**)

DISCUSSION

Overdenture treatment is indicated for all ages, more so it is an ideal treatment when there are few natural teeth remaining and a cast partial denture cannot be given. It also allows patients to transit from natural to artificial teeth, thus increasing acceptance of the patient. The medical history of the patient revealed two important underlying medical conditions that could affect the prognosis of the overdenture in this case. Both diabetes and hypertension are prone to develop physiological xerostomia as well as the drug induced xerostomia, since daily drug regime is to be practiced. Xerostomia can lead to the development of secondary

caries under the coping while also increase the halitosis (Mattoo, K. *et al.*, 2014). To minimize development of secondary caries, the copings were cemented using a fluoride containing cement (Mattoo, K.A. *et al.*, 2014).

The use of coping in overdenture is a clinical decision and should be taken only when certain requirements are fulfilled. One of the most difficult decision is the selection between the short and long coping which is related to the existing vertical dimensions of the face (Brar, A. *et al.*, 2014). If occlusal dimensions permit the use of long coping without the need for endodontic treatment, then the required occlusal dimensions should be adequate enough to place an artificial tooth over the area of the coping (Mattoo, K.A. *et al.*, 2015) which is rarely the case. Ideally, the vertical dimensions do allow the use of short, coping with endodontic treated teeth as in this case (Mattoo, K.A. *et al.*, 2015). Another important clinical finding that is relevant is the supra eruption of the tooth. If the tooth has supraerupted beyond the occlusal plane of the anticipated denture, the tooth in such cases is reduced in height and it is preferable to give a root retained cast coping since extra coronal coping do not allow placement of artificial tooth over the existing tooth.

CONCLUSION

The use of a short, coping cemented with glass ionomer cement in a diabetic and hypertensive patient has a fair prognosis when an immediate denture is planned. Increase in post-operative follow up appointments is required and an update on medical status should be enquired after one year follow up.

Acknowledgements

The authors would like to acknowledge the staff of the department of periodontics for their valued support

REFERENCES

1. Atkinson, W.H. (1861). Plates over fangs. *Dent Reg*, 15, 213-6.
2. Brar, A., Mattoo, K.A., Singh, Y., Singh, M., Khurana, P.R.S., & Singh, M. (2014). Clinical reliability of different facial measurements in determining vertical dimension of occlusion in dentulous and edentulous subjects. *Int J Prosthodont Restor Dent*, 4, 68-77.
3. Crum, R., & Rooney, G. (1978). Alveolar bone loss in overdentures. *J Prosthet Dent*, 40, 610.
4. Ledger, E. (1856). On preparing the mouth for the reception of a full set of artificial teeth. *Br J Dent Sci*, 1, 90.
5. Mattoo, K., Brar, A., & Jain, P. (2014). A novel approach to manage drug associated xerostomia in geriatric edentulous patients utilizing salivary reservoir in complete denture prosthesis. *European journal of pharmaceutical and medical research*, 1, 41-48.
6. Mattoo, K.A., Kapoor, A., & Sivach, A. (2014). Selecting the right cement for cast post core crowns – a dental students quandary. *Journal of Medical Sciences and Clinical Research*, 2, 2323-2327.
7. Mattoo, K.A., Sivach, A., & Jain, S. (2015). Gnatho dynamic teeth arrangement in complete denture prosthesis. *Journal of Medical Sciences and Clinical Research*, 3, 3875-3878.
8. Mattoo, K.A., Yadav, L., & Rahman, S.U. (2015). Immediate overdenture - a treatment option for bone preservation. *Journal of Medical Sciences and Clinical Research*, 3, 3879-3882.
9. Morrow, R., Powell, J., Jameson, W., Jewson, L., & Rudd, K. (1969). Tooth supported complete dentures: Description and clinical evaluation of a simplified technique. *J Prosthet Dent*, 27, 414.
10. Renner, R.P., & Levy, M. (1977). Preventive prosthodontics- Overdenture service. *NY State Dent J* 43, 17.