

Research Article

Choosing A Non-Aesthetic Region to Test Implant Outcome – A Patient Preference

Humaria Tanvir^{*1}, Vikram Kapoor²

¹Assistant professor, Department of prosthodontics, IDST, CCSU, India

²Professor, Department of prosthodontics, IDST, CCSU, India

Article History

Received: 20.07.2020

Accepted: 15.08.2020

Published: 20.08.2020

Journal homepage:

<https://www.easpublisher.com/easjdom>

Quick Response Code



Abstract: Implant dentistry serves as an excellent treatment option to restore the edentulous areas. People with existing natural dentition often have a hard time psychologically accepting the idea of a removable appliance. Patients' preference for choosing which partial edentulous space has never been explored. We present one unique case that had two Kennedy's partial edentulous situations (one tooth missing) with one in the esthetic zone (maxillary premolar) and the other in a non-esthetic zone (maxillary molar). The patient opted for restoring the mandibular tooth, first as part of his self reliance test for using implant supported restoration. A two stage surgery saw an endosseous (5.3 × 10 mm) implant fixture placed over which porcelain fused to metal restoration was screwed to the abutment. While the patient was happy with the outcome of the mandibular prosthesis, he never turned to restore the maxillary partial edentulous space.

Keywords: Osseointegration, Implant Surgery, Abutment, Screw Retained Implant, Single Tooth Implant.

Copyright © 2020 The Author(s): This is an open-access article distributed under the terms of the Creative Commons Attribution **4.0 International License (CC BY-NC 4.0)** which permits unrestricted use, distribution, and reproduction in any medium for non-commercial use provided the original author and source are credited.

INTRODUCTION

Since the Branemarks introduction of osseointegration between a viable bone and titanium implant in 1965 (Mattoo, K. *et al* 2014), the concepts and techniques in implant dentistry have gone through many evolutionary phases over the years. Its influence is evident from the research conducted on implant dentistry during last three decades of restorative sciences (Minocha, T. *et al.*, 2020). The goal of implant dentistry is not only the tooth replacement, but a functional oral rehabilitation. Considering dental implants as treatment option gives the patient a positive and long term functional prosthesis. Implants have also developed into a sustainable alternative to removable and fixed dental prosthesis (Minocha, T. *et al.*, 2020).

Restoration of molar tooth is of paramount importance as it plays a key role in mastication. Besides its role in maintaining an occlusal plane by preventing supraeruption it also prevents changes in overall occlusion. Studies have also shown that the option of single-implant crown is more cost effective than a 3-unit conventional fixed partial dental prosthesis (Brägger, U. *et al.*, 2005). For a single implant restoration replacing a molar, it is imperative that the occlusion should be planned to curtail the occlusal forces and to capitalize on force distribution to adjacent

natural teeth (De Boever, A. L. *et al.*, 2006; & Kim, S. S. *et al.*, 2013). Ignoring such occlusal changes can even compromise retentive capability of implant supported restorations (Mattoo, K. *et al.*, 2014). This is especially important when the missing molar is to be restored. Single tooth reconstruction with dental implant also provides convenient access for oral hygiene maintenance with relative ease. This case report demonstrates the rehabilitation of missing mandibular molar tooth with a dental implant using a two stage surgical procedure. The feature of the case being the patients preference of choosing a less esthetic area as test for treatment satisfaction before deciding the same treatment option for an esthetic zone.

CASE REPORT

A 43 years old male patient reported to the post graduate wing of the department of prosthodontics. The patient presented with a chief complaint of the missing tooth on left lower back tooth region. He got his tooth extracted due to a failed root canal treatment, 1 year ago. He was wearing a temporary partial denture in the same region since 8 months. His preference of treatment was a fixed prosthesis. Different treatment modalities of fixed prosthesis were explained in detail to the patient. These included a conventional fixed partial denture (3 unit) or an implant supported single

restoration in relation to missing molar. The patient consented for implant supported prosthesis in relation to left mandibular first molar.

Patients medical, social and drug history did not signify to have an impact on dental treatment and/or procedures. Dental history included previous root canal treatment in mandibular left and right second premolars. Extraction of left upper first premolar due to decay 3 years ago, rotation of left upper second premolar and extraction of left lower mandibular first molar 1 year

ago due to failed root canal treatment. The patient was wearing removable partial denture in relation to left lower first molar for 8 months while there was no prosthesis for missing maxillary tooth. No significant adverse habits of the patient came to light. Extra oral findings were within normal variations. Intra oral examination showed a class 2 carious lesion on the maxillary left second premolar while there was attrition on the posterior right side maxillary and mandibular teeth, suggesting a unilateral chewing pattern developed as a loss of other side mandibular molar tooth.

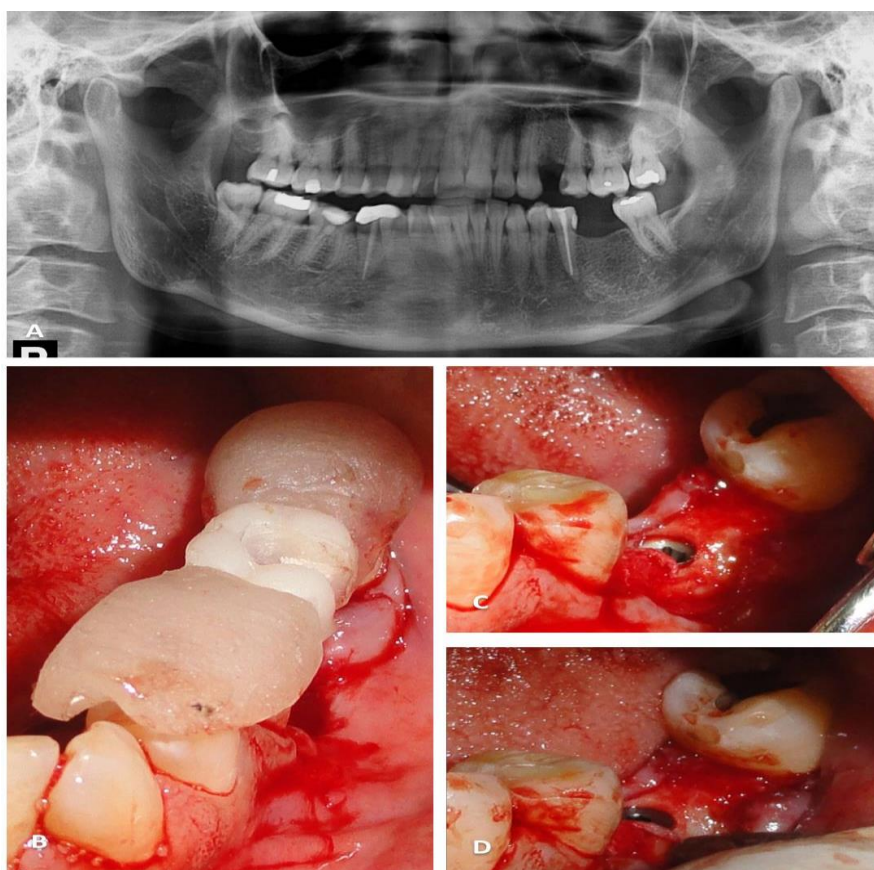


Figure 1: (A) Orthopantomograph shows status of natural dentition (B) Surgical splint (C) and (D) Placement of implant fixture at stage one surgery

The bone type was assessed on a preoperative IOPA, OPG and cone-beam computed tomography (CT) scans. There was adequate width and height of bone to accept a wider dental implant (**Fig 1 A**). Mouth preparation planned for the patient, including an oral hygiene maintenance program for a period of 3 months and restoration of carious tooth. The maxillary premolar was found to have pulpal involvement with symptomatic apical periodontitis thus delaying the maxillary rehabilitation procedure. Following a thorough clinical examination and radiographic imaging, patient was provided with detailed information regarding the planned treatment, alternative treatment options and possible risks. Although the patient was advised to go for implant supported restoration of both missing tooth, the patient wanted to test the outcome in

mandibular arch first before going for the same treatment in the maxillary arch. Prosthetic treatment was initiated by making diagnostic impressions using irreversible hydrocolloid impression material (CA 37; Cavex, Haarlem, Holland), following which diagnostic casts were mounted on a semi adjustable articulator (Whip Mix series 3000; Elite Dental Services, Inc, Orlando, Fla). A two stage implant surgery with an endo osseous implant (Alpha Bio ICE 5.3 × 10 mm implant, Alpha Bio Tec.) was planned. Written informed consent was obtained from the patient. A diagnostic, surgical splint was fabricated of clear acrylic auto polymerizing resin (Fortex; Lucite Intl, Durham) (**Fig 1 B**) and checked for proper fit intraorally. The patient was given preoperative antibiotic therapy. Surgery was performed under local anesthetic with

implant fixture placement facilitated by a surgical splint (**Fig 1C**). A series of drills were used to prepare the osteotomy site precisely and in increments, collaborating the drilling direction with a paralleling pin. The dental implant (Alpha Bio ICE 5.3 × 10 mm implant, Alpha Bio Tec.) was inserted with a surgical motor at a torque value of 25 Ncm and then continued

manually to complete the implant placement (**Fig 1C, D**). Adequate primary stability was obtained with the surrounding the cortical bone present occlusally. After debriding the surrounding area, a cover screw was placed onto the implant and the surgical site was sutured. Post-operative instructions were given and medications (antibiotic and analgesic) were prescribed.

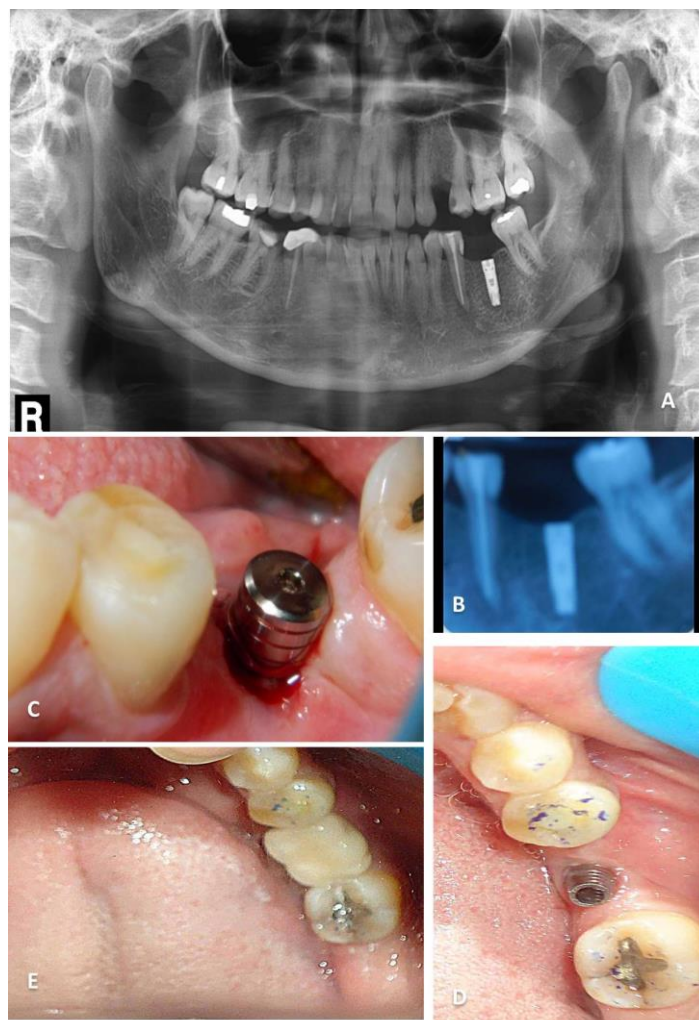


Figure 2: (A) Post surgery orthopantomograph showing osseointegration of implant fixture (B) Intra oral periapical view of integrated implant (C) Placement of healing abutment (D) Screw retained abutment in place (E) Final restoration of porcelain fused to metal screwed to the implant fixture with occlusal opening closed by composite.

After 4 months of healing, second stage surgery was initiated after confirming osseointegration through a series of radiographs including a pantomograph and periapical view (**Fig 2 A, B**). An incision was given to allow exposing the cover screw. A healing abutment was placed on the implant and the area was closed (**Fig 2C**). The patient was recalled after 2 weeks for evaluating the gingival architecture. A well formed gingival emergence profile was appreciated on removal of healing abutment. An impression was made with polyether impression material (Impregum Penta; 3M ESPE) using the closed tray impression technique with the help of impression coping and implant analog. Final abutment (Alpha Bio, Alpha Bio Tec.) was then

selected according to the height of the soft tissue (**Fig 2D**) and temporization was done. Porcelain fused to metal screw retained complete crown was fabricated in which an implant protected occlusion was incorporated. The crown was screwed on the abutment and the hole of the crown was filled with flowable composite for esthetic purposes (**Fig 2 E**). The patient was instructed about the oral hygiene maintenance. Bone levels around implant were stable at 6 months and 12 month follow-up.

DISCUSSION

A case of implant supported single crown restoration in the region of left mandibular missing

molar using a screw retained abutment has been described in this case report. The main feature that the authors want to highlight is the patients choice for using a non esthetic zone (in this case mandibular molar) as a test for patient satisfaction before getting the same treatment done in a more esthetically zone (in this case a maxillary premolar). While studies have shown that doctors tend to have a poor understanding of their patients' preferences (Lenert, L. A. *et al.*, 1998), especially in decision making, it is a matter of studying such preferences in dentistry.

Branemark's accidental finds of osseointegration is a boon and has completely changed dental rehabilitation. The use of endosseous dental implants is a probable treatment modality with proven safety and survival rates (Rangert, B. R *et al.*, 1997). To attain expectable osseointegration for dental implants, Branemark advocated an unloaded healing time of 3-6 months (Taylor, R. C. *et al.*, 2004). Till date, this transpires to be the most satisfactory and the most commonly followed treatment protocols (Misch, C. 1999). The aim of bringing occlusal forces on the implant prosthesis gradually allows a better bone remodelling and organize in accordance with Wolff's law (Corso, M. *et al.*, 1999; & Branemark, P. I. 1977). On allowing healing for a period of 3-8 months, depending on bone densities, a clinical study determined the overall implant survival rate to be 98% that is, 100% of D₁ bone, 98.9% for D₂ bones, 99% for D₃ and 100% for D₄ (Cavallaro Jr, J. S. 2011; & Misch, C. E. *et al.*, 1998).

A clinician's skill in manipulating the soft tissues around the healing abutment of the implant and judicious use of temporary restoration results in enhanced aesthetics. The same principle has been used in this case to create soft tissue contour around the surface of the abutment that would aid in maintaining oral hygiene (Rathi, N. *et al.*, 2019). In most of the cases rehabilitated by implants, especially in the anterior maxillary zone, the overall skill of the multidisciplinary team who plan the prosthesis are tested (Rathi, J. N. *et al.*, 2019).

CONCLUSION

With the improvements in implant materials, design, surgical approach, and prosthetic guidelines, the use of implants to replace a single tooth is often the treatment of choice. Unique surgical and prosthetic concepts are implemented for proper results. This case report demonstrates that it is possible to achieve greater efficiency in our efforts to give patient sound, timely and economical treatment. Continued innovations in the prosthetic capabilities of implant system will enhance the service and treatment offered to the patients in regard to comfort, cost and esthetics.

Acknowledgement

The authors would like to acknowledge the efforts of the staff of the department of periodontology, restorative dentistry and oral surgery for their valued contribution towards completing this case.

REFERENCES

1. Brägger, U., Krenander, P., & Lang, N. P. (2005). Economic aspects of single-tooth replacement. *Clinical Oral Implants Research*, 16(3), 335-341.
2. Branemark, P. I. (1977). Osseointegrated implants in the treatment of the edentulous jaw. Experience from a 10-year period. *Scand. J. Plast. Reconstr. Surg. Suppl.*, 16.
3. Cavallaro Jr, J. S. (2011). Implant survival and radiographic analysis of proximal bone levels surrounding a contemporary dental implant. *Implant dentistry*, 20(2), 146-156.
4. Corso, M., Sirota, C., Fiorellini, J., Rasool, F., Szmukler-Moncler, S., & Weber, H. P. (1999). Clinical and radiographic evaluation of early loaded free-standing dental implants with various coatings in beagle dogs. *The Journal of prosthetic dentistry*, 82(4), 428-435.
5. De Boever, A. L., Keersmaekers, K., Vanmaele, G., Kerschbaum, T., Theuniers, G., & De Boever, J. A. (2006). Prosthetic complications in fixed endosseous implant-borne reconstructions after an observations period of at least 40 months. *Journal of oral rehabilitation*, 33(11), 833-839.
6. Kim, S. S., Yeo, I. S., Lee, S. J., Kim, D. J., Jang, B. M., Kim, S. H., & Han, J. S. (2013). Clinical use of alumina-toughened zirconia abutments for implant-supported restoration: prospective cohort study of survival analysis. *Clinical oral implants research*, 24(5), 517-522.
7. Lenert, L. A., Cher, D. J., Goldstein, M. K., Bergen, M. R., & Garber, A. (1998). The effect of search procedures on utility elicitation. *Medical Decision Making*, 18(1), 76-83.
8. Mattoo, K., Singh, S. P., & Brar, A. (2014). A simple technique to align attachment components in implant supported mandibular overdenture. *International Journal Of Research In Medical Sciences And Technology*, 1(1), 6-8.
9. Mattoo, K., Garg, R., & Bansal, V. (2014). Designing the occlusion for a single tooth implant in a compromised occlusion. *Journal of Medical Sciences and Clinical Research*, 2(11), 2996-3000.
10. Minocha, T., Mattoo, K., & Rathi, N. (2020). An 2/2 Implant Overdenture. *Journal of Clinical Research in Dentistry*, 3(1), 1-2.
11. Misch, C. (1999). Available bone and dental treatment plans. In: Misch CE, editor. *Contemporary Implant Dentistry*. St. Louis: Mosby. p.178-99.
12. Misch, C. E., Hoar, J., Beck, G., Hazen, R., & Misch, C. M. (1998). A bone quality-based implant

- system: a preliminary report of stage I & stage II. *Implant dentistry*, 7(1), 35-42.
13. Rangert, B. R., Sullivan, R. M., & Jemt, T. M. (1997). Load factor control for implants in the posterior partially edentulous segment. *International Journal of Oral & Maxillofacial Implants*, 12(3), 360-370.
 14. Rathi, J. N., Goswami, R., & Mattoo, K. A. (2019). Implant Supported Mandibular Overdenture-Case Report. *Journal of Advanced Medical and Dental Sciences Research*, 7(11), 128-130.
 15. Rathi, N., Jain, K., & Mattoo, K.A. (2019). Placing an implant fixture during ongoing orthodontic treatment. *SSRG International Journal of Medical Science* 6 (11), 19-21.
 16. Taylor, R. C., McGlumphy, E. A., Tatakis, D. N., & Beck, F. M. (2004). Radiographic and Clinical Evaluation of Single-Tooth BioloK Implants: A 5-year Study. *International Journal of Oral & Maxillofacial Implants*, 19(6), 849-854.