

## Original Research Article

## Distribution of Malignant Abdominal Tumors in Children at Wahidin Sudirohusodo Hospital in 2014-2017

Emmy Palinggi<sup>1\*</sup> and Farid Nur Mantu<sup>2</sup><sup>1</sup>Department of Surgery, Medical Faculty, Hasanuddin University, Makassar, Indonesia<sup>2</sup>Pediatric Surgery Division, Department of Surgery, Faculty of Medicine, Hasanuddin University, Makassar, Indonesia

\*Corresponding Author

Emmy Palinggi

**Abstract:** This study aims to determine the number of sufferers, disease patterns based on sex, age, radiological features, type of surgery performed, place of treatment, results of postoperative Anatomy Pathology and the condition of post-treatment patients in cases of abdominal tumors in children. This research method is descriptive retrospective. Retrospectives were obtained in Dr. Hospital's medical records Wahidin Sudirohusodo from 2014 to 2017. The results of this study showed that cases of malignant abdominal tumors in children were found 83 cases, the distribution of 44 cases (69.23%) and 39 cases (30.77%) for women, the youngest age was 6 months and the oldest is 16 years, most at the age of 3-6 years. Abdomen ultrasound examination and CT scan Abdomen tumor location of the most nephroblastoma 23 cases (44.23%). Surgery was performed in 38 cases (65.71%), the results of Anatomical Pathology after nephroblastoma surgery were 25 cases (48.07%). The surgical department treated 35 cases (67.30%) and pediatric 17 cases (22.70%). This type of surgery performed 11 cases (47.82%) nephrectomy, 4 cases (17.39%) biopsy laparotomy and 8 cases (34.78%) laparotomy removal of the tumor. The condition of the patient when healed 10 cases (43.47%), forced to go home 7 cases (30.43%) and died 6 cases (26.2%) The average patient with a malignant abdominal tumor in children came with an advanced stage. Not a good recording and monitoring system causes the final results can not be well known.

**Keywords:** Malignant abdominal tumor in children, nephroblastoma, neuroblastoma.

### INTRODUCTION

Malignant abdominal tumors in children are the growth of malignant tumor cells that occur in the abdominal cavity. Malignancy or cancer is the second most leading cause of death in children after trauma (Murphy & Holcomb, 2010; Brunicardi *et al.*, 2014). Malignant abdominal tumors in children constitute about 2% of all cancer in humans. Abdominal malignant tumors constitute one-third of all malignant tumors in children. The prevalence of malignant abdominal tumors in children consists of neuroblastoma, Wilms tumor (nephroblastoma), teratoma, ovarian tumor, abdominal lymphoma, hepatoma and others (Chu *et al.*, 2011; Armstrong *et al.*, 2014).

Common symptoms caused by cancer are lethargy, weakness, weight loss dramatically, excessive sweating, fever, pale and pain in the stomach, need to get close attention even though such symptoms can also

be found in various chronic infectious diseases that are still many found in Indonesia (Murphy & Holcomb, 2010; Williams *et al.*, 2013).

Tumors in the abdominal cavity are realized by the parents and the patient himself when the child's abdomen appears to be enlarged, felt solid hard mass or when the child is bathed. If a tumor is found in the abdomen, physical examination is done carefully and gently to avoid excessive trauma that can facilitate the occurrence of tumor rupture or metastasis. The tumor mass then needs to be identified precisely the location and origin of the tumor, intraperitoneal or retroperitoneal. But in large tumor masses it is difficult to determine the exact location of the tumor. Similarly, if the tumor originates from the pelvic cavity and has been pressed into the abdominal cavity (Murphy & Holcomb, 2010; Brunicardi *et al.*, 2014).

Quick Response Code



Journal homepage:

<http://www.easpublisher.com/easims/>

Article History

Received: 25.11.2019

Accepted: 06.12.2019

Published: 18.12.2019

Copyright © 2019: This is an open-access article distributed under the terms of the Creative Commons Attribution license which permits unrestricted use, distribution, and reproduction in any medium for non commercial use (NonCommercial, or CC-BY-NC) provided the original author and source are credited.

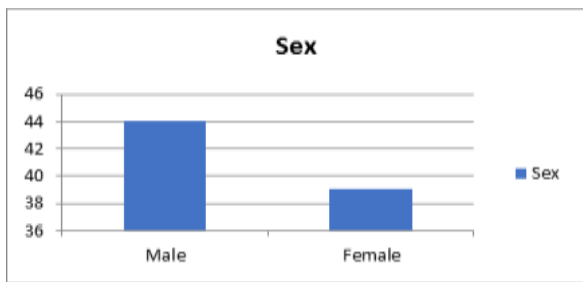
This study aims to determine the number of sufferers, disease patterns based on sex, age, radiological features, type of surgery performed, place of care, results of postoperative Anatomical Pathology and the condition of post-treatment patients in cases of abdominal tumors in children.

**METHODOLOGY**

This research is a descriptive retrospective. Secondary data were obtained from the medical record at Wahidin Sudirohusodo Hospital in the Division of Pediatric Surgery for the period 2014-2017 with ICD code C76.2. The study was conducted in the medical record section of Wahidin Sudirohusodo Hospital in Makassar in June-July 2018.

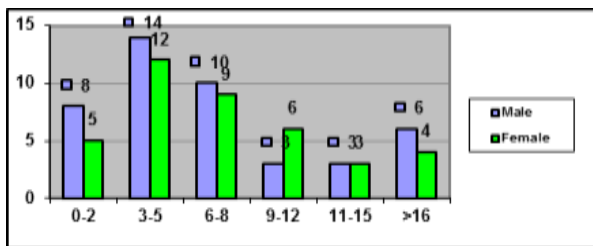
**RESULTS**

From this descriptive retrospective study, we found that in the period of January 2014 to 2017 at Wahidin Sudiro Husodo General Hospital Makassar, 83 cases of abdominal malignant tumors in children were found. Of the 83 cases, 44 cases were men (53.01%) and 39 cases were women (46.98%).



**Graph 1. Distribution of cases of malignant abdominal tumors in children by sex in Makassar Hospital between 2014 and 2017**

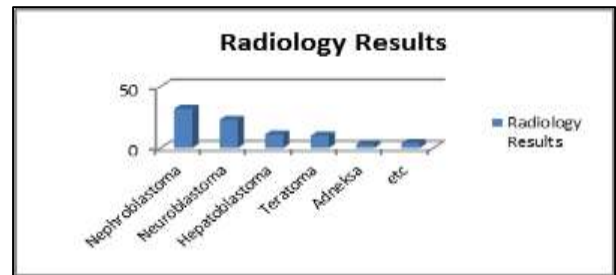
Based on age groups, varied with 0-2 years 13 cases (15.6%), most between 3-5 years, 26 cases (31.2%), ages 6-8 years 19 cases (22.89%). The youngest age is 6 months and the oldest is 16 years.



**Graph 2. Distribution of cases of malignant abdominal tumors of children by age group in RSWs for the period 2014 to 2017**

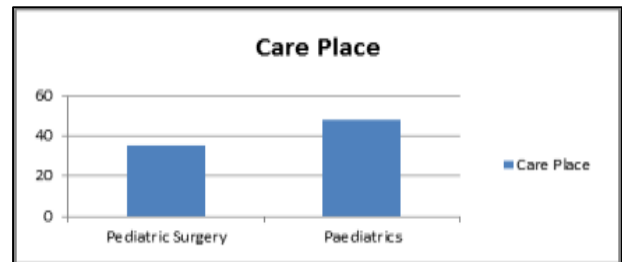
Of the 83 cases of abdominal malignant tumors that were examined by USG Abdomen and CT Scan Abdomen tumor types with the most nephroblastoma 32 cases (38.55%) then neuroblastoma 23 cases (27.71%), hepatoblastoma 11 cases (13.25%), teratoma 10 cases (12.04%), adnexal tumor 3 cases

(3.61%), testicular seminoma, gastric tumor, rectosigmoid tumor, mesentery tumor 1 case each.



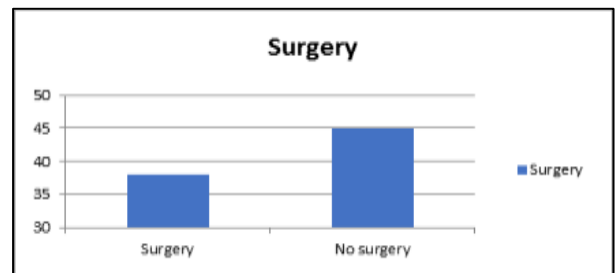
**Graph 3. Distribution of types of abdominal malignant tumors in children based on ultrasound examination of the Abdomen and CT Scan of the Abdomen in children in the RSWs for the period 2014 to 2017**

Of the 83 cases of abdominal malignant tumors in children, 35 cases (42.16%) were treated in pediatric surgery and 48 cases (57.8%) were treated in pædiatrics.



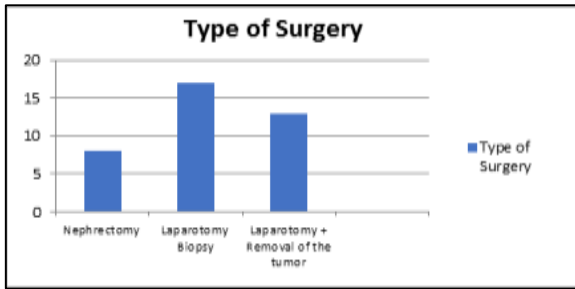
**Graph 4. Distribution of types of malignant abdominal tumors in children treated in RSWs for the period 2014 to 2017**

Of 83 cases of abdominal malignant tumors in children who underwent surgery as many as 38 (45.7%) cases and non-surgery as many as 45 cases (54.21%). In 45 cases that were not performed due to the average patient's parents refused surgery and the average patient went home not yet recovered or forced to go home, and some patients died with complications before they could have surgery.



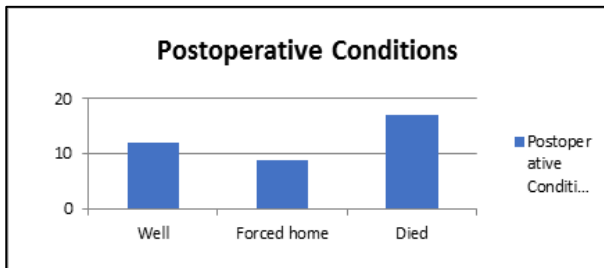
**Graph 5. Distribution of cases of malignant abdominal tumors in children undergoing surgery at the RSWs for the period 2014 to 2017**

From 38 cases of abdominal malignant tumors in children who performed nephrectomy in 8 cases (21.5 %%), laparotomy biopsy in 17 cases (44.7%), laparotomy for tumor removal in 13.cases (33.76%).



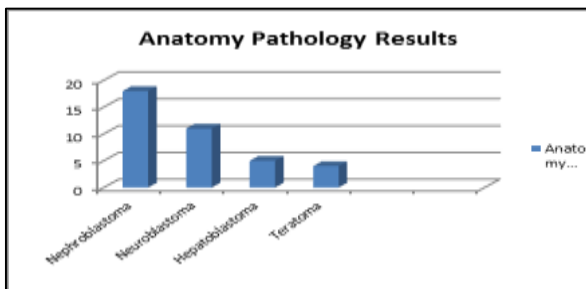
**Graph 6. Distribution of cases of malignant abdominal tumors in children based on the type of surgery performed at RSWS for the period 2014 to 2017**

Of the 38 cases that were operated on, patients were discharged from the hospital in good condition 12 cases (31.57%), not yet healed or forced to go home 9 cases (23.68%) and died 17 cases (44.73%).



**Graph 7. Distribution of cases of malignant abdominal tumors in children based on the type of surgery performed at RSWS for the period 2014 to 2017**

From 38 operated cases, PA results showed nephroblastoma 18 cases (47.3%), neuroblastoma 11 cases (28.9%) and hepatoblastoma 5 cases (13.1%) and teratoma 4 cases (10.52%).



**Graph 8. Anatomical Pathology Results performed in cases of abdominal tumors in children in RSWS for the period 2014 to 2017**

## DISCUSSION

In this study the results obtained evaluating cases of abdominal malignant tumors in children retrospectively from Dr. Hospital. Wahidin Sudirohusodo from 2014 to 2017 found 83 cases of malignant abdominal tumors in children, male genital distribution more than women, 44 cases in men (69.23%) and women in 39 cases (30.77%). The number of men compared to women is not too

significantly different, according to the literature that the distribution of tumor patients is more in boys (Malkan *et al.*, 2014; Magro, *et al.*, 2015).

The youngest is 6 months and the oldest is 16 years, with the highest frequency at 3-6 years. The average age of patients recorded is 5-6 years, this is in accordance with the literature in which the age of most patients with solid tumors at ank is 5 years (Malkan *et al.*, 2014; Magro, *et al.*, 2015).

Cases of abdominal malignant tumors in children who underwent USG Abdomen and CT Scan The abdomen obtained the most tumor locations were nephroblastoma 23 cases (44.23%), followed by neuroblastoma, hepatoma and teratoma. There are patients who are only on ultrasound and there are also patients who are on CT scans. This radiological examination is the standard that was used to diagnose solid tumors located in the abdominal cavity. The examination is not invasive, and has a pretty good sensitivity, and the minimum radiation is ultrasound. CT scan can assess the structure around the tumor, including staging of the malignant tumor found. Existing literature provides standards for examining solid tumors, with ultrasound and CT scans have been able to identify solid tumors, of course if there are more sophisticated examinations such as MRI and PET Scan, it can also be done (Malkan *et al.*, 2014; Magro, *et al.*, 2015).

Pathology Results Anatomy of malignant abdominal tumors in children who obtained the most postoperative nephroblastoma with 25 cases (48.07%). Nephroblastomas or Wilms tumors in various literature have the greatest number of cases among other solid abdominal tumors (Haupt *et al.*, 2010; Kelleher & Goldstein, 2015).

Cases of abdominal malignant tumors in children treated in the surgical department were 35 cases (67.30%) and in the pediatric section 17 cases (22.70%). Insignificant complaints that only the stomach is burning, making many abdominal tumor patients delivered by their parents to pediatrics, not to pediatric surgery, so that many patients are not detected, or not even get surgery because of fear of the patient's family for surgery. Concomitant diseases in tumor patients also make many patients treated by pediatrics. accompanying diseases that can occur in the form of bronchopneumonia, sepsis and anemia (Malkan *et al.*, 2014; Magro, *et al.*, 2015).

There were 38 cases (65.71%) performed surgery, the patient was not operated for because it has complications of the disease that are difficult to handle, so it is not possible to do the operation, given the patient's weak condition. Parents are also a determining factor in patients not undergoing surgery, many parents who do not agree to do surgery on their children.

Surgery performed 11 cases (47.82%) nephrectomy, 4 cases (17.39%) biopsy laparotomy and 8 cases (34.78%) laparotomy removal of the tumor. Nephrectomy in Wilms Tumor patients is still the first choice for Wilms Tumor management.

Patients discharged from the hospital recovered 10 cases (43.47%), had not recovered or were forced to go home 7 cases (30.43%) and died in 6 cases (26.2%). Not a good system of recording and monitoring of patients who have been discharged from the hospital causes the final results can not be well known.

## CONCLUSION

The average patient with a malignant abdominal tumor in children presents with an advanced stage. The most documented cases of malignant abdominal tumors are nephroblastoma, neuroblastoma, hepatoma, teratoma. Not a good system of recording and monitoring of patients who have been discharged from the hospital causes the final results can not be well known.

## REFERENCES

1. Armstrong, G. T., Kawashima, T., Leisenring, W., Stratton, K., Stovall, M., Hudson, M. M., & Oeffinger, K. C. (2014). Aging and risk of severe, disabling, life-threatening, and fatal events in the childhood cancer survivor study. *Journal of clinical oncology*, 32(12), 1218.
2. Brunnicardi, F., Andersen, D., Billiar, T., Dunn, D., Hunter, J., Matthews, J., & Pollock, R. (2014). *Schwartz's principles of surgery*, 10e. McGraw-hill.
3. Chu, C. M., Rasalkar, D. D., Hu, Y. J., Cheng, F. W. T., Li, C. K., & Chu, W. C. W. (2011). Clinical presentations and imaging findings of neuroblastoma beyond abdominal mass and a review of imaging algorithm. *The British journal of radiology*, 84(997), 81-91.
4. Haupt, R., Garaventa, A., Gambini, C., Parodi, S., Cangemi, G., Casale, F., ... & Luksch, R. (2010). Improved survival of children with neuroblastoma between 1979 and 2005: a report of the Italian Neuroblastoma Registry. *Journal of Clinical Oncology*, 28(14), 2331-2338.
5. Kelleher, C. M., & Goldstein, A. M. (2015). Adnexal masses in children and adolescents. *Clinical obstetrics and gynecology*, 58(1), 76-92.
6. Magro, G., Longo, F. R., Angelico, G., Spadola, S., Amore, F. F., & Salvatorelli, L. (2015). Immunohistochemistry as potential diagnostic pitfall in the most common solid tumors of children and adolescents. *Acta histochemica*, 117(4-5), 397-414.
7. Malkan, A. D., Loh, A. H., & Sandoval, J. A. (2014). Minimally invasive surgery in the management of abdominal tumors in children. *Journal of pediatric surgery*, 49(7), 1171-1176.
8. Murphy, J. P., & Holcomb III, G. W. (2010). *Ashcraft's pediatric surgery*. Saunders.
9. Williams, N. S., Bulstrode, C. J., & Connell, P. R. (2013). *Bailey & Love's short practice of surgery*.