

Case Report

Transient Biventricular Dysfunction Following Pericardiocentesis for Cardiac Tamponade

M.A. Amil^{1*}, M Akrim¹, and S. El. Karimi¹¹Service de cardiologie, CHU Mohammed VI, Marrakech, Morocco**Article History**

Received: 18.02.2020

Accepted: 20.03.2020

Published: 25.03.2020

Journal homepage:<https://www.easpublisher.com/easjms>**Quick Response Code**

Abstract: We report a case of transient biventricular dysfunction post pericardiocentesis. Biventricular dysfunction post pericardiocentesis more prevalent than previous. In addition to judicious and gradual decompression to avoid ventricular dysfunction, patients undergoing therapeutic pericardiocentesis should have careful hemodynamic monitoring, as changes in parameters such as heart rate and respiratory rate can raise suspicion of acute ventricular impairment.

Keywords: pericardiocentesis, biventricular dysfunction, pericardial effusion.

Copyright © 2020: This is an open-access article distributed under the terms of the Creative Commons Attribution license which permits unrestricted use, distribution, and reproduction in any medium for non commercial use (NonCommercial, or CC-BY-NC) provided the original author and source are credited.

INTRODUCTION

We report a case of transient biventricular dysfunction post therapeutic pericardiocentesis. Our case is instructive in challenging our understanding of the aetiology of ventricular dysfunction complicating pericardiocentesis, and in highlighting the importance of careful clinical evaluation (altered heart rate and dyspnoea) in suspecting acute ventricular dysfunction after initial clinical improvement with pericardial aspiration.

CASE REPORT

A 38 years-old woman, with no past significant cardiovascular history. She has a history of metastatic breast cancer, who underwent mastectomy for Invasive Ductal Carcinoma SBR II triple negative, 6 months and with no cardiovascular history, presented to the emergency department with progressively worsening dyspnea over the previous 2 weeks with lower chest discomfort. Her physical examination was noticeable for jugular venous distension, hypotension (blood pressure of 80/50 mmHg), tachycardia (heart rate of 172 beats/min), and muffled heart sounds.

Her ECG showed sinus tachycardia with electrical alternance and diffuse low complex QRS voltage.

The echocardiogram showed very little pericardial effusion without hemodynamic compromise, but revealed systolic dysfunction of both ventricles (LVEF 27%).

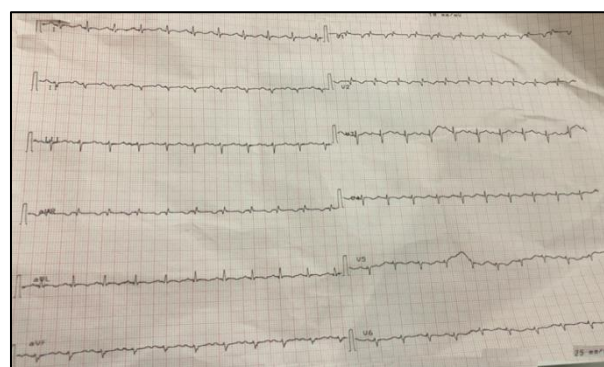


Fig.1 : ECG : electrical alternance and diffuse low complex QRS voltage.

The chest X-ray revealed an enlarged cardiac silhouette with a right pleural effusion.

A transthoracic echocardiogram revealed a large pericardial effusion (53 mm in the posterior wall, 31mm in the anterior wall) with swinging heart and hemodynamic signs of cardiac tamponade. Global and

regional contractility were preserved and left ventricle ejection fraction (LVEF) was preserved.

An emergent pericardiocentesis was performed and 1,500 ml of serosanguinous fluid was removed.

The pericardial draining catheter was left in place for one day. The pericardial fluid was exudative. Cytologic examination of the pericardial fluid revealed malignant cells. A postpericardiocentesis TTE showed no residual pericardial effusion with LV systolic dysfunction.

Her postpericardiocentesis ECG showed normal sinus rhythm without electrical alternans. Six hours after removal of the pericardial fluid the patient became increasingly breathless with sinus tachycardia, without chest pain.

The echocardiogram showed very little pericardial effusion without hemodynamic compromise, but revealed systolic dysfunction of both ventricles (LVEF 27%).

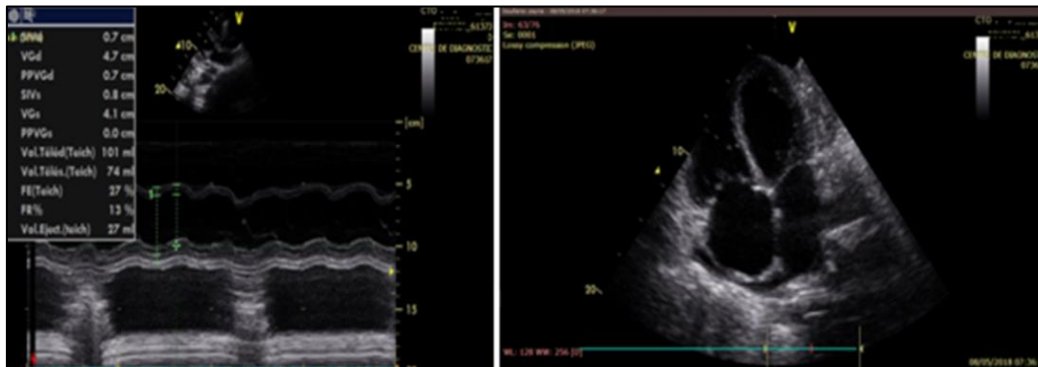


Fig.2: Parasternal long-axis view, M mode (A) and apical 4-chamber view (B) : demonstrating severely depressed biventricular dysfunction postpericardiocentesis.

There was no evidence of myocardial perforation. ECG showed a sinus tachycardia with diffuse low QRS voltage, negative T waves in anterior leads. Troponin was normal. Repeat renal panel did not show any renal impairment. Repeat liver panel showed improvement of Cytolysis.

Immediate i.v therapy with dobutamine and furosemide 40mg per day were initiated with a steady

clinical improvement. Eleven days after admission the patient was recovering well in the cardiology ward and expressed a subjective perception of good health. A control echocardiogram showed a dramatic improvement of the contractility of both ventricles. Both ventricles had returned to a normal size and LVEF was 57%. Analgesics were only prescribed drugs, and the oncology team was ready to initiate chemotherapy for the breast cancer.

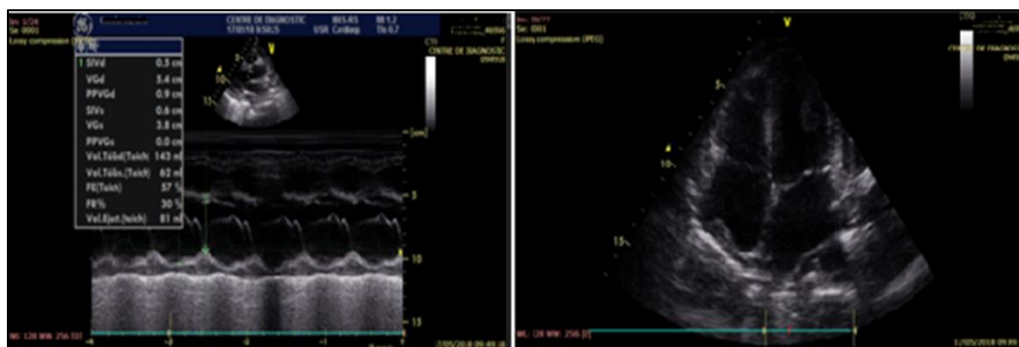


Fig.3: An apical four chamber view post pericardiocentesis showing resolution of normal LV systolic function.

DISCUSSION

Our patient developed biventricular dysfunction following successful pericardiocentesis. In light of the timing of onset of biventricular impairment immediately post procedure pericardial decompression syndrome is an important differential diagnosis. Other differentials such as laceration to the ventricle or left anterior descending (LAD) coronary artery were clinically unlikely. The former was excluded by the

absence of new pericardial bleed post procedure. Laceration of the LAD was also clinically unlikely given relatively small rise in cardiac enzymes and absence of large infarct, the presence of concurrent RV dysfunction, spontaneous recovery of ventricular function in a short period of time. Accordingly, we reviewed the literature describing pericardial decompression syndrome. The incidence of pericardial decompression syndrome (PDS) or new left or right systolic dysfunction has been reported to range from 5

% to 36 % of patients post pericardiocentesis (Dosios, T. *et al.*, 2003; Wagner, P. L. *et al.*, 2011), especially after malignant pericardial effusions. Although the first case report of PDS in 1983 noted APO with preserved LV function (Vandyke Jr, W. H. *et al.*, 1983), most subsequent reports describe severe impairment of left, right or biventricular function, which may be segmental or global. A number of mechanisms have been proposed to explain the pathogenesis of LV systolic dysfunction in PDS. Acute withdrawal of exaggerated sympathetic drive during relief of tamponade may trigger paradoxical haemodynamic instability (Vandyke Jr, W. H. *et al.*, 1983). Mechanical, inter-ventricular volume mismatch may also contribute, with sudden relief of pericardial constraint leading to abrupt, disproportionate increase in RV volume and a paradoxical rise in pulmonary artery pressure, resulting in raised LV end diastolic pressure and transient left heart failure (Vandyke Jr, W. H. *et al.*, 1983). Others have proposed myocardial stunning from coronary perfusion mismatch with acute distension of cardiac chambers after decompression (Vandyke Jr, W. H. *et al.*, 1983). Taken together, it is likely that a combination of hormonal and mechanical pathophysiologic mechanisms contribute to LV dysfunction and the final clinical sequelae in PDS. Current literature has not specifically addressed risk factors for the development of ventricular dysfunction after pericardiocentesis. In our patient, the malignant nature of the effusion, the presence of tamponade and larger size of pericardial effusion (Wagner, P. L. *et al.*, 2011), may have increased his predisposition to develop ventricular dysfunction. Amount and rate of fluid removed on initial decompression are also associated with development PDS (Wagner, P. L. *et al.*, 2011; Vandyke Jr, W. H. *et al.*, 1983), however there are no guidelines regarding the maximum amount of pericardial fluid that can be drained immediately

CONCLUSION

We report a case of transient biventricular dysfunction post pericardiocentesis. Biventricular dysfunction post pericardiocentesis more prevalent than previous. In addition to judicious and gradual decompression to avoid ventricular dysfunction, patients undergoing therapeutic pericardiocentesis should have careful haemodynamic monitoring, as changes in parameters such as heart rate and respiratory rate can raise suspicion of acute ventricular impairment.

BIBLIOGRAPHIE

1. Dosios, T., Theakos, N., Angouras, D., & Asimacopoulos, P. (2003). Risk factors affecting the survival of patients with pericardial effusion submitted to subxiphoid pericardiostomy. *Chest*, 124(1), 242-246.
2. Vandyke Jr, W. H., Cure, J., Chakko, C. S., & Gheorghide, M. (1983). Pulmonary edema after pericardiocentesis for cardiac tamponade. *New England Journal of Medicine*, 309(10), 595-596.
3. Wagner, P. L., McAleer, E., Stillwell, E., Bott, M., Rusch, V. W., Schaffer, W., & Huang, J. (2011). Pericardial effusions in the cancer population: prognostic factors after pericardial window and the impact of paradoxical hemodynamic instability. *The Journal of thoracic and cardiovascular surgery*, 141(1), 34-38.