

Research Article

Effect of Zinc on Spermatogenesis

Mohammad Sair^{1*}, Sana Imran², mohammad Nauman Shad³ and mohammad azeem⁴Tufail Soomro⁵¹Assistant professor Department of pharmacology Margalla institute of health sciences Rawalpindi, Pakistan²Assistant Professor Department of pharmacology and therapeutics Jinnah Sindh Medical University, Pakistan³Associate professor Sahara Medical College Narowali, Pakistan⁴Associate professor islam medical college Sialkot, Pakistan⁵Assistant Professor Indus medical college Tando muhammad khan

*Corresponding Author

Mohammad Sair

Abstract: Objective: To study the effect of zinc on spermatogenesis in albino rats. **Method:** This study was conducted in the Department of Pharmacology BMSI, JPMC Karachi. four groups of albino rats were made 15 rats in each group. Group one was control group given normal diet only, group two was given indomethacin, group three was given zinc and group four was given combination of Zinc and indomethacin. Drugs were given for 12 weeks. At the end of study histopathology of testes was performed to see spermatogenesis. Data was analyzed statistically. **Results:** In group 2 focal loss of normal distribution of germ cells series was seen with focal detachment of basement membrane. In group 4 normal series of spermatogenesis seen **Conclusion:** Zinc has a protective role on testes.

Keywords: Zinc, spermatogenesis, Indomethacin, Sertoli cells, seminiferous tubules, germinal epithelium.

INTRODUCTION

Zinc is important anti-oxidant. Zinc is in the form of zinc oxide, zinc acetate, and zinc gluconate (DiSilvestro, R. A. 2004). It is a constituent of an important enzyme superoxide dismutase, which protects cells from damage caused by free radicals. Zinc reduce oxidative stress in developing sperm (Onyenmechi *et al.*, 2002). Zinc is present in rich quantity in semen (Berdanier, C.D., Dwyer, J. 2007). It is important factor sperm formation (Falana, B. A., & Oyeyipo, I. P. 2012). Zinc plays an important role in spermatogenesis and sperm motility (Madding, C. I. *et al.*, 1986). Administration of zinc causes induction of metallothionein which have antioxidant effects (Powell 2000). Indomethacin is a nonselective inhibitor of cyclooxygenase (COX) 1 and 2. Toxic effects of indomethacin on spermatogenesis are oligospermia and azoospermia (Dissanayake, D. M. A. B. *et al.*, 2009).

MATERIALS AND METHODS

This study was conducted in the Department of Pharmacology and Therapeutics BMSI, JPMC Karachi from 30 June 2013 to 30 December 2013.

Animals:

Sixty male albino rats weighing 200 to 300 grams were taken from animal house BMSI/JPMC.

Drugs:

Zinc in the syrup form available as 20 mg /5ml given orally for 12 weeks. Indomethacin with a dose of 10mg /kg given for 12 weeks.

GROUPING OF THE ANIMALS:

The Selected Sixty Albino Male Rats Were Divided Into Four Equal Groups, 15 Animals In Each Group.

Group I (control group): The 15 albino rates of this group were kept on normal diet.

Group II (Indomethacin group): In this group 15 Albino rats were treated with indomethacin.

Group III (Zinc group): The 15 albino rats in this group were given zinc.

Group IV (Combination group): Combination of zinc and indomethacin in their respective dose given for 12 weeks.

Quick Response Code



Journal homepage:

<http://www.easpublisher.com/easjpp/>

Article History

Received: 29.10.2019

Accepted: 08.11.2019

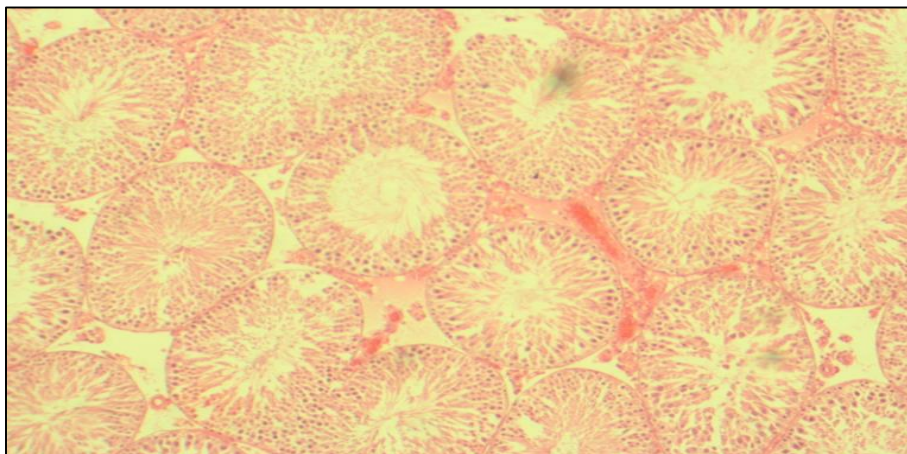
Published: 28.11.2019

Copyright © 2019: This is an open-access article distributed under the terms of the Creative Commons Attribution license which permits unrestricted use, distribution, and reproduction in any medium for non commercial use (NonCommercial, or CC-BY-NC) provided the original author and source are credited.

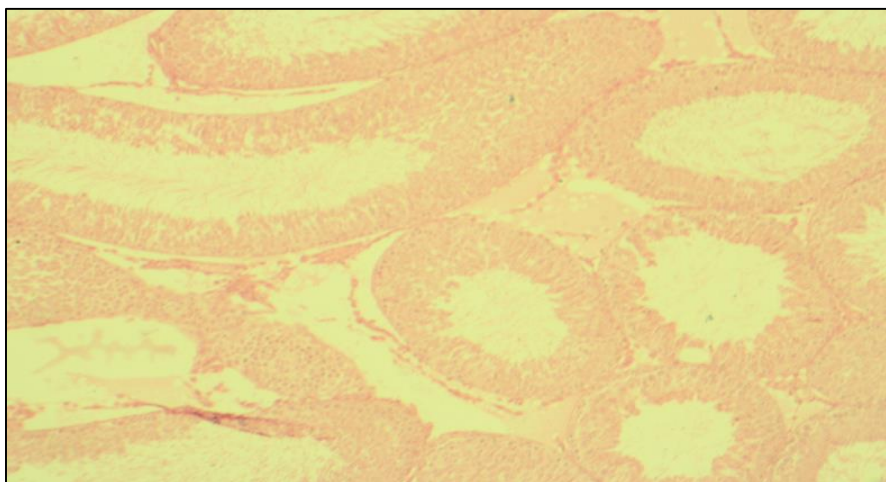
Before to start of research animal were kept on room temperature for one week for acclimatization. Medication was given to each rat for three months. Animals were observed daily for their physical activity and weighed weekly. At end of study period rats were scarified. A mid line incision was made up to scrotum.

Testes were excised and kept in bouin,s fluid for 48 hours. Tissue was prepared. H and E staining was performed. Histopathological examination was performed.

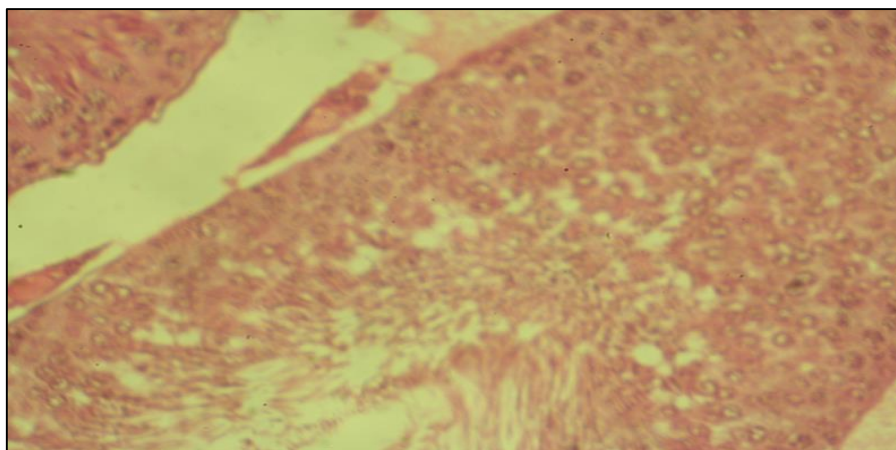
RESULTS



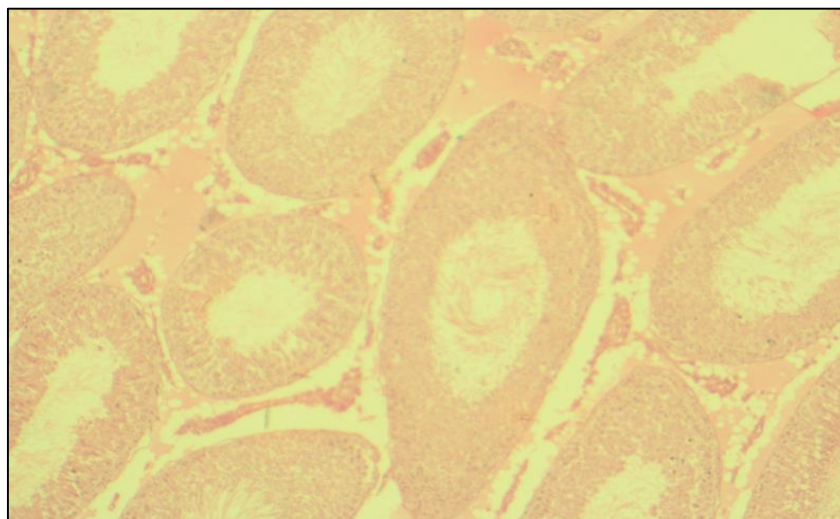
Photomicrograph 1: Control group 10x H and E photomicrograph testicular tissue showing normal spermatogenesis



Photomicrograph :Indomethacin Group 10 x H and E Photomicrograph testicular tissue showing suppressed spermatogenesis.



Photomicrograph :Zinc Group 40x H and E photomicrograph testicular tissue showing normal spermatogenesis



Photomicrograph:Combination Group 10x H and E photomicrograph testicular tissue showing normal spermatogenesis

Histopathological Finding

Albino rats of control group showed normal series of spermatogenesis with intact basement membrane. Sertoli cells and leydig cells were seen. Multiple layers of germinal epithelium were seen.

Albino rats given Indomethacin for 90 days revealed overall decrease in spermatogenic series with focal detachment of basement membrane when compared to control. Focal loss of normal distribution of germ cells series were present. Leydig cells were less in number as compared with control.

Albino rats given zinc for 90 days revealed increase in spermatogenesis when it was compared to control. Large number of seminiferous tubules were present. Basement membrane were intact. Multiple layer of germinal epithelium were seen with normal looking leydig cell.

Albino rats given combination of zinc and Indomethacin for 90 days revealed slight increase in spermatogenesis, and mostly intact basement membrane. Organized spermatogenic cells series observed.

DISCUSSION

Zinc is essential for spermatogenesis. It causes induction of metallothionein which protects cell from toxicity (Oyewopo, A. O. *et al.*, 2010). Zinc deficiency in rats causes changes in seminiferous tubules (Dissanayake *et al.*, 2009). The result of present research indicate that administration of indomethacin in a dose of 10mg/kg suppresses spermatogenesis due to toxic effects of indomethacin on testes seminiferous tubules. Similar finding were reported previously by jhangir *et al.*, 2009. Seminiferous tubules atrophy were observed by administration of propoxur (PPX) by Oyewopo *et al.*, 2010. The results of combination

therapy of zinc and indomethacin showed the protective effects of zinc on spermatogenesis. Study conducted by Falana *et al.*, 2012 observed similar finding. Study conducted by Hamieda 2002 observed similar results. Study conducted by Babaei *et al.*, 2007 also observed the protective effects of zinc on testes. He concluded that zinc has good effects on spermatogenesis.

CONCLUSION

Zinc plays protective role on testes and increases spermatogenesis especially when spermatogenesis was arrested by some drug or chemical.

REFERENCES

1. DiSilvestro, R. A. (2004). *Handbook of minerals as nutritional supplements*. cRc press.
2. Afonne, O. J., Orisakwe, O. E., Ekanem, I. O. A., & Akumka, D. D. (2002). Zinc protects chromium-induced testicular injury in mice. *Indian journal of pharmacology*, 34(1), 26-31.
3. Berdanier, C.D., Dwyer, J. (2007). Nutritional science. *Handbook of Nutrition and Food*; 2.1200.
4. Falana, B. A., & Oyeyipo, I. P. (2012). Selenium and zinc attenuate lead-induced reproductive toxicity in male sprague-dawley rats. *Res J Med Sci*, 6, 66-70.
5. Madding, C. I., Jacob, M., Ramsay, V. P., & Sokol, R. Z. (1986). Serum and semen zinc levels in normozoospermic and oligozoospermic men. *Annals of nutrition and metabolism*, 30(4), 213-218.
6. Alam, M. J., Khatun, M., Begum, M., Hossain, M., Akhter, J., Paul, U. K., & Begum, T. (2009). Role of vitamin E on antispermatogenic effects of indomethacin on number of sperm containing seminiferous tubules of testes in long evans rats. *Bangladesh Journal of Anatomy*, 7(1), 5-9.

7. Dissanayake, D. M. A. B., Wijesinghe, P. S., Ratnasooriya, W. D., & Wimalasena, S. (2009). Effects of zinc supplementation on sexual behavior of male rats. *Journal of human reproductive sciences*, 2(2), 57.
8. Oyewopo, A. O., Saalu, L. C., Osinubi, A. A., Omotoso, G. O., & Adefolaju, G. A. (2010). The attenuating effect of zinc on Propoxur-induced oxidative stress, impaired spermatogenesis and deranged steroidogenesis in wistar rat.