

## Research Article

# Anatomy of Gonads and Sexual Differentiation during Fetal Development of Rabbits

Reda Mohamed\*

Department of Basic Veterinary Sciences, School of Veterinary Medicine, Faculty of Medical Sciences, The University of the West Indies, St. Augustine, Trinidad and Tobago. And Anatomy and Embryology Department, Faculty of Veterinary Medicine, Beni-Suef University, Beni -Suef 62511, Egypt

### Article History

Received: 04.01.2020

Accepted: 18.01.2020

Published: 27.01.2020

### Journal homepage:

<https://www.easpublisher.com/easjvms>

### Quick Response Code



**Abstract:** This aim of this research was to find out the time of sexual differentiation, and to describe the gross morphology of the gonads of the rabbit fetuses. Fifty Balady rabbit fetuses were used in this study. The pregnant rabbits were euthanized, dissected and, subsequently, the fetuses were collected. The gross morphological study revealed that the gonads of the rabbit could be grossly differentiated into testes and ovaries from the 24<sup>th</sup> day postconception. The testes migrated caudally from the caudal kidney pole towards the pelvic inlet where they were situated until the end of the fetal life. The ovaries migrated slightly caudally from the caudal kidney pole to be situated in the sublumbar region.

**Keywords:** Anatomy, Gonads, Fetus, Rabbit.

**Copyright @ 2020:** This is an open-access article distributed under the terms of the Creative Commons Attribution license which permits unrestricted use, distribution, and reproduction in any medium for non commercial use (NonCommercial, or CC-BY-NC) provided the original author and source are credited.

## INTRODUCTION

The rabbit is valued as an experimental animal model used in laboratory researchers as it gives offspring monthly, so it can be used to study the embryology of the gonads. Rabbit is an excellent source of meat with a high percentage of protein fit for human consumption. As there are no much available literatures that describe the gonads of the rabbit during intrauterine life, so the present study aimed to describe the gross anatomy of the gonads, explain the descent of the gonads and detect the time of sexual differentiation during the prenatal period in rabbit.

## MATERIAL AND METHODS

This study has been conducted with the rabbit according to the international ethical standard, by giving minimum pain to the animal. The present study was done on 50 Balady rabbit fetuses ranging from the 23<sup>th</sup> day postcoitum to full term rabbit fetus (full term is 30 to 31 days as mentioned by Nielsen and Torday (1983). The abdominal cavities of the adult, healthy, pregnant female rabbits were opened after euthanasia and the uteri were exposed and separate incisions were made within them. The gonads were fixed in situ by injection into the abdominal cavity with suitable

amount of modified Davidson's fixative (Lihui *et al.*, 2011) and left for few minutes. The gonads of the rabbit fetuses were exposed and dissected carefully in their situ with normal relations by making a transverse cut between the umbilicus and pubic symphysis. The gonads were photographed by using a digital camera (12 mega pixels).

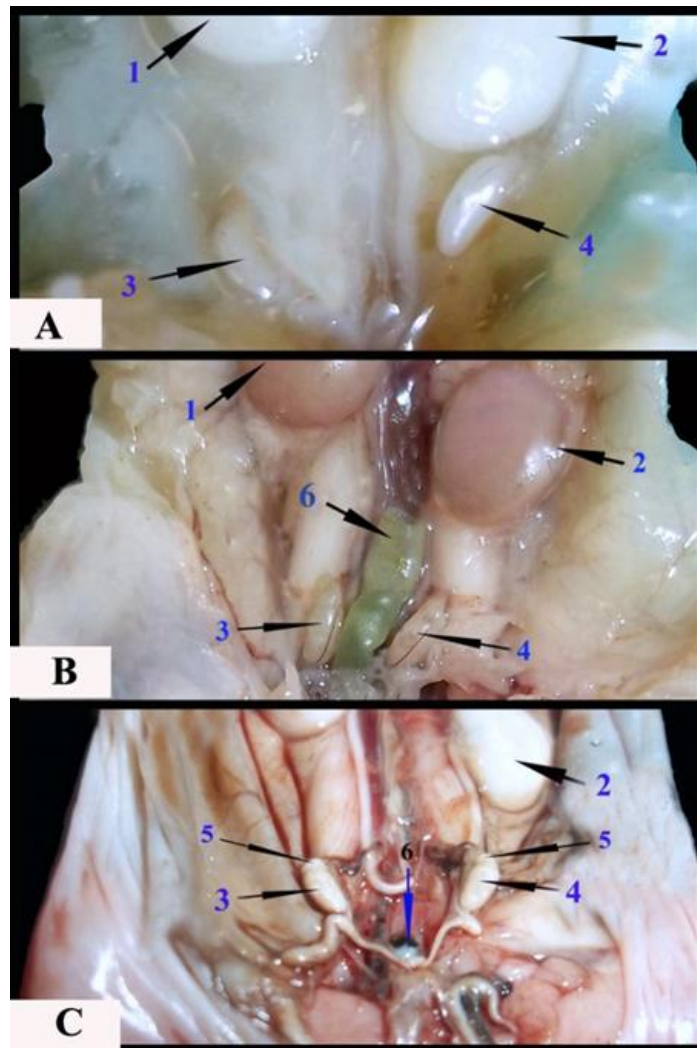
## RESULTS

The sex determination of the gonads of the rabbit fetus either testes or ovaries was still indistinguishable grossly until the 24<sup>th</sup> day postconception. The testes of the 24<sup>th</sup> day old rabbit fetus layed in the region of the kidneys where they were situated intra-abdominally in the sublumbar region caudal to the caudal pole of the corresponding kidney and the right testis was situated in a lower level than that of the left one (Figure 1A). In the following fetal days up to the full term male rabbit fetus, the testes started to move caudally from the region of the caudal kidney pole towards the pelvic inlet where they remained situated. They were separated from each other by a segment of the large intestine. The right testis was still situated in a lower level than the left one (Figure 1B&C).

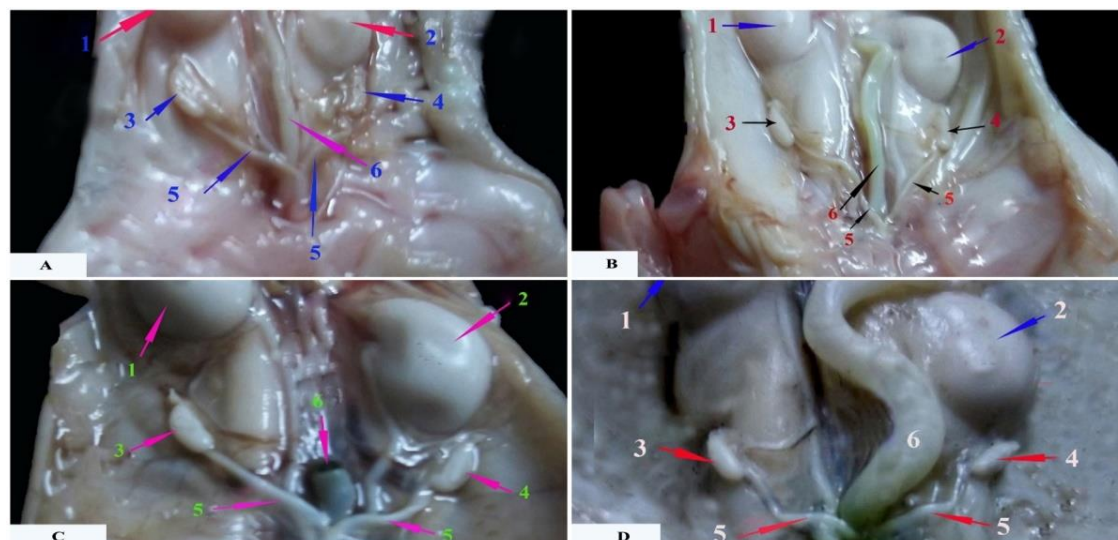
The testes appeared thick, large, and ovoid shape with smooth surface and whitish in color. A well-formed cap of epididymis was seen over the proximal pole of each testis in full term male rabbit fetus (Figure 1C). The migration of the testes occurred intra-abdominal and the testes remained inside the body of the male rabbit fetus until the end of the fetal life.

The ovaries of the 24<sup>th</sup> day old rabbit fetus were located intra- abdominally in the sublumbar region below the caudal pole of the corresponding kidney

(Figure 2A). In the following fetal days up to full term female rabbit fetus, the ovaries moved slightly caudally from the region of the caudal kidney pole to be situated in the sublumbar region in the middle area between the caudal pole of the kidneys and pelvic inlet and were separated from each other by a segment of large intestine. The ovaries were positioned more cranially than the testes and the right ovary was located cranial to the left one. The ovaries were smaller than the testes, thin and elongated in shape. The fallopian tubes and uterine horns were also seen (Figure 2B,C &D).



**Figure. 1:** Photographs of the caudal half of 24<sup>th</sup> day old rabbit fetus showing the grossly differentiation of the testes (A). The caudal half of the 28<sup>th</sup> day old rabbit showing the caudal descent of the testes (B). The caudal half of the full term rabbit fetus showing the final position of the testes (C). 1- Right kidney; 2- Left Kidney; 3- Right testis; 4- Left testis; 5- Head of epididymis; 6- A segment of the large intestine.



**Figure. 2:** Photographs of the caudal half of 24<sup>th</sup> day old rabbit fetus showing the grossly differentiation of the ovaries (A). The caudal half of the 26<sup>th</sup> day old rabbit fetus showing the descent of the ovaries (B). The caudal half of the 28<sup>th</sup> day old rabbit fetus showing the more caudal descent of the right ovary (C). The caudal half of the full term rabbit fetus showing the final position of the ovaries (D). 1- Right kidney; 2- Left Kidney; 3- Right ovary; 4- Left ovary; 5- Uterine horns; 6- A segment of the large intestine.

## DISCUSSION

The current work stated that the gonads can be differentiated grossly into testes in the 24<sup>th</sup> day old rabbit fetus. Similar result was recorded by Nielsen and Torday (1983) and Mario *et al.*, (2018) in the same animal. Fiegel *et al.*, (2010) mentioned that the testes were clearly demonstrated in the 16.5 day old rat fetus.

Our findings as well as Nielsen and Torday (1983) in rabbit ascertained that the testes were located in sublumbar region at a few millimeters below the kidney at the 24<sup>th</sup> day postcoitum, then started to migrate more caudally and they its final position at the entrance of the pelvic inlet in the 28<sup>th</sup> day up to full term male rabbit fetus. Rajfer (1982) observed that the testes of the rabbit descend on or about the 6<sup>th</sup> day postnatal and they reach scrotum at the 22<sup>nd</sup> day postnatal.

Fiegel *et al.*, (2010) reported that the testes of the 17.5<sup>th</sup> day old rat fetus lie in the region of the lower kidney pole and they are finally reaching the inguinal region in the 20<sup>th</sup> day old rat fetus.

The current work revealed that the right testis was situated on a lower level the left one. Moreover, the testes were larger, smooth, thicker and more bulky than the ovaries; such results confirmed those given by Nielsen and Torday (1983) in rabbit fetus and Brambell (1927a) in mouse.

The descent of the rabbit testis was similar to other domestic animals, however the failure of this occurrence is clinically marked as cryptorchidism (Kaleva and Toppari, 2003 and Amann and Veeramachaneni, 2007).

The current work stated that the gonads can be differentiated grossly into ovaries in the 24 day old rabbit fetus, where they located in the sublumbar region at a few millimeters below the kidney at the 24<sup>th</sup> day postconception. They took their final position in the middle area between the kidneys and the pelvic inlet, a result which was reported by Nielsen and Torday (1983) in rabbit.

The present investigation asserted that the right ovary was located in a higher level than the left one. Moreover, the ovaries were thin, translucent and more elongated; similar results were recorded by Nielsen and Torday (1983) in rabbit.

## CONCLUSION

The current study recorded the moment of the sexual differentiation of the gonads of the rabbit fetus. Moreover, this study will be value for embryological and drug researches.

## Acknowledgments

I am very grateful to the technical staff and lab assistants in the Department of Anatomy and Histology for their assistance.

## REFERENCES

1. Amann, R.P., & Veeramachaneni, D.N.R. (2007). *Cryptorchidism in common eutherian mammals. Reproduction, 133, 541-561.*
2. Brambell, F.W.R. (1972a). The development and morphology of the gonads of the mouse. Part I- The morphogenesis of the indifferent gonad and of

- the ovary. *Proc. R. Soc. Lond. B.*, 101 (711), 391-409.
3. Fiegel, H.C., Rolle, U., Metzger, R., Geyer, Ch., Till H., & Kluth, D. (2010). The testicular descent in the rat: a scanning electron microscopic study. *Pediatr. Surg. In.*, 26 (6), 643–647.
  4. Kaleva, M., & Toppari, J. (2003). Genetics and hormones in testicular descent. *Hormones (Athens)*, 2, 211-216.
  5. Lihui, T.U., Lili, Y.U., & Zhang, H. (2011). Morphology of rat testis preserved in three different fixatives. *J Huazhong Univ Sci Technol (Med Sci)*, 31(2),178-180.
  6. Mario, L.C., Borghesi, J., Da Anunciação, A.R.A., Miranda, C.M.F., Dos Santos, A C., Favaron, P.O., Dos Santos, D.M., Conei, D., Vásquez B, Del Sol, M, & Miglino, M.A. (2018). Sexual Determination and Differentiation during embryonic and fetal development of New Zealand Rabbit females. *Int. J. Morphol.*, 36(2), 677-686.
  7. Nielsen, H. C., & Torday, J.S. (1983). Anatomy of fetal rabbit gonads and the sexing of fetal rabbits. *Laboratory Animals*, 17, 148-150.
  8. Rajfer, J. (1982). Endocrinological study of testicular descent in the rabbit. *Journal of Surgical Research*, 33 (2), 158-163.