

Research Article

The Influence of the Angles of the Femoral arterial bifurcation on the Efficiency of Its Stenting

Gaye M^{1,2*}, Ndiaye Ai¹, Diop MS², Wade R¹, Sow NF², Diagne PA², Diatta S², Ba Salmane², Dieng PA², Boufi M³, Ndiaye A⁴, Ciss AG², Ndiaye Ab¹

¹Laboratory of Anatomy and Organogenesis-FMPO-UCAD Senegal

²Thoracic and Cardiovascular Surgery Department - Fann CHNU Senegal

³Vascular Surgery Department - North Hospital of Marseille Senegal

⁴Laboratory of Anatomy and Organogenesis - UAS Ziguinchor Senegal

*Corresponding Author

Magaye GAYE

Abstract: Endovascular surgery of the Femoral arterial bifurcation (femoral tripod) with stenting is currently in full expansion for atheromatous occlusive lesions of this arterial segment. On the other hand, long-term permeability is not good. As a result, several hypotheses are made to control these poor long-term results. Among these hypotheses, the morphological ones take a good place, in particular the angulations between the common femoral artery, the superficial femoral artery and the deep femoral artery. The purpose of this work is to determine the influence of angle on stenting. The CFA / PFA and SFA / PFA angles are measured on a 3D image of the Femoral arterial bifurcation (femoral tripod) extracted with the endoSize software. On average, the angle CFA / PFA measured 157° and the angle SFA / PFA measured 23.8°. Compared to coronary bifurcation, the acute or obtuse character of the CFA / PFA and SFA / PFA angles should be a determining factor in the choice of stenting technique; whether she has one or two stents.

Keywords: stenting, angle, femoral tripod, bifurcation, permeability, morphology.

INTRODUCTION

Endovascular treatment has become, the last two decades, as an alternative to conventional surgery for the treatment of both aortic and peripheral arterial diseases. The limits of these endovascular therapies are constantly being repulsed and the femoral tripod is one of the examples that illustrates the extension of indications to territories previously considered to be contraindicated. While femoral tripod surgery is the gold standard for atheromatous lesions (Gouëffic, Y. *et al.*, 2017), it remains associated with a postoperative mortality of 3.4% (Nguyen, B. N. *et al.*, 2015) and a significant local complication rate, ranging between 6.6%. And 28.3% according to the literature, with type of surgical site infection, hematoma, lymphorrhoea and paresthesia (Gouëffic, Y. *et al.*, 2017; Ballotta, E. *et al.*, 2010) requiring reintervention in more than one third of cases (Wieker, C. M. *et al.*, 2016).

Actually the place of endovascular treatment and surgery in the management of occlusive lesions of

the femoral tripod remains controversial between the advocates of surgery who argue for a better long-term permeability: primary and primary assisted patency at age 5 respectively of 91% and 100% (Kang, J. L. *et al.*, 2008); and advocates of endovascular treatment who emphasize the reduction of mortality, morbidity and length of stay (Gouëffic, Y. *et al.*, 2017). Different endovascular approaches (simple angioplasty, cutting balloon, atherectomy, stenting) have been proposed but no consensus exists to date on the optimal technique. Moreover, while in the field of endovascular therapeutics, anatomy remains the most important decision-making element. There is no work focused on the analysis of morphometry that has been published in the literature of the femoral tripod. In addition, the anatomical criteria for selecting patients for endovascular treatment are not clearly studied. Therefore, the aim of this work is to analyze, based on the morphological data of the stenting of the coronary bifurcation, the influence of the angles of the femoral tripod on the results of its stenting.

Quick Response Code



Journal homepage:

<http://www.easpublisher.com/easms/>

Article History

Received: 17.08.2019

Accepted: 25.08.2019

Published: 02.09.2019

Copyright © 2019: This is an open-access article distributed under the terms of the Creative Commons Attribution license which permits unrestricted use, distribution, and reproduction in any medium for non commercial use (NonCommercial, or CC-BY-NC) provided the original author and source are credited.

MATERIALS AND METHOD

This is a retrospective study from January 2015 to July 2017 involving 65 patients (70 sides) who were hospitalized, in the Department of Vascular Surgery of the North Hospital of Marseille, for the surgical management of arterial disease of the lower extremities related to lesions of the femoral tripod.

Inclusion criteria are for patients with (Gouëffic, Y. *et al.*, 2017) significant lesions of the femoral tripod isolated or associated with other lesions, (Nguyen, B. N. *et al.*, 2015) treated by conventional surgery isolated or associated with endovascular staging of upstream or downstream lesions, and (Ballotta, E. *et al.*, 2010) having angioTDM imaging. The exclusion criteria are the absence of angioTDM of the arteries of the lower limbs of good quality allowing the extraction of a central line.

In addition to the clinical data, morphological data at the femoral tripod are collected from the angioTDM analysis using the EndoSize image processing software. The images are transferred in DICOM format to a console with this software. After the determination of a proximal point at the level of the birth of the common femoral artery (CFA) taking as a reference the birth of the inferior epigastric artery, and a distal point located 5 cm downstream of the birth of the superficial femoral artery (SFA) an automatic segmentation is performed followed by the extraction of a primary 3D central line. A second secondary central line is then created that begins at the femoral bifurcation and ends 5cm downstream of the birth of the deep femoral artery (PFA). The image of the extracted 3D femoral tripod allows us to measure: the angle α formed between the common femoral artery and the deep femoral artery and the angle θ between the superficial femoral artery and the deep femoral artery. Measurements were performed using 90 ° right anterior oblique incidence as reference (Figure 1).

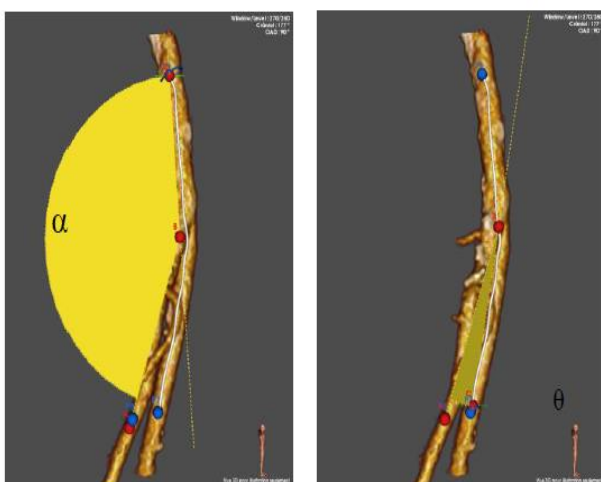


Figure 1: CFA/PFA and PFA/SFA angle measurement methods

RESULTS

The average age was 69.4 years old. There was a male predominance. The sex ratio was 4: 1. The average body mass index was 25.

In terms of antecedents and cardiovascular risk factors, smoking was found in 75.7% of patients, diabetes in 27.1% of patients, hypertension in 61.4% of patients, dyslipidemia in 21.4% of patients; % of patients and cannabis use in 2.9% of patients. In addition, in 8.6% of patients, no cardiovascular risk factors were found.

Two patients (2.9%) were renally impaired at the dialysis stage.

Clinically, 27% of patients were at stage 3 of the Rutherford classification. The systolic pressure index averaged 0.41 (Table 1).

Table 1: Demographic and Clinical Characteristics

Age	69.63 years	Extremes (année) : 44-95
Sex	H: 81.4% (n = 57) F: 18,6% (n=13) Sex Ratio 4:1	
BMI	24.63	
Tobacco	75.7% (n = 53)	
Diabetes	27.1% (n = 19)	
HTA	61.4% (n = 43)	
Dyslipidemia	21.4% (n = 15)	
Cannabis	2.9% (n = 2)	
Dialysis	2.9% (n = 2)	
Classification de Rutherford		
0	1.4% (n = 1)	
1	8.6% (n = 6)	
2		
3	25,7% (n = 18)	
4		
5	38,6% (n = 27)	
6	4,3% (n = 3)	
	18,6% (n = 13)	
	2,9% (n = 2)	
IPS	0,41	

The angle α formed by the CFA and the PFA, on a 90 ° OAD incidence, was on average 157 ° and that θ between the CFA and the SFA was 23.8 °

DISCUSSION

Blood flow at a bifurcation is complex. It includes vortex formation and the creation of areas of low turbulence and shear stress. These phenomena alter hemodynamics. The latter, associated with the turbulence caused by the presence of a stent, are factors providing restenosis (Zheng, X. *et al.*, 2016).

At the coronary level, different stenting strategies exist for bifurcation lesions. There are two-stent strategies such as Culotte-stenting, T-stenting, kissing-stenting and crush-stenting, and one-stent strategy (Figures 2 and 3).

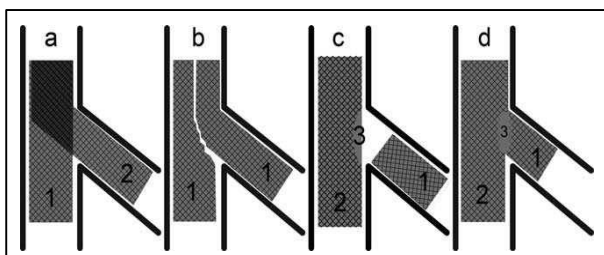
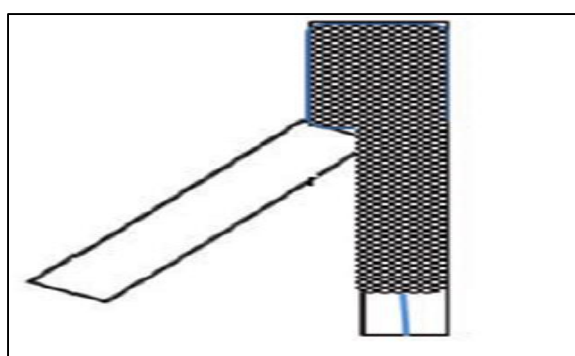
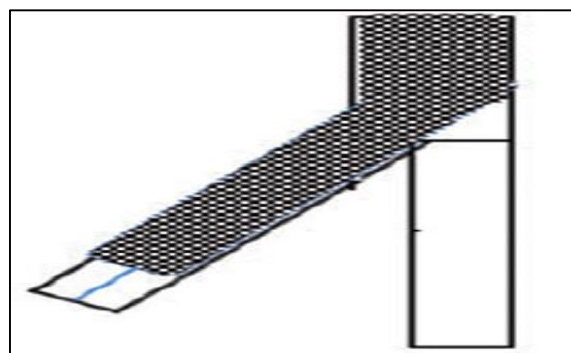


Figure 2: illustration of the different stenting techniques at bifurcations: (a) culotte-stenting, (b) kissing-stenting, (c) T- stenting, (d) crush stenting



A stent with AFP coverage



A stent with AFS coverage

Figure 3: One-stent strategy with an artery cover

With regard to the one-stent strategy, acute-angle bifurcations have more favorable results than obtuse-angle ones (Zheng, X. *et al.*, 2016; Medrano-Gracia, P. *et al.*, 2017). In our morphological analysis, the angle CFA /PFA is obtuse and that PFA /SFA is acute; thus we can deduce that CFA-SFA stenting by covering PFA should give good results compared to CFA-PFA stenting. The measurement of the angle of the bifurcation is also decisive in the choice of the two-stent strategy. Indeed, the use of two stents is burdened with a poor result when the angle of the bifurcation is greater than 50 °, due to the significant overlap of the stents at the hull (Mishra, S. 2016). The recommended rule is to make the least possible overlap and adapt the

technique according to the angle of the bifurcation: in case of acute angle the culotte-stenting technique is preferred; on the other hand, in case of obtuse angle, T-stenting is recommended.

These analyzes should be confirmed by a biomechanical study, by simulation, involving stents deployed in the bifurcation and blood flow.

CONCLUSION

Stenting of the femoral bifurcation should be done taking into account the anatomical particularities of each femoral tripod. The angulations between the femoral artery and its two superficial and deep branches are a determining factor for the technical success but also for the permeability of the vessels stented in the long term.

REFERENCES

- Gouëffic, Y., Della Schiava, N., Thaveau, F., Rosset, E., Favre, J. P., du Mont, L. S., ... & Ducasse, E. (2017). Stenting or surgery for de novo common femoral artery stenosis. *JACC: Cardiovascular Interventions*, 10(13), 1344-1354.
- Nguyen, B. N., Amdur, R. L., Abugideiri, M., Rahbar, R., Neville, R. F., & Sidawy, A. N. (2015). Postoperative complications after common femoral endarterectomy. *Journal of vascular surgery*, 61(6), 1489-1494.
- Ballotta, E., Gruppo, M., Mazzalai, F., & Da Giau, G. (2010). Common femoral artery endarterectomy for occlusive disease: an 8-year single-center prospective study. *Surgery*, 147(2), 268-274.
- Wieker, C. M., Schönefeld, E., Osada, N., Lührs, C., Beneking, R., Torsello, G., & Böckler, D. (2016). Results of common femoral artery thromboendarterectomy evaluation of a traditional surgical management in the endovascular era. *Journal of vascular surgery*, 64(4), 995-1001.
- Kang, J. L., Patel, V. I., Conrad, M. F., LaMuraglia, G. M., Chung, T. K., & Cambria, R. P. (2008). Common femoral artery occlusive disease: contemporary results following surgical endarterectomy. *Journal of vascular surgery*, 48(4), 872-877.
- Zheng, X., Peng, H., Zhao, D., Ma, Q., Fu, K., Chen, G., ... & Liu, J. (2016). Optimal Revascularization Strategy on Medina 0, 1, 0 Left Main Bifurcation Lesions in Type 2 Diabetes. *Journal of diabetes research*, 2016.
- Medrano-Gracia, P., Ormiston, J., Webster, M., Beier, S., Ellis, C., Wang, C., ... & Cowan, B. (2017). A study of coronary bifurcation shape in a Normal population. *Journal of cardiovascular translational research*, 10(1), 82-90.
- Mishra, S. (2016). Dedicated bifurcation stents—Mechanistic, hardware, and technical aspects. *Indian heart journal*, 68(6), 841-850.