

Case Report

Mesothelioma of the Tunica Vaginalis

Parvathy V^{*1} and Sankar Sundaram²

¹Junior Resident, Department of Pathology, Government Medical College Kottayam, Kerala, India

²Professor and Head, Department of Pathology, Government Medical College Kottayam, Kerala, India

Article History

Received: 28.01.2020

Accepted: 29.02.2020

Published: 15.03.2020

Journal homepage:

<http://www.easpublisher.com/easms/>

Quick Response Code



Abstract: Testicular mesothelioma is a rare form of mesothelioma accounting for less than 1 % of the cases. We present a case of 75 year old male who presented with right scrotal swelling and he underwent right high inguinal orchidectomy. A final diagnosis of Mesothelioma –low grade (Epithelial) was made on the histopathology.

Keywords: Testicular mesothelioma, hematocele.

Copyright @ 2020: This is an open-access article distributed under the terms of the Creative Commons Attribution license which permits unrestricted use, distribution, and reproduction in any medium for non commercial use (NonCommercial, or CC-BY-NC) provided the original author and source are credited.

INTRODUCTION

Testicular mesothelioma is a neoplasm of the membrane lining of the testes. This rare condition accounts for less than 1 % of all mesothelioma cases. Since the first case reported, fewer than 100 cases have been reported to date. Most of the testicular mesothelioma patients however have no history of asbestos exposure.

CASE REPORT

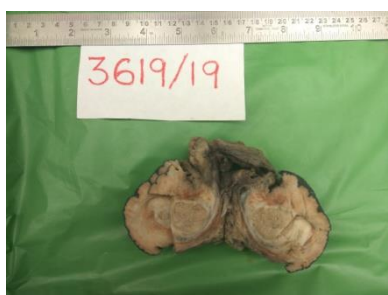A 75 year old male who presented with right scrotal swelling of 1 year duration. He gives a history of increase in size recently. On physical examination the patient was diagnosed to have right hematocele. No palpable lymph nodes were detected in the pelvis or inguinal areas. CECT of abdomen and pelvis was

performed and it revealed an irregular thickening of the scrotum, enhancement of tunica vaginalis and fluid collection in the sac. The levels of AFP and LDH were within normal limits.

Right Jabouleys procedure was done to relieve hematocele and biopsy at that time was reported as possibility of Mesothelioma or Adenocarcinoma. After 3 months, the patient underwent right high inguinal orchidectomy with wide local excision.

GROSS

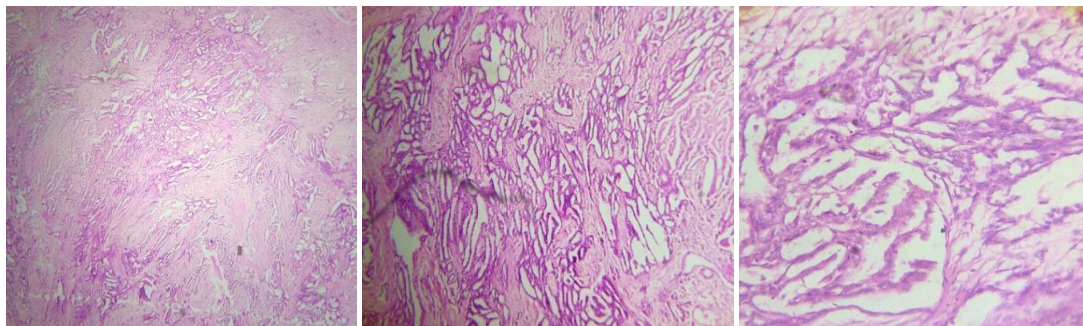
The specimen of testes with attached scrotal skin and spermatic cord show in paratesticular area an irregular whitish mass measuring 2.5x2x1.5 cm.



MICROSCOPY

Showed an infiltrating neoplasm arranged in tubular pattern. The individual cells have scanty

cytoplasm and ovoid vesicular nuclei. Focal sarcomatoid area and stromal collagenisation noted. Sparse mitosis noted.



IHC

Diffuse immunoreactivity was evident against mesothelial markers including calretinin, cytokeratin 7 and negative immunostaining for CEA, CK 20 and TTF 1.

Hence a diagnosis of Mesothelioma low grade (Epithelial) was made. The excision was found to be complete and on follow up the patient is doing well.

DISCUSSION

Malignant mesothelioma of the Tunica vaginalis testis is an extremely rare condition .The first case was reported in 1957.Although the tumour is most often seen in patients between the ages of 55 and 75 years, 10 % of the patients are younger than 25years. Mesothelioma has been strongly related to asbestos exposure and long standing hydrocele.However there are cases of mesothelioma without history of exposure to asbestos.This condition is associated with high recurrence and mortality rates.Testicular mesothelioma arises from the tunica vaginalis, often in relation to the epididymis, testes or spermatic cord. Mesothelioma has 3 histological subtypes–Epithelial (60-70%), spindle cell (least common) and biphasic (30-40 %).Epithelial type has papillary, tubular,adenomatoid or solid

architectural patterns.Most well differentiated tumours have predominance of epithelial types.Surgery should be the first line therapy in case of early disease. Adjuvant therapy with systemic chemotherapy and radiotherapy might provide a better overall survival.

CONCLUSION

This case of Testicular mesothelioma in an old man with hematocele is reported for its rarity.

REFERENCE

1. Tan, W. K., Tan, M. Y., Tan, W. S., Gan, S. C., Pathmanathan, R., Tan, H. M., & Tan, W. P. (2016). Well-differentiated papillary mesothelioma of the tunica vaginalis: case report and systematic review of literature. *Clinical genitourinary cancer*, 14(4), e435-e439.
2. Tan, W. K., Tan, M. Y., Tan, H. M., Pathmanathan, R., & Tan, W. P. (2016). Well-differentiated papillary mesothelioma of the tunica vaginalis. *Urology*, 90, e7-e8.
3. Segura-González, M., Urias-Rocha, J., & Castelán-Pedraza, J. (2015). Malignant Mesothelioma of the Tunica Vaginalis: A Rare Neoplasm--Case Report and Literature Review. *Clinical genitourinary cancer*, 13(6), e401.