

Epidemio-Clinical Diagnostic and Therapeutic Aspects of Acute Intestinal Invagination in Infants and Children at Fousseyni Daou Hospital in Kayes (Mali)

Kouyate, M^{1,2*}, Traore, I. L^{3,2}, Sangare, S^{3,2}, Diakite, A. S^{5,2}, Toure, S^{4,2}, Magassa, M⁵, Dicko, B^{4,2}, Kane, M³, Haidara, M¹

¹Service De Chirurgie Pédiatrique De L'hôpital Fousseyni Daou, Kayes, Mali

²Centre National De Recherche Scientifique et De Technologie (CNRST), Bamako, Mali

³Unité De Chirurgie Générale De L'hôpital Fousseyni Daou, Kayes, Mali

⁴Service De Pédiatrie Fousseyni Daou, Kayes, Mali

⁵Service D'urologie De L'hôpital Fousseyni Dao de Kayes

*Corresponding author: Kouyate, M

| Received: 11.06.2022 | Accepted: 21.07.2022 | Published: 27.07.2022 |

Abstract: Intussusception is a condition characterized by the penetration of one segment of the intestine into another. It is a medical emergency characterized by bowel obstruction. It can be fatal if left untreated, and occurs most often in children. It is a fairly common pathology in our country with seasonal peaks. The objective of this study is to describe the diagnostic and therapeutic clinical epidemiological aspects of intussusception in infants and children in the pediatric surgery department of Fousseyni Daou hospital. Material and methodology: This is a retrospective study which took place from January 2019 to December 2021 at the Fousseyni Daou hospital in Kayes and included in this study all children operated on for intussusception from 0 to 15 years, through the use of patient records. **Results:** During the study period, we operated on 975 patients, including 63 occlusions and 27 intussusceptions, i.e. 2.76% of operations and 42.85% of occlusions. The male sex was the most represented 18 cases or 66.66%. There was the notion of abdominal pain in all patients, vomiting in 18 patients and rectal bleeding in 7 patients. At the clinical examination the sausage was found in 18 patients, a standard blood test was carried out in all the patients. Ultrasound was the main radiological examination to confirm intussusception. Treatment was surgical in all patients, with resection. Anastomosis in 6 cases due to late management of these patients. In the immediate postoperative course, we noted two surgical site infections and one eventration. **Conclusion:** Intussusception is a fairly common pathology in our region, but the evolution of which depends on the promptness of treatment.

Keywords: Intussusception, occlusion, epidemiology, Kayes.

INTRODUCTION

Acute intussusception is defined as the telescoping of a proximal intestinal segment and its meso into the lumen of the distal intestinal segment, progression occurring in the peristaltic direction. It is a strangulation that compresses the mesenteric vessels of the invaginated portion leading to ischemia, necrosis and intestinal perforation. It is idiopathic in about 90% of cases in the pediatric population [1-4], but organic causes can be found in some older children and adults [7, 12, 13]. The management depends on the promptness of the diagnosis which can give way to medical treatment [3, 4, 7, 8, 11]. The mortality of intussusception depends on the clinical presentation of

the patient, but also on the therapeutic means. It can vary between 1% and 55% depending on the series [1, 2, 4, 6, 13]. The delay in diagnosis leads to irreversible lesions requiring surgical treatment.

The objective of this work was to report the diagnostic and therapeutic clinical epidemiological aspects of acute intestinal intussusception in infants and children at the Fousseyni Daou hospital in Kayes.

PATIENTS AND METHODS

This was a retrospective study over a period of 3 years (January 2019 to December 2021) at the Fousseyni Daou hospital in Kayes by using patient files.

Quick Response Code



Journal homepage:

<https://www.easpublisher.com/>

Copyright © 2022 The Author(s): This is an open-access article distributed under the terms of the Creative Commons Attribution **4.0 International License (CC BY-NC 4.0)** which permits unrestricted use, distribution, and reproduction in any medium for non-commercial use provided the original author and source are credited.

Citation: Kouyate, M, Traore, I. L, Sangare, S, Diakite, A. S, Toure, S, Magassa, M, Dicko, B, Kane, M, Haidara, M (2022). Epidemio-Clinical Diagnostic and Therapeutic Aspects of Acute Intestinal Invagination in Infants and Children at Fousseyni Daou Hospital in Kayes (Mali). *Cross Current Int J Med Biosci*, 4(3), 67-70.

Included in this study were all patients (infants and children) operated on for acute intussusception, other types of obstruction were excluded from the study.

RESULTS

During the study period (January 2019 to December 2021), we had collected 63 cases of mechanical acute intestinal obstruction in children, including 27 cases of acute intussusception, i.e. 42.85% of cases and i.e. 2, 76% of all interventions in 3 years. We had noted a slight increase in cases during the months of February to June. Acute intussusception had a frequency of 9 cases / year. The notion of vaccination was not taken into account during this study. The male sex was predominant (18), i.e. 66.66% of cases and the female sex 9 cases, i.e. 33.33% (Table 2). The patients were aged from 4 months to 48 months. Infants aged 4 months to 24 months represented 74.07% (n=20) and 7 were under age or equal to 4 years, i.e. 25.92% (Table 3) patients (Table 1). Intraoperatively we had discovered 16 ileo-coeco-colic intussusception, that is 59.25%; 7 colo-colic, i.e. 25.92% and 4 ileo-ileal, i.e. 14.81% (Table 4) and 4 stomas. We had detected a case of intussusception secondary to a sigmoid tumour: Fig 3 whose anastomosis resection had been performed intraoperatively Fig 4. Anatomopathology found a benign tumor. The 4 patients with ostomy underwent an end-to-side ileocecal anastomosis. In the postoperative course, we recorded two parietal suppurations and one eventration. We had recorded two cases of death, i.e. 7.40%

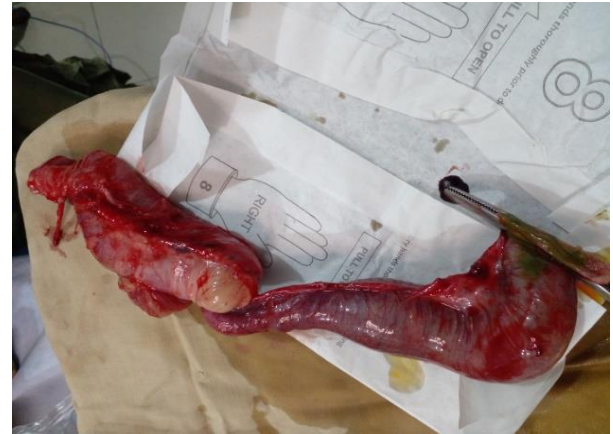

Fig 2: Necrotic sausage resected after resected tumor

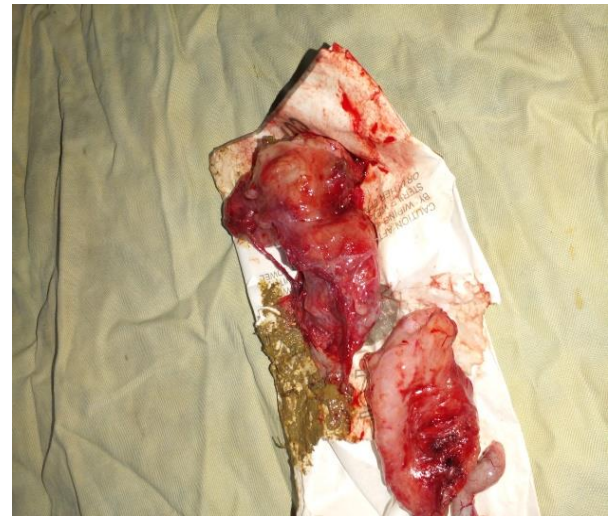

Fig 3: Resected tumor

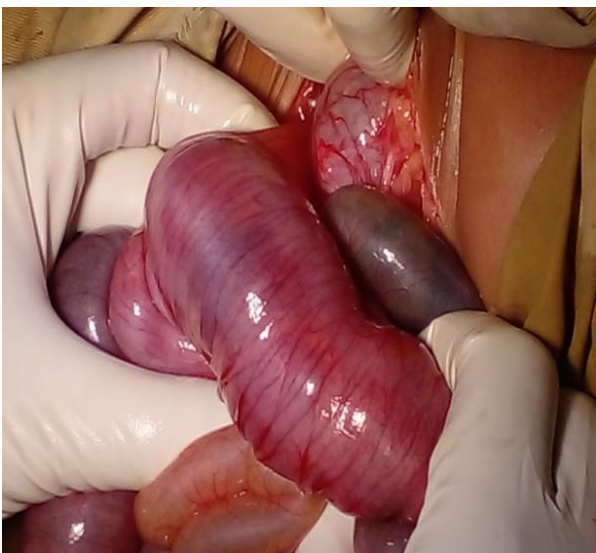


Fig 1: Sausage of invagination

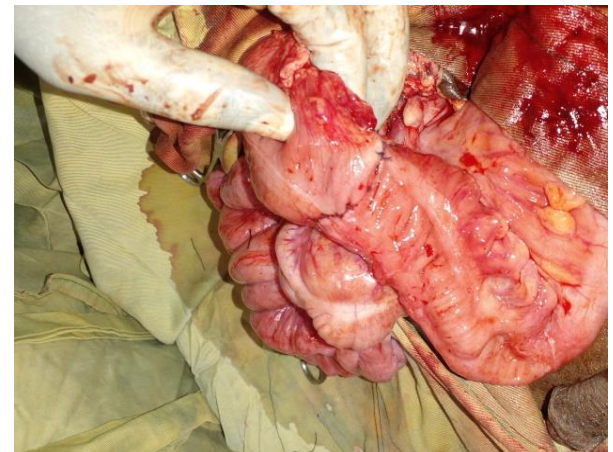


Fig 4: End-to-end colo-colonic anastomosis

Table 1: Distribution according to the main clinical signs encountered

Signs	Number of cases Percentage (%)	Number of cases Percentage (%)
Abdominal pain	27	100%
Vomiting	18	66,66%
Rectal bleeding	7	25,92%
Invagination Sausage	18	66,66%

Table 2: Distribution of patients by gender

Sex	Nombre	Pourcentage
Male	18	66,66%
Feminine	9	33,33%
Total	27	100%

Table 3: Breakdown by age

Age	Number	Pourcentage
4 months to 24 months	20	74,07%
25 to 48 months	7	25,92%
Total	27	100%

Table 4: Distribution by type of intussusception

Type of intussusception	Number	Pourcentage
Ileo-coeco-collic	16	59,25%
Colo-collic	7	25,92%
Ileo-ileal	4	14,81%
Total	27	100%

DISCUSSION

During this 3-year study period from January 2019 to December 2021, we had observed, like the data in the literature, that acute intussusception is the most frequent occlusion in infants and children [1, 10-12]. In our series it represents 42.85% of acute mechanical occlusions, a male predominance in our series (Table 2) is consistent with many other studies [1, 4, 6, 9], on the other hand Mouafo *et al.*, [3] had found a female predominance of about 70%. The frequency found / year during our study is 9 cases / year, which is similar to that of Harouna *et al.*, [4] in Niamey in Niger who had reported 11 cases / year, however Ngowé *et al.*, [2] to Yaoundé had found 4.77 cases of intussusception / year. In our study the idiopathic causes of intussusception were 96.29% which is similar to the literature [1-4]. Some authors mention a frequency of idiopathic intussusception during hot periods of the year [3, 4], in our study we observed a peak in idiopathic intussusception from February to June. The median consultation time was 48 hours, which explains the delay in diagnosis.

Abdominal pain was found in all patients, the notion of vomiting in 66.66% of cases and rectal bleeding in 7 patients, i.e. 25.92% (Table 1). These three signs are characteristic of intussusception, but their Association is not compulsory. Other signs may or may not be associated, such as pallor, unusual crying abdominal distension refusal to suckle dehydration, palpation of the pudding [2]. For Baule *et al.*, [5], "in a child aged 3 months to 3 years, pain rhythmic abdominal pain, with pallor and vomiting, refusal to suckle are suspected of acute mechanical intestinal intussusception". In developed countries, the means of imaging and early consultations allow early diagnosis and therefore treatment without resorting to surgery. In our study, ultrasound had visualized the intussusception tube in 95% of our patients, however Ngowé *et al.*, [2], had reported in their study that the intussusception tube

was noted in 100% of cases at Abdominal ultrasound. All our patients had undergone surgical treatment because of the delay in diagnosis. The high number of necrosis in our patients can be explained by the delay in consultations and the waiting time before surgery. In the literature, the mortality rate varies between 7 and 55% [1, 6, 7, 14] during this study our mortality rate was 7.40%, i.e. 2 out of 27 patients.

CONCLUSION

Acute intussusception is quite common in our region, but its evolution depends on the promptness of treatment.

REFERENCES

1. L'invagination intestinale aiguë secondaire chez l'enfant dans le service de chirurgie pédiatrique du CHU Gabriel Touré. Thèse de Médecine 2017-2018 Seybou Baba DIARRA Page 93 Invagination intestinale aiguë du nourrisson et de l'enfant. *EMC-pédiatrie 2* (2005) 45-57.
2. Ngowé Ngowé, M., Mouafo Tambo, F. F., Salihou, A., Ondobo, A., & Sosso, M. A. (2013). Les invaginations intestinales du nourrisson et de l'enfant à yaoundé. *J Afrchir*, 2(3), 132-137.
3. Mouafo Tambo, F. F., & Andze, O. (2009). Les Invaginations Intestinales Aigues Du Nourrisson Et De L'enfant En Milieu Africain: Interet D'un Diagnostic Precoce. *Mali Médical*, 24(2), 46-49.
4. Harouna, Y., Tardivel, G., Abdou, I., Gamatie, Y., Mariama, S., & Bia, M. (1997). Pronostic de l'invagination intestinale aiguë du nourrisson à l'hôpital national de Niamey (Niger). A propos de 11 cas traités chirurgicalement. *Bulletin de la société de pathologie exotique*, 90(1), 30-32.
5. Baud, C., Prodhomme, O., Forgues, D., Saguintaah, M., Veyrac, C., & Couture, A. (2015). Invagination intestinale aigue du nourrisson et de l'enfant *Feuill Radiol*. <http://dx.doi.org/10.1016/j.Frad.2015.06.007>

6. Aubrespy, P., Derlon, S., Alessandrini, P., SERIAT-GAUTIER, B., & JALLUT, Y. (1983). Invagination intestinale aiguë du nourrisson et de l'enfant. Analyse de 125 observations traitées chirurgicalement. *Chirurgie pédiatrique (Paris)*, 24(6), 392-395.
7. Huppertz, H. I., Soriano-Gabarró, M., Grimprel, E., Franco, E., Mezner, Z., Desselberger, U., ... & Giaquinto, C. (2006). Intussusception among young children in Europe. *The Pediatric infectious disease journal*, 25(1), S22-S29.
8. Akbulut, S. (2012). Unusual cause of adult intussusception: diffuse large B-cell non-Hodgkin's lymphoma: a case report and review. *Eur Rev Med Pharmacol Sci*, 16(14), 1938-1946.
9. Ongom, P. A., Opio, C. K., & Kijjambu, S. C. (2014). Presentation, aetiology and treatment of adult intussusception in a tertiary Sub-Saharan hospital: a 10-year retrospective study. *BMC gastroenterology*, 14(1), 1-8.
10. Enehwi, A. (2016). Les invaginations intestinales aiguës secondaires chez l'enfant. [Thèse Med]. Marrakech: Université CADI-AYYAD, 166. N° = 959.
11. Traoré, D., Sissoko, F., Ongoiba, N., Traoré, I., Traoré, A. K., & Koumaré, A. K. (2012). Intussusception: diagnostic, morbidité et mortalité dans un pays en développement. *Journal de chirurgie viscérale Juin*, 149(3), 211-214.
12. West, K. W., Stephens, B., Rescorla, F. J., Vane, D. W., & Grosfeld, J. L. (1988). Postoperative intussusception: experience with 36 cases in children. *Surgery*, 104(4), 781-787.
13. De Vries, S., Sleeboom, C., & Aronson, D. C. (1999). Postoperative intussusception in children. *British Journal of surgery*, 86(1), 81-83.
14. Bai, Y. Z., Chen, H., & Wang, W. L. (2009). A special type of postoperative intussusception: ileoileal intussusception after surgical reduction of ileocolic intussusception in infants and children. *Journal of pediatric surgery*, 44(4), 755-758.