

Research Article

Doppler Auditory Assistance - Arterial Cannulation Made Easy

Sajjan Prashant Shivaraj¹ & Kulkarni Vandana Sharashchandra*²¹Associate Professor, Department of Anaesthesiology, Aarupadai Veedu Medical College, Kirumampakkam, Puducherry 607403, India²Associate Professor. Department of Anaesthesiology, Aarupadai Veedu Medical College, Kirumampakkam, Puducherry 607403, India

Article History

Received: 05.05.2020

Accepted: 25.05.2020

Published: 30.05.2020

Journal homepage:

<https://www.easpublisher.com/easjacc>

Quick Response Code



Abstract: Background- Intra-arterial cannulation for invasive blood pressure monitoring is required in patients with shock. However in these patients it is difficult to pass the cannula because of difficulty in palpation of artery. Few tools like ultrasound guidance and Doppler auscultatory assistance are available to locate the artery in such difficult cases. However use of ultrasound requires practical as well as operator knowledge. Hand held fetal Doppler auscultatory assistance device is an easily available tool that can be effectively used for arterial cannulation in patients with shock. **Method:** This is a prospective study conducted in 100 patients who were admitted to Intensive care unit with shock. Here intra-arterial cannulation was done with the help of hand held Doppler auscultatory assistance device by an inexperienced operator. We observed the ease of cannulation indicated by number of attempts, number of cannulas used, failure to cannulate and post cannulation complications in difficult conditions like shock, by inexperienced operators. **Result** - In 72 patients cannula was placed in first attempt, 12 patients required 2-3 attempts. In 10 patients though artery was located cannulation was unsuccessful and different site was cannulated. These 10 patients required more than 2 cannula as they were damaged during the procedure. In 6 patients neither artery was located satisfactorily nor were we able to cannulate the artery. **Conclusion** - A simple hand held Doppler auscultatory assist device can be used to cannulate the artery in difficult cases even by inexperienced operator where palpation of artery is difficult.

Keywords: Intra-arterial cannulation, Doppler auscultatory assistance, shock.

Copyright © 2020 The Author(s): This is an open-access article distributed under the terms of the Creative Commons Attribution **4.0 International License (CC BY-NC 4.0)** which permits unrestricted use, distribution, and reproduction in any medium for non-commercial use provided the original author and source are credited.

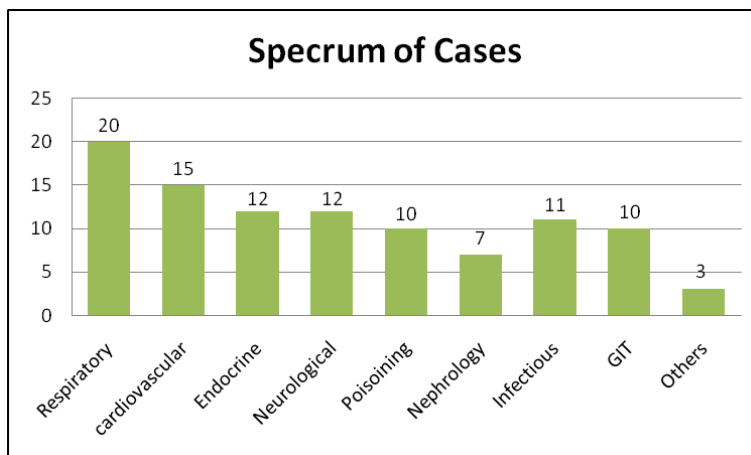
INTRODUCTION

The first successful arterial cannulation was described by Peterson *et al.* in 1949. Arterial cannula insertion has evolved from insertion of a metal needle to the polyethylene catheter. The method of insertion has developed and modified from simple percutaneous needle insertion, arterial cut down to the catheter over needle technique.(Peterson LH, Dripps RD, Risman GC.1949)(Barr PO 1961) (Seldinger SI1953).Continuous haemodynamic monitoring is one of the main goals of intensive care management as it determines cardiac status and organ perfusion. Blood pressure is one of the main haemodynamic parameters monitored in intensive care units (ICU). It can be monitored both invasively and non-invasively. Both techniques have got their own advantages and disadvantages. However invasive blood pressure (IBP) monitoring is the gold standard of blood pressure measurement because of its accuracy and continuous beat to beat measurement.(Chatterjee A, *et al.*, 2010),(McGhee BH, Bridges EJ.2002). Traditionally anaesthesiologists or intensivists are used to pass the arterial cannula by palpating the pulsatile artery at different sites. (Schindler_E *et al.*, 2005). But in cases

of shock the arteries may not be well palpable enough to pass the intra-arterial catheter. This may lead to confusion or difficulty in identifying the course of artery and hence difficulty in cannulation; thus causing many unwanted complications ranging from multiple punctures to irreversible ischemic changes of the limb. (Brown AE, Sweeney DB, Lumley J.1969) (Soderstrom CA.1982) (Downs JB.1973) (Scheer BV.2002) (Varga_EQ *et al.*, 2013). There are a few tools which can help Anaesthesiologist or Intensivist in locating the artery in such difficult scenarios. Doppler auscultatory assistance is one of these methods which can help in locating the artery. In this article we have evaluated the use of hand held fetal heart monitor Doppler assistance as an easy and economic mode for intra arterial cannulation in shock patients.

MATERIALS AND METHODS

After ethical committee permission, the study was conducted prospectively in 100 patients of either sex with shock. The patients were admitted to the ICU with shock and required continuous invasive blood pressure monitoring.



Inclusion Criteria

Patients with shock for various causes.

(Hemorrhagic, septic, anaphylactic etc.)Patients on inotropic and vasopressor support.

Exclusion Criteria

Patients not in shock

1. Arterial Cannulation for other than haemodynamic monitoring (Frequent ABG, Angio etc)
2. Patients with gangrenous changes
3. Pediatric patients (Due to unavailability of paediatric cannula).
4. Any other contraindication for arterial Cannulation.

Presence of pulsatile blood gush after removing the stylet of the arterial cannula was considered as the end point of the study.

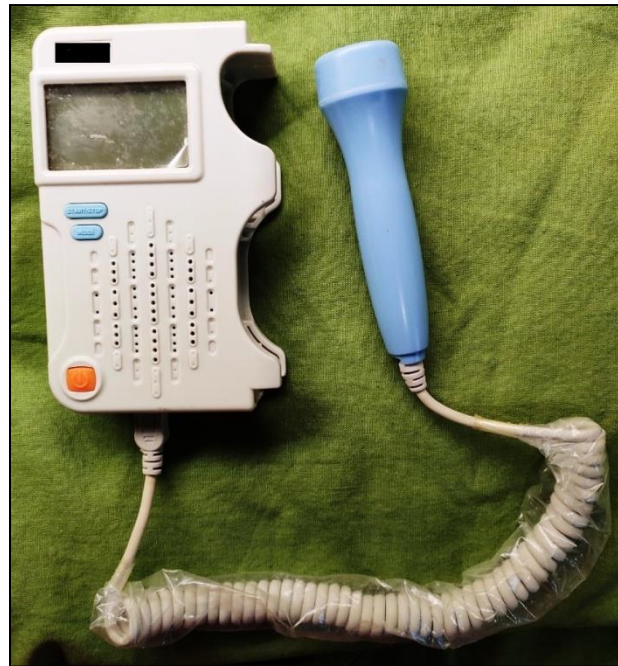Shock was defined by evidence of hypotension or hypoperfusion requiring inotropic or vasopressor support and continuous blood pressure monitoring. The operator was either an anaesthesiology resident or critical care resident. None of the operators had prior experience of placing the arterial cannula with the help of Doppler auscultation assistance. Before initiation of the procedure a brief demonstration of the instrument regarding its usage was given. The radial artery of non dominant hand was selected for placement of the

cannula. Collateral circulation of the hand was noted. The technique of cannulation remained the same. The patient's hand was restricted for movements by adhesive tape and wedge was placed below the wrist joint. Location of the artery was done with the help of Doppler auscultatory assistance where maximum sound of Doppler flow was heard. Skin was pricked approximately 0.5 cm distal to the Doppler probe. The placement of cannula was confirmed by characteristic auditory change in the Doppler flow sound and pulsatile gush of blood in the arterial cannula after removal of stylet which was considered as the end point.

In this study we monitored for first attempt success, total number of attempts, extra cannula used when first one was damaged during the procedure, extravasations of blood under the skin, hematoma formation and help required in case of failure. Numbers of attempts were counted if the tip of the cannula removed from the skin or new prick was made. If the operator was taking more than 10 min for cannulation then help was sought from experienced operator.

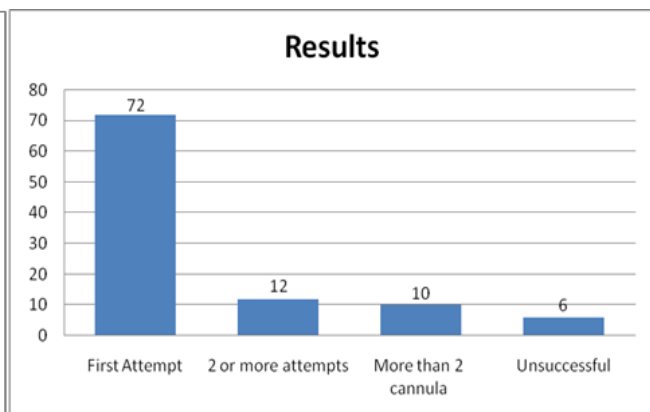
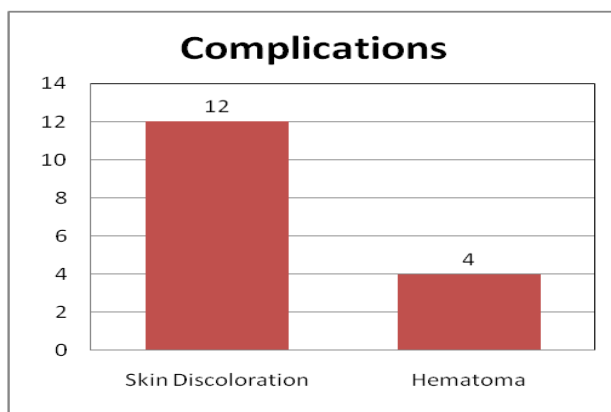
Adverse effects were monitored for 24 hours after arterial cannulation. Patients were monitored for skin discoloration, hematoma formation, thrombus and ischemic changes.

We have used Doppler transducer with 2.5 MHz ½ inch probe.



OBSERVATION AND RESULTS

Out of 100 patients, 68 were male and 32 were female with mean age of $49.51(\pm 16.37)$. In 72 patients cannula was passed in first attempt. 12 patients required 2-3 attempts. In 10 patients though artery was located cannulation was unsuccessful and a different site was cannulated. These 10 patients required more than 2 cannulas as they were damaged during the procedure. In 6 patients neither artery was located satisfactorily nor were we able to cannulate the artery. These patients were cannulated with USG guidance. In patients where either multiple attempts were made or there was failure to cannulate, 12 patients developed skin discoloration, 4 patients developed hematoma.



DISCUSSION

IBP is the gold standard for measurement of blood pressure and is indicated in conditions like shock, inotropic support titration, frequent blood sampling, major surgeries and for diagnostic and interventional procedures (Seidlerová *et al.*, *BMC Cardiovascular Disorders*.2019). However arterial cannulation in shock patients can be challenging. Traditional way of passing arterial cannula has limitations as there may not be palpable pulse. In these conditions the operator may take multiple attempts to pass cannula, causing multiple punctures, hematoma formation and in the worst cases ischemic damages to the limb.(Weiss BM, Gattiker R.1986) (Quist J, Peterfreund RA, Perlmutter GS.1996).

In a conscious patient the repeated pricking can be very painful and agonizing.

Use of ultrasound(USG) and doppler sound assistance are helpful in locating the artery in such difficult cases. Though ultrasound can help in accurate localization of artery, its use requires expertise and training(Hausmann D, Schulte am Esch J, Fischdick G.1981) (Hack WW, Vos A, Okken A.1990). Moreover ultrasound machine is costly, bulky and difficult to shift from one place to another when a machine dedicated to the ICU is not available. In an intervention review study by Marie and comparative study by Ueda concluded that USG is better in first attempt cannulation. However

use of USG guided arterial cannulation requires sound knowledge about the machine, selection of USG probe and identification of diastolic diameter of the artery. While performing USG guided arterial cannulation operator holds the USG probe in one hand, artery cannula in the other hand and watches the screen to insert the cannula. This definitely requires lot of hand, eye orientation and co-ordination. As per the guidelines issued by ultrasound society at least 25 USG guided artery line procedures are required to make the operator competent. (Chinyanga HM, Smith JM.1979) (Murray JP, Brandford HG, Barnes LF, Oh SM, Furman EB. 1984) (K, Sese A.1988) (Fukutome T, Kojiro M, Tanigawa Aouad-Maroun.2016) (Ueda_K, Puangsuvan_S, Hove_MA, Bayman EO.2013).

Foetal heart monitoring Doppler probe can help in tracking the arteries without much expertise. In our study 72 patients could be cannulated in first attempt. This shows the utility of this technique to identify arteries in shock patients. The operators in our study were demonstrated the use of this technique and performed arterial cannulations for the first time using this method. This shows that not much training is required to use the doppler machine. In patients where multiple attempts were required and there was failure to cannulate using this technique we observed that the patients were obese, had edema of the hand or systolic blood pressure less than 60mmHg. These underlying conditions made the tracking of artery by auditory assistance of doppler difficult. These conditions are probably cases where doppler assistance may not help. But as per our study in majority of the cases it was helpful and could be used without much training. The other advantages of hand held foetal doppler machine are its easy availability, low cost compared to USG, small size making it easy to carry from one place to another.

The positive points of our study are the size of study group (100 patients) and that we also monitored the patients for complications following cannulation.

Limitation of the Study

Blinding of the study is not possible.

CONCLUSION

A simple hand held Doppler auscultatory assist device can be used to cannulate the artery in difficult case scenario where conventional palpatory method of arterial cannulations is difficult to perform. The use of the Doppler probe can also help in minimizing the complications associated with the procedure. It can be used to cannulate artery where USG machines are not easily available or operator knowledge is limited.

Conflict of interest – None

Financial support and Funding – None

REFERENCES

- Peterson, L. H., Dripps, R. D., & Risman, G. C. (1949). A method for recording the arterial pressure pulse and blood pressure in man. *American heart journal*, 37(5), 771-782.
- Barr, P. O. (1961). Percutaneous puncture of the radial artery with a multi-purpose Teflon catheter for indwelling use. *Acta Physiologica Scandinavica*, 51(4), 343-347.
- Ivar Seldinger, S. (1953) catheter replacement of the needle in percutaneous arteriography: a new technique. *Acta radiologica* 39:368-76.
- Chatterjee, A., DePriest, K., Blair, R., Bowton, D., & Chin, R. (2010). Results of a survey of blood pressure monitoring by intensivists in critically ill patients: a preliminary study. *Critical care medicine*, 38(12), 2335-2338.
- McGhee, B. H., & Bridges, E. J. (2002). Monitoring arterial blood pressure: what you may not know. *Critical Care Nurse*, 22(2), 60-79.
- Schindler, E., Kowald, B., Suess, H., NIEHAUS-BORQUEZ, B. A. R. B. A. R. A., Tausch, B., & Brecher, A. (2005). Catheterization Of The Radial Or Brachial Artery In Neonates And Infants. *Pediatric Anesthesia*, 15(8), 677-682.
- Brown, A.E., Sweeney, D.B., & Lumley, J. (1969). Percutaneous radial artery cannulation. *Anaesthesia*.24:532-6
- Soderstrom, C. A., Wasserman, D. H., Dunham, C. M., Caplan, E. S., & Cowley, R. A. (1982). Superiority of the femoral artery for monitoring: A prospective study. *The American Journal of Surgery*, 144(3), 309-312.
- Downs, J. B., Rackstein, A. D., Klein, E. F., & Hawkins, I. F. (1973). Hazards of radial-artery catheterization. *Anesthesiology: The Journal of the American Society of Anesthesiologists*, 38(3), 283-286.
- Scheer, B. V., Perel, A., & Pfeiffer, U. J. (2002). Complications of peripheral arterial catheters used for haemodynamic monitoring in anaesthesia and intensive care medicine. *Critical Care*, 6, 199-204.
- Varga, E. Q., Candiotti, K. A., Saltzman, B., Gayer, S., Giquel, J., Castillo-Pedraza, C., ... & Halliday, N. (2013). Evaluation of distal radial artery cross-sectional internal diameter in pediatric patients using ultrasound. *Pediatric Anesthesia*, 23(5), 460-462.
- Seidlerová, et al., (2019). BMC Cardiovascular Disorders 19:150 <https://doi.org/10.1186/s12872-019-1129-9>.
- Weiss, B. M., & Gattiker, R. I. (1986). Complications during and following radial artery cannulation: a prospective study. *Intensive care medicine*, 12(6), 424-428.
- Qvist, J., Peterfreund, R. A., & Perlmutter, G. S. (1996). Transient compartment syndrome of the forearm after attempted radial artery

- cannulation. *Anesthesia & Analgesia*, 83(1), 183-185.
15. Hausmann, D., & Fischdick, G. (1981). Radial artery cannulation--a prospective study on its complication rate by clinical and sonographic evaluation (author's transl). *Anesthesie, Intensivtherapie, Notfallmedizin*, 16(5), 269-273.
 16. Hack, W. W. M., Vos, A., & Okken, A. (1990). Incidence of forearm and hand ischaemia related to radial artery cannulation in newborn infants. *Intensive care medicine*, 16(1), 50-53.
 17. Chinyanga, H. M., & Smith, J. M. (1979). A modified Doppler flow detector probe—an aid to percutaneous radial arterial cannulation in infants and small children. *Anesthesiology: The Journal of the American Society of Anesthesiologists*, 50(3), 256-257.
 18. Morray, J. P., Brandford, H. G., Barnes, L. F., Oh, S. M., & Furman, E. B. (1984). Doppler-assisted radial artery cannulation in infants and children. *Anesthesia & Analgesia*, 63(3), 346-348.
 19. Fukutome, T., Kojiro, M., Tanigawa, K., & Sese, A. (1988). Doppler-Guided “Percutaneous” Radial Artery Cannulation In Small Children. *Anesthesiology: The Journal Of The American Society Of Anesthesiologists*, 69(3), 434-434.
 20. Aouad-Maroun, M., Raphael, C. K., Sayyid, S. K., Farah, F., & Akl, E. A. (2016). Ultrasound-guided arterial cannulation for paediatrics. *Cochrane Database of Systematic Reviews*, (9).
 21. Ueda, K., Puangsuwan, S., Hove, M. A., & Bayman, E. O. (2013). Ultrasound visual image-guided vs Doppler auditory-assisted radial artery cannulation in infants and small children by non-expert anaesthesiologists: a randomized prospective study. *British journal of anaesthesia*, 110(2), 281-286.