

Research Article

Outcome of Provisional Restorations on Basis of Materials and Techniques of Choice: A Systematic Review

Dr. Pooja Garg^{1*}, Dr. Reena Ravi², Dr. Pankaj Ghalaut³

¹Consultant Prosthodontist, ex postgraduate student of PGIDS, Rohtak, Haryana, India

²Consultant Prosthodontist, Ex postgraduate student of PGIDS, Rohtak, Haryana, India

³Professor, Deptt of Prosthodontics, PGIDS, Rohtak Haryana, India

Article History

Received: 11.01.2021

Accepted: 22.01.2021

Published: 07.02.2021

Journal homepage:

<https://www.easpublisher.com>

Quick Response Code



Abstract: The prognosis of fixed restorative procedure is largely dependent upon the quality of the interim treatment restorations pertaining to their importance regarding margin fidelity, function, occlusion and esthetics. The need for accurate provisional restorations has led to the introduction of multitude of materials for the same, with considerable variation in physical, biological and chemical properties. While the choice of the particular material and technique rests solely with the clinician, and varies with the patient's needs. This article highlights the outcome, merits and demerits of provisional restorations fabricated with different materials and different techniques with the sole aim of affording a better understanding and improving clinical performance.

Keywords: Fabrication, Provisional restoration, Acrylic Resins.

Copyright © 2021 The Author(s): This is an open-access article distributed under the terms of the Creative Commons Attribution **4.0 International License (CC BY-NC 4.0)** which permits unrestricted use, distribution, and reproduction in any medium for non-commercial use provided the original author and source are credited.

INTRODUCTION

Process of fabricating the provisional restorations is called temporization. It is a fixed or removable prosthesis, designed to enhance esthetics, stabilization and/ or function for a limited period of time, after which it is to be replaced by a definitive prosthesis [1].

Synonyms: Interim prosthesis/Provisional prosthesis/Temporary Restoration/ Transitional restoration/ Treatment restoration/ Intermediate restoration [2-5].

The term temporization may be a misnomer as these restorations may be expected to last for longer periods. The terms provisional, interim have also been used interchangeably in literature [3]. The term provisional denotes "serving for time being", as a necessary step in providing for the final arrangement [6].

The provisional restorations must satisfy the requirements of pulpal protection, periodontal health, occlusal compatibility [7], maintaining tooth position, protection against fracture, resistance to functional loads, maintaining inter abutment alignment, be easily

contourable, color stable, and have sufficient translucency [8].

Provisional fixed partial dentures (FPDs) are the prototype on which functional, occlusal & esthetic adjustments are made to optimize the definitive prosthesis [7]. During this type of treatment, much information can be gathered about tissue response, occlusion, vertical dimension, esthetics, patient's co-operation and homecare [9].

The basic main requirements /concepts behind the provisional restorations are biological, mechanical & esthetic [10]. The provisional crown protects pulp from thermal and chemical insults after crown preparation & enamel removal during the period between the preparation and final restoration [10]. Maintenance of periodontal health is a requisite of any prosthesis, whether provisional or definitive [3].

Provisional restorations have become a vital diagnostic and assessment tool to evaluate the function, colour, shape, contour, occlusion, periodontal response, implant healing and overall esthetics [11]. These can also be used for extended treatment intervals by providing long term tooth protection and stabilization

during adjunctive periodontal and endodontic treatment procedures [12].

Mechanically, the provisional restorations, during function, must resist functional loads that occur during chewing as well as resist removal forces without fracturing [13]. The fibre reinforcement increased the fracture toughness and flexural strength of provisional restorations [14]. Esthetically critical areas, the provisional restorations must not only provide an initial shade match [11], but also maintain its esthetic appearance over the period of service [15].

The purpose of this study was to conduct a systematic review of the clinical and economic outcomes, as well as beneficial and harmful effects, of provisional restorations fabricated with different materials and different techniques.

- Rationale of provisional restoration [3]
- Protect pulpal tissue and sedate prepared abutments.
 - Protect teeth from dental caries and fracture.
 - Brings psychological confidence to the patient
 - Prevent supraeruption of opposing teeth.
 - Provide comfort and function.
 - Evaluate parallelism of abutments.
 - Provide method for immediately replacing missing teeth.
 - Prevent migration of abutments.
 - Provide an environment conducive to periodontal health.

- Evaluate and reinforce the patient’s oral home care.
- Assist with periodontal therapy by providing visibility and access to surgical sites when removed.
- Provide a matrix for the retention of periodontal surgical dressings.
- Stabilize mobile teeth during periodontal therapy and evaluation.
- Provide anchorage for orthodontic brackets during tooth movement.
- Aid in developing & evaluating an occlusal scheme before definitive treatment
- Allow evaluation of vertical dimension, phonetics, and masticatory function.
- Assist in determining the prognosis of questionable abutments during prosthodontic treatment planning.

MATERIALS AND METHODS

Fixed prosthodontic treatment, whether involving complete or partial coverage and natural tooth or dental implant abutments, common relies on indirect fabrication of definitive prosthesis in the dental laboratory [3]. Over the years many researchers and clinicians have documented and demonstrated numerous method of temporization in different clinical situations. A systematic review was developed following established guidelines.

Methodology included. These have been classified and categorized by many authors.

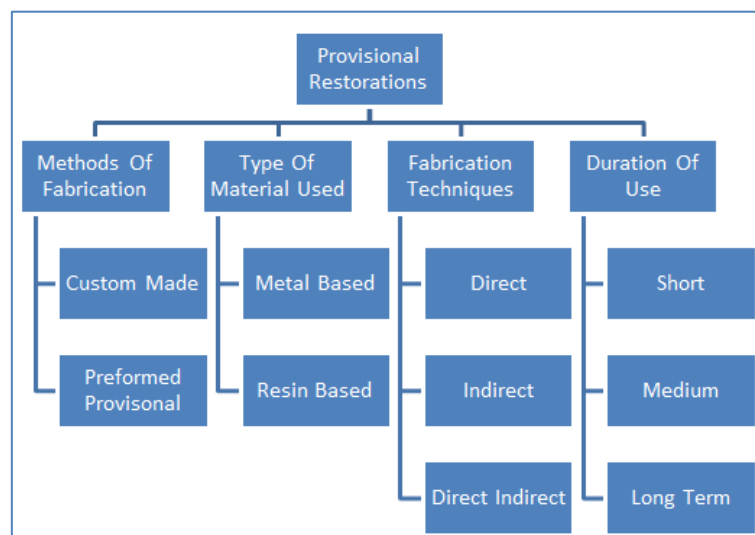


Fig-1: Classification of Provisional Restorations Grouped under different Categories

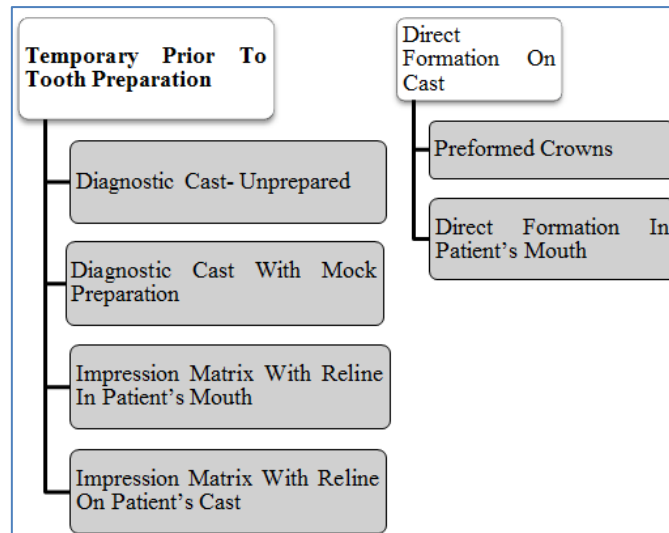


Fig-II: Another Classification of Provisional Restorations

Type of Material Used for Provisional Restoration

Provisional material selection should be based on the strength and weakness of a given material, relative to clinical mandates for specific treatment. The ideal provisional material has not yet been developed. A major problem still to be solved is dimensional changes during solidification. Materials shrink during polymerization that causes marginal discrepancy, especially when direct technique is used. In addition, the resins currently used are exothermic and are not entirely biocompatible [16, 17].

Since the 1930s, different materials have been introduced and used for fabrication of a provisional prosthesis, and great improvements have been made over the past decade [18]. In 1937, heat cured acrylic resin [19] and in 1947, auto polymerizing acrylic resin [20] used for fabrication of provisional prosthesis. Then in 1960s, vinyl polyethylmethacrylate [18] such as Snap and Tim used and in 1969, ethyl imine derivatives [20] such as Suctan was introduced. Composite [4] such as Protemp, Visio Gem and Triad derived in 198

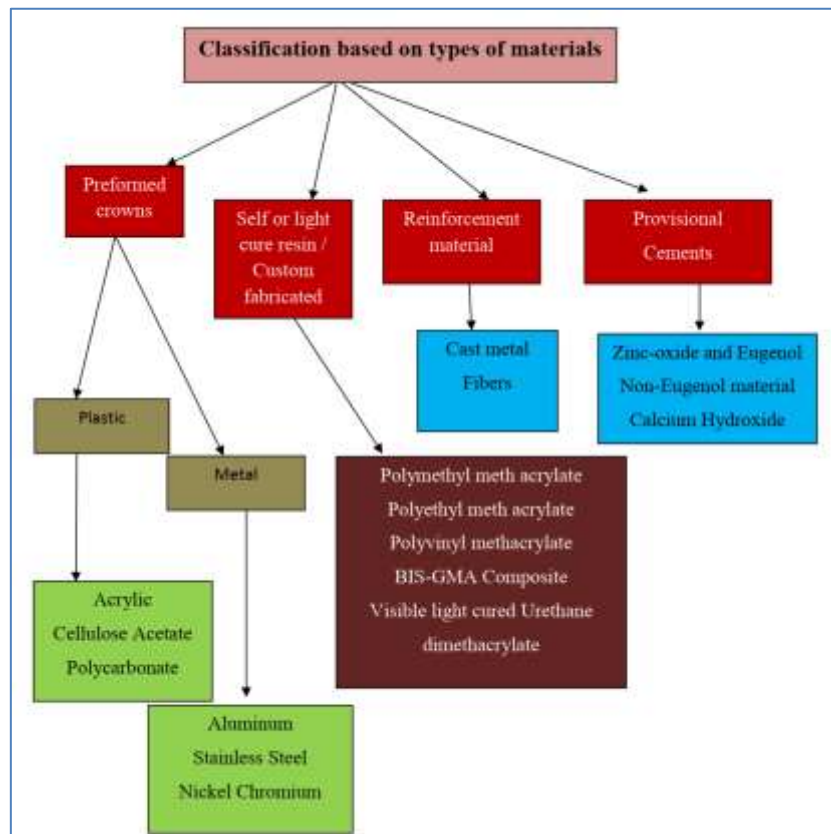


Fig-3: Classification based on types of materials

Methacrylate resins

The literature indicates that polymethyl methacrylate is the preferred material when provisional restorations are made using indirect techniques [3] Plant *et al*. [21] found that the intrapulpal temperature rise associated with the polymerization of methyl methacrylate materials could be up to 5 times that associated with the normal consumption of thermally hot liquid. Ethyl methacrylate may be a better selection for direct interim prosthesis fabrication and is best suited for short-term use relative to methyl methacrylate [22, 23].

Composite

Composite provisional materials encompass a fairly variable category by virtue of the fact that they are chemically comprised of a combination of 2 or more types of material. Most of these materials use bis-acryl resin, a hydrophobic material that is similar to bis-

GMA. Typically these materials use a variety of multifunctional acrylic resin monomers that produce high-density cross linkages during polymerization. These materials are available as autopolymerized, dual (auto/ visible light) polymerized, or visible Light polymerized forms [3].

Visible light-polymerized resin

The visible light polymerized (VLC) materials require the addition of urethane dimethacrylate, a resin whose polymerization is catalyzed with visible light energy and a camphoroquinone/ amine photo initiator [24, 25]. These materials usually incorporate filler such as microfine silica to improve physical properties such as reduced polymerization shrinkage [3]. Unlike methacrylate resins, they do not produce residual free monomers after polymerization, which explains why they exhibit significantly decreased tissue toxicity relative to methacrylate resins [26].

Table-I: Comparison of mechanical and biological properties for fixed provisional resin restorations

Desired properties	PolyMethyl methacrylate	Ethyl methacrylate	Bis-GMA composite	Visible-light polymerized composite
Minimal temperature change	√√	√√√	√√√√	√
Surface hardness	√√√	√	√√	√√√√
Marginal fit	√√√	√√	√√√√	√
Wear resistance	√	√√√	√√√√	√√√√
Transverse strength	√√√√	No value	√√√√	√√√√
Transverse repair strength	√√√√	√	√√	√√√√
Surface roughness & polish ability	√√√	√√√√	√√	√√
Color stability	√√	√	√√√	√√√√
Stain resistnace	√√√	√√√√	√	√

Preformed materials

Preformed provisional crowns or matrices usually consist of tooth-shaped shells of plastic, cellulose acetate, or metal. They are commonly relined with acrylic resin to provide a more custom fit before cementation, but the plastic and metal crown shells can also be cemented directly onto prepared teeth using a stiff luting material following adjustment [27] They are commercially available in various tooth sizes and are usually selected for a particular tooth anatomy. Nonetheless, available sizes and contours are finite which makes the selection process important for clinical success. Compared with custom fabricated restorations, this treatment method is quick to perform but is more subject to abuse and inadequate treatment outcome. This can result in improper fit, contour, or occlusal contact for a provisional restoration [23].

Techniques of fabrication

Many procedures involving a wide variety of materials are available to make satisfactory interim restorations. As new materials are introduced, associated techniques are reported, and thus, there is even more variety. What all the procedures have in

common is the preparation of a mould cavity into which a plastic material is packed [28].

Indirect technique [28]

The technique involves the fabrication of the interim restoration outside the mouth.

- i. On the diagnostic cast, place a selected acrylic tooth on the area of the missing tooth, adjust the occlusion and seal it with the carding wax
- ii. Following this, a silicone putty index is made involving at least one tooth on either side of the abutment teeth.
- iii. Prepare the patient's teeth to receive the planned prosthesis.
- iv. Make a sectional impression of the prepared teeth and the adjacent structures and pour a check cast.
- v. Lubricate the check cast with a petroleum jelly or any suitable separating media, mix the provisional restorative material, and place it in the tissue surface of the index and seat it on the check cast.
- vi. Try in the preformed restoration for its fit on the cast and then intra-orally.

vii. Reline the temporary restoration to perfect the internal fit if necessary.

viii. Finish, polish, and then cement the restoration.




Fig-4: Steps involved in fabrication via indirect technique

Advantages

1. Any esthetic and occlusal changes can be made on articulator.
2. No contact of free monomer with the prepared teeth or gingival which might cause tissue damage and an allergic reaction or sensitization [28, 29].
3. Avoids, subjecting of prepared tooth to the heat evolved from the polymerizing resin.
4. Produces restoration with superior marginal fit.
5. Frees the patient and dentist for a considerable period of time.

6. Reduces the volume of volatile hydrocarbons inhaled by patient

DISADVANTAGES

1. Increased chair side time.
2. Increased number of intermediate steps.

Direct technique [29]

The technique involves the fabrication of the interim restoration inside the mouth.

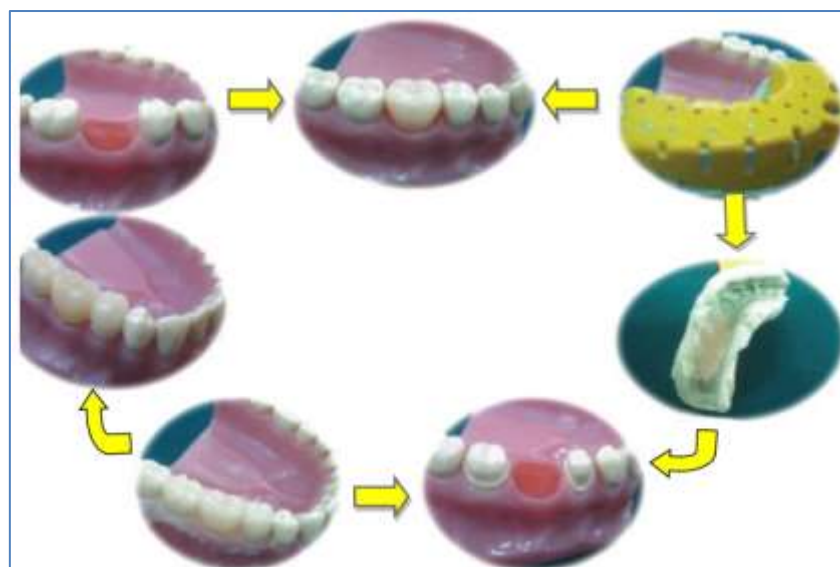


Fig 5: Steps involved in fabrication via direct technique

Direct technique [12]

- a) First an impression is made with silicone rubber and sectional impression tray, the extensions of the impression should be trimmed so that it can be reinserted in the same position in the patient's mouth. If the temporary is for a bridge, the pontic

can be fitted in the patient's mouth prior to making the impression.

- b) Tooth preparation is done and prepared tooth and surrounding tissue is covered with petroleum jelly. The autopolymerizing resin is mixed and loaded into the impression taken earlier.

- c) When the rubbery stage of polymerization (about 2 min in mouth), it is removed from mouth and excess material is removed and again inserted into same place.
- d) After the polymerization is complete, the restoration is removed from the impression soaked in water for 5 min.
- e) Final restoration is cemented with zinc oxide eugenol on the prepared tooth surface.

Advantage

Cheaper and Easier to fabricate

Disadvantage [12]

- 1. Poor marginal adaptation because of polymerization shrinkage.
- 2. Residual monomer causes tissue inflammation.
- 3. Exothermic heat of polymerization causes pulpal damage and patient discomfort

NOTE- Whenever resins are used in the patient's mouth; the temperature rise of polymerization may lead to irreversible pulp damage [30, 3]. Mechanisms of injury include protoplasm coagulation, expansion of the liquid in the dentinal tubules and pulp with increased outward flow from the tubules, vascular injuries and tissue necrosis [32].

According to Zach and Cohen (1965), a temperature rise of 5.5 °C can lead to 15% loss of vitality in the pulp, an 11 °C rise causes about 60% and a 16.6 °C temperature rise causes 100% necrosis of the pulp [33]. The temperature rise may be reduced by employing various cooling techniques like removing the provisional restoration after the initial polymerization of resin; using air/water spray etc [34].

Alginate matrices are best at absorbing the resin exotherm- although temporary should have been removed before the stage of set [35]. A thin insulating layer of petroleum jelly, Vaseline or glycerin can be applied to the tooth structure prior to contact with uncured resin to avoid chemical injury. Many patients are allergic to acrylic resins [36]. Whenever these are used in the patient's mouth, the operator should observe all precautions and careful and thorough history is a must.

Indirect-direct technique [29]

- a) Pour an accurate pre-treatment diagnostic cast from an impression of the unprepared teeth. For FPDs, wax a pontic into the edentulous area of the study cast.

- b) Make an impression using a high-viscosity elastomeric impression material involving at least one tooth each beyond the abutment teeth.
- c) Remove the acrylic tooth and prepare the abutments on mounted diagnostic casts.
- d) Lubricate the prepared diagnostic cast with a petroleum jelly or any suitable separating media, mix the provisional restorative material, and place it in the tissue surface of the index and reseat it on the prepared diagnostic casts.
- e) After the acrylic resin has polymerized, finish the restoration
- f) Prepare the patient's teeth. Try in the preformed restoration. Reline the temporary restoration to perfect the internal fit if required.
- g) Finish, polish and cement the restoration.

Advantage

- 1. Chair time can be reduced, since the provisional shell is fabricated before the patient's appointment.
- 2. In addition, a smaller amount of acrylic resin will polymerize in contact with the prepared abutment that is during reline, resulting in decreased heat generation, chemical exposure, allergic reactions and polymerization shrinkage.

Disadvantage

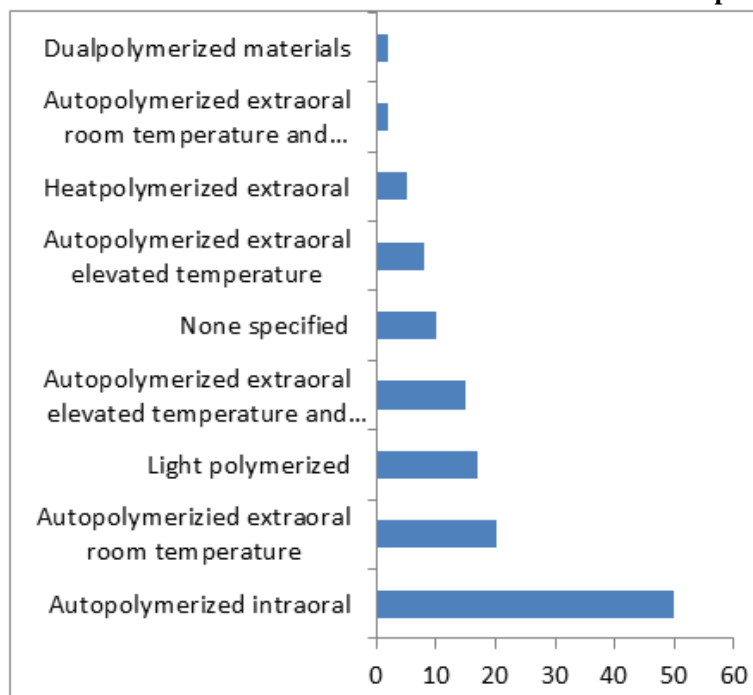
Potential need of a laboratory phase before tooth preparation and the adjustments needed to seat the shell completely on the prepared tooth.

Provisional restoration for post and core restorations [28, 29]

If custom made post and core is planned, the post and core portion can be instantly built and temporary crown can be fabricated on it. If cast post is to be placed in final restoration, the following measures may be taken.

- 1) A ball pin may be placed into the post space and an alginate over impression is made that would pick up the ball pin and then the restoration fabricated on cast.
- 2) Instead of placing ball pin directly into the post space, it may be placed into the impression and the restoration fabricated.
- 3) In the alternative technique, a ball pin may be placed into the post space and restoration fabricated intraorally using resin block technique. A tooth trimmed in form of labial veneer can be used in such cases.

Table-II: Prevalence in literature of clinical fabrication methods for tooth borne provisional restoration.



I. Temporary prior to tooth preparation

The temporary crown or bridge is formed prior to tooth preparation. Even though the final provisional restoration is completed after preparation but the provisionalization procedure are begun prior to tooth preparation.

A. Diagnostic cast – unprepared [37]

A cast on which no tooth preparation has been done is used. The cast is not altered in any form except to attach a pontic to the cast for forming a temporary bridge.

- I. Making a silicon or alginate impression of the altered/unaltered but unprepared diagnostic cast. This impression serves as a matrix which is subsequently relined in the patient’s mouth using self-polymerizing resins.
- II. Following the set, the matrix and temporary crown/bridge is removed.
- III. The temporary crown /bridge is finished, adjusted and cemented in the patient’s mouth.

B. Diagnostic cast with mock preparation

A mock or dummy tooth preparation may be done on the diagnostic cast or its replica using the smoothest, worn out burs or a Bard Parker knife. A shell form of temporary crown/bridge can be prepared on this mock preparation and checked for marginal extensions and occlusal discrepancies on the cast and may be relined in the patient’s mouth following the completion of tooth preparation [4]. These relined temporary restorations should be removed from the patient’s mouth and the margins, axial contours and occlusal inaccuracies should be corrected and they can be finished, polished and cemented.

C. Impression matrix with reline in patient’s mouth [12]- Same as direct technique explained earlier.

D. Impression matrix with reline on patients cast [4]- Same as indirect technique

II. Temporary following tooth preparation

In this group all procedures for temporization are started after the tooth preparation has been completed.

A. Direct formation on cast- Same as indirect technique.

The temporary crown/bridge may be formed by any of the following methods:-

- a) Heat cure acrylic resin: The wax up is done on the model and the temporary crown is prepared in heat cure using traditional lost wax technique [4, 36]
- b) Self-cure acrylic resins may be used to form the temporary crown/bridge on the model in free hand. Strengthened resins: Resins which have been strengthened using various fibers such as carbon fibers, aramid fibers, Kevlar fibers, glass fibers, ultrahigh molecular weight polyethylene fibers can also be used for improving the strength of bridges specially long span bridges and bridges for high stress areas [4, 38].
- c) Metal frameworks can also be used to strengthen the provisional restoration [39].
- d) Composite resins light and dual cure temporary crown forming composite resins

may be used to form temporary crown/bridge on the model [4]

- e) Tin-Silver alloys and Tin – bismuth can be used using traditional wax up, burn out and casting techniques.
- f) Nickel-Chromium alloys: These temporary metal crowns have greatest strength of all temporary crowns and last the longest and cast [4, 39].

B. Preformed Crowns: [4, 39]

Also known as propriety shells. These crown forms may be used for temporization. These are commonly used for crowns as it is difficult to use them for bridges especially long span bridges. The various preformed crowns are-

- Cellulose acetate
- Polycarbonate
- Aluminium shell

Stainless steel crowns the patient's mouth. The size that suits the situation best requiring least amount of adjustment should be used. The choice of technique to be used for each patient depends on the material to be used.

After the appropriate size crown is chosen using the available sizing device the cervical portion of the crown is trimmed and adapted to the margins of the preparation. The crown forms are relined in the patient mouth using self-polymerizing resin, dual-polymerizing resins, visible light-polymerizing resins, Bis-GMA composite resins [4].

C. Direct formation in patient's mouth

Temporary crown forming composite resin can be used for forming a tooth crown directly in the patient's mouth [4]. These resins are light cured, providing complete control to the operator on the setting time. This method can be used for single crowns. However, multiple crown and bridges can also be formed but the method would become tedious to the point of being impractical.

Alternative techniques for direct technique

1. Acrylic resin block technique for direct provisional restorations [28]

A useful though seldom employed method for making provisional restoration is the resin block technique. The interim restoration is fabricated without the use of diagnostic casts and lab processing costs.

Autopolymerizing acrylic resin is used and when set to a doughy consistency; the resin is placed over the abutments and in the region of the pontic. The patient closes in centric occlusion. The resin record is removed and replaced a few times. After polymerization, the restoration is trimmed at margins and axial

contours. The occlusion is adjusted. The insides are relieved with a bur for self-curing resin relining material. After relining the restoration is adjusted and checked for accuracy and luted with temporary cement.

(2) In any of these techniques, instead of building up the entire tooth with autopolymerizing resin, the acrylic tooth can be trimmed in the form of a labial veneer and the rest of the tooth built up with autopolymerizing resin. This tooth that has been trimmed in the shape of a veneer can be either used directly in the patient's mouth and rest of the tooth built up or can be used indirectly on a cast.

(3) Using the existing prosthesis as a provisional restoration: The important principle in such a case is to remove the prosthesis with minimum risk to the natural abutment teeth. Once removed, the prosthesis can be rebuilt to be used as a provisional or temporary prosthesis.

Alternatively, an impression of the existing fixed partial denture may be made before attempting its removal, and this impression may be used to make the temporary restoration by placing it on the master cast that would be made after the tooth preparation.

(4) In cases the patient presents with tooth preparation already being done and without a temporary, the following measures may be undertaken.

(a) To build up the prepared tooth with the carding wax and place an acrylic tooth in the area of missing tooth and take an impression and use it to fabricate the temporary restoration.

(b) To make the impression of the prepared tooth as it is and then score the impression in the form of reverse pontic and also in the area of the prepared tooth in an attempt to duplicate the unprepared tooth.

(c) To use acrylic resin block technique forming direct provisional restoration.

CONCLUSION

This article is prompted by the desire to classify and categorize all methods of provisionalization /temporization in various categories and sub groups. Different techniques have been presented for the efficient fabrication of temporary or provisional restoration with the emphasis on the advantages and disadvantages of temporization. Attention to details in these procedures can be most rewarding to both the patient and the dentist.

REFERENCES

1. Haselton, D. R., Diaz-Arnold, A. M., & Dawson, D. V. (2004). Effect of storage solution on surface roughness of provisional crown and fixed partial denture materials. *Journal of Prosthodontics: Implant, Esthetic and Reconstructive Dentistry*, 13(4), 227-232.
2. Nivedita, S., & Prithviraj, D. R. (2006). A comparative study to evaluate the marginal accuracy of provisional restorations fabricated by

- light polymerized resin and autopolymerized resin: A scanning electron microscope study. *The Journal of Indian Prosthodontic Society*, 6(3), 122.
3. Jamani, K. D., & Fayyad, M. A. (2004). A technique for fabrication of a provisional fixed partial denture for nonparallel abutments. *The Journal of prosthetic dentistry*, 92(6), 584-587.
 4. Burns, D. R., Beck, D. A., & Nelson, S. K. (2003). A review of selected dental literature on contemporary provisional fixed prosthodontic treatment: report of the Committee on Research in Fixed Prosthodontics of the Academy of Fixed Prosthodontics. *The Journal of prosthetic dentistry*, 90(5), 474-497.
 5. Glossary of Prosthodontic Terms. (2006). 8th Edition. J Prosthet Dent 2006.
 6. Rosenstiel, S.F., Land, M.F., & Fuji Moto, J. (2001). Contemporary fixed prosthodontics. Third Edition. Chicago: Mosby Inc. Chapter 15, Provisional Restorations; 380-416.
 7. Baldissara, P., Katsinas, G., Scotti, R. (2004). Use of carbon epoxy frameworks for reinforcing provisional fixed partial dentures. *J Prosthet Dent*, 91:89-92.
 8. Digholkar, S., Madhav, V.N., Palaskar, J. (2016). Evaluation of flexural strength and microhardness of provisional crown and bridge materials fabricated by different methods. *J Indian Prosthodont Soc*, 16(4):328-34.
 9. Kinsel, R.P. (1986). Fabrication of treatment restorations using acrylic resin denture teeth. *J Prosthet Dent*, 56:142-5.
 10. Schwedhelm, E.R. (2006). Direct technique for the fabrication of acrylic provisional restorations. *J Contemp Dental Pract*, 7:10 25.
 11. Jalali, H., Dorriz, H., Hoseinkhezri, F., Razavi, S.F. (2012). In vitro color stability of provisional restorative materials. *Indian journal of dental research*, 23(3):388-9.
 12. Choudhary, M., Nahar, N., Yazdi, S., Choudhary, F., Sultana, A. A. (2015). Fabrication of provisional restoration on freshly prepared tooth: indirect and direct technique. *Bangladesh journal of medical science*, 10(1):59-64.
 13. Powel, D.B., Nicholls, J.I., Youdelis, R.A., Strygler, H. (1994). A comparison of wire and Kevlar reinforced provisional restorations. *Int J Prosthodont*, 7:81-89.
 14. Hamza, T.A., Rosenstiel, S.F., Elhosary, M.M. (2004). The effect of fibre reinforcement on fracture toughness and flexural strength of provisional restorations. *J Prosthet Dent*, 91(3): 258-64.
 15. Doray, P.G., Li, D., Powers, J.M. (2001). Color stability of provisional restorative materials after accelerated aging. *J Prosthodont*, 10:212-8.
 16. Patras, M., Naka, O., Doukoudakis, S., Pissiotis, A. (2012). Management of Provisional Restorations' Deficiencies: A Literature Review. *Journal of Aesthetic and Restorative Dentistry*, 24:26-38.
 17. Glossary of Prosthodontics Terms. (1999). J Prosthet Dent; 81:94
 18. Hunter, R.N. (1983). Construction of accurate acrylic resin provisional restorations. *J Prosthet Dent*, 50:520-1.
 19. Starr, F.C. (1952). Acrylic in jacket and crown and bridge pontics. *J Prosthet Dent*, 2:543-5.
 20. Dahl, B.L., Tronstad, L., Spanbeg, L. (1974). Biological tests of a temporary cement and bridge material. *J Oral Rehabil*, 1:299-309.
 21. Plant, C.G., Jones, D.W., Darvell, B.W. (1974). The heat evolved and temperatures attained during setting of restorative materials. *Br Dent J*, 137:233-8.
 22. Krug, R.S. (1975). Temporary resin crowns and bridges. *Dent Clin North Am*, 19:313-20.
 23. Christensen, G. J. (1996). Provisional restorations for fixed prosthodontics. *J Am Dent Assoc*, 127:249-52.
 24. Gegauff, A.G., Wilkerson, J.J. (1995). Fracture toughness testing of visible light- and chemical-initiated provisional restoration resins. *Int J Prosthodont*, 8:62-8.
 25. Ireland, M.F., Dixon, D.L., Breeding, L.C., Ramp, M.H. (1998). In vitro mechanical property comparison of four resins used for fabrication of provisional fixed restorations. *J Prosthet Dent*, 80:158-62.
 26. Khan, Z., Razavi, R., von, Fraunhofer, J.A. (1988). The physical properties of a visible light-cured temporary fixed partial denture material. *J Prosthet Dent*, 60:543-5.
 27. Lui, J.L., Setcos, J.C. Phillips, R.W. (1986). Temporary restorations: a review. *Oper Dent*, 11:103-10.
 28. Regish, K. M., Sharma, D., & Prithviraj, D. R. (2011). Techniques of fabrication of provisional restoration: an overview. *International journal of dentistry*, 2011.
 29. Shetty, M., Alva, H., & Prasad, A. (2012). Provisional restorations in prosthodontic rehabilitations-concepts, materials and techniques. *Journal of Health and Allied Sciences NU*, 2(02), 72-77.
 30. Young, H. M., Smith, C. T., & Morton, D. (2001). Comparative in vitro evaluation of two provisional restorative materials. *The Journal of prosthetic dentistry*, 85(2), 129-132.
 31. Grajower, R., Shaharbani, S., Kaufaman, E. (1979). Temperature rise in Pulp Chamber during Fabrication of the Temporary Self cure Resin Crowns. *J Prosthet Dent*, 41:5, 535-40.
 32. Singh, R., Tripathi, A., Dhiman, R. K., & Kumar, D. (2015). Intrapulpal thermal changes during direct provisionalization using various autopolymerizing resins: ex-vivo study. *medical journal armed forces india*, 71, S313-S320.
 33. Anusavice, K.J. Phillips' Science of Dental Materials. 11th ed. Saunders: 239e248.

34. Moulding, M. B., & Teplitsky, P. E. (1990). Intrapulpal temperature during direct fabrication of provisional restorations. *International Journal of Prosthodontics*, 3(3).
35. Wassell, R.W., George, G.S., Ingledew, R.P., Stelle, J.G. (2002). Crown and other extracoronal restorations: Provisional restorations. *British dental journal*, 192(11):619-21.
36. Antonoff, S. J., & Levine, H. (1981). Fabricating an acrylic resin temporary fixed prosthesis for an allergic patient. *The Journal of prosthetic dentistry*, 45(6), 678-679.
37. Dalvit, D.L., Parker, M.H., Cameron, S.M. (2002). Quick chairside diagnostic wax-up. *J Prosthet Dent*, 87:581-2.
38. Pfeiffer, P., Grube, L. (2003). In vitro resistance of reinforced interim fixed partial dentures. *J Prosthet Dent*, 89:170-4.
39. Binkley, C.J., Irvin, P.T. (1987). Reinforced heat-processed acrylic resin provisional restorations. *J Prosthet Dent*, 57:689-92.

Cite This Article: Pooja Garg *et al* (2021). Outcome of Provisional Restorations on Basis of Materials and Techniques of Choice: A Systematic Review. *EAS J Dent Oral Med*, 3(1), 6-15.