

Original Research Article

What about Infants with Clefts? A 7-Years Descriptive Cross Sectional Study in Tunisian Pediatric Dentistry Departement

Emna Bourguiba^{1,2*}, Jihene Zaroui^{1,3}, Mohamed Ali Chemli^{1,4}¹Faculty of Dentistry of Monastir, Pediatric Dentistry Department, Dento- Facial Biological and Clinical Approach Laboratory, LR12ES10, 5019 Monastir, Tunisia, University of Monastir, Tunisia²DDS, Department of Pediatric Dentistry and Prevention, La Rabta Hospital, 1007, Tunis³DDS, Associate professor, Department of Pediatric Dentistry and Prevention, La Rabta Hospital, 1007 Tunis⁴DDS, Professor, Department of Pediatric Dentistry and Prevention, La Rabta Hospital, 1007 Tunis**Article History**

Received: 17.07.2021

Accepted: 19.08.2021

Published: 24.08.2021

Journal homepage:<https://www.easpublisher.com>**Quick Response Code**

Abstract: The aim of the present communication was to describe characteristics of oro-facial clefts as well as oro-dental clefts' sequel in new borns admitted in pediatric dentistry outpatient. The secondary endpoint was to expose contribution of pediatric dentist in the multidisciplinary management of oro-facial clefts and to propose a regular program of follow-up that have been recently adopted in our department of exercise. We performed a descriptive cross-sectional study between 2013 and 2020. Age at diagnosis, gender, type of cleft and other associated malformations were enrolled for all patients. Means and frequencies were calculated by Excell software. One hundred and fourteen patients were enrolled. Diagnosis of clefts was made at birth in all patients. Newborns presented cleft lip in 0.88% (n=1), lip-palate in 41.2% (n=47), lip -palate -velar in 14.15% (n=16), palate in 31% (n=19), soft palate in 7.08% (n=8) and hard and soft palate in 15% (n=17). 9% of newborns, admitted in our department of exercise, had a follow-up. Malocclusions, (17%) / (n=20), were the most frequent sequel observed in our cohort. Oro-facial clefts represent severe malformations requiring multidisciplinary support. Pediatric dentist must be implicated as soon as cleft diagnosis was made. His input helps reducing severe oral damages. His role is later extended to next stages of life in order to intercept and correct consequent malocclusion as early as possible.

Keywords: Oro-facial clefts, pediatric dentist, management, Maxillary expansion, Surgery.

Copyright © 2021 The Author(s): This is an open-access article distributed under the terms of the Creative Commons Attribution **4.0 International License (CC BY-NC 4.0)** which permits unrestricted use, distribution, and reproduction in any medium for non-commercial use provided the original author and source are credited.

INTRODUCTION

Oro-facial clefts are the most common congenital malformation of the face [1]. Its worldwide prevalence is 1 in 700 live births and close to 1 in 2500 in African populations [1]. To our knowledge, there were no previous descriptive studies in pediatric dentistry sections about this congenital defect in spite of continuous and expanding care, since the advent of pediatric dentistry in Tunisia in the 80 s.

Pediatric dentist is considered a part of multidisciplinary team approach of those infants [2, 3]. A specialized dental care from birth until 15 years old is recommended for infants clefts, and it will depend on type of clefts, associated syndromes, number of surgical cleft repair, sequels diagnosed and regular follow-up [1, 3, 4].

We aim to describe characteristics of oro-facial clefts in new borns as well as oro-dental clefts' sequelae's distribution in pediatric dentistry outpatient. Our second endpoint is to propose an oro-dental schedule for infants with clefts from birth until 15 YO in order to regularize their dental management in synchronization with surgical management.

MATERIAL AND METHODS

We performed a descriptive cross-sectional study between 2013 and 2020 in the department of pediatric dentistry at Rabta university hospital in Tunis.

Clinical charts of infants with oro-facial clefts were extracted from hospital archives. Data concerning patients' names, age at diagnosis of the clefts, age at consultation in pediatric dentistry department, gender, number and type of clefts, laterality and completeness of clefts syndrome associated, short and long term

follow-up, clefts sequel, age of sequel's diagnosis and management of cleft sequel were enrolled. Means and frequencies were calculated by excel software.

RESULTS AND DISCUSSION

One hundred and fourteen patients were enrolled. The prevalence of infants with clefts in the pediatric dentistry outpatient is 0.62 %. Diagnosis of clefts was made at birth in all patients (12 days +/- delta = (26 days)/median 6 [1days →7 months]). Boys were affected more than girls with sex ratio 1:3. Newborns presented complete clefts in 26.54% (n=30), incomplete clefts in 1.76 % (n=2), bilateral clefts in 13.27% (n=15) and unilateral clefts in 25 % (n=28).

Types of clefts were lip in 0.88% (n=1), lip-palate in (n=47), palate in 31% (n=19), soft palate in 7.08 % (n= 8) and hard and soft palate in 15 % (n=17).

Non syndromic orofacial clefts presented 85.96 % (n=99) whereas syndromic form was noted in 14.03% (n=15). Pierre Robin syndrome was the most prevalent one (40 %). Consanguineous marriage, twin pregnancy and risky pregnancy are some of the prenatal characteristics revealed in our study.

Only seven point eighty nine percent (7.89 %) of newborns with clefts had a regular follow-up, and twenty six point thirty one percent (26.31 %) of infants were lately reviewed with oro-dental clefts 'squeal. Endognathia (62 %), agenesis of maxillary lateral incisor (5 %), mobility of premaxilia (10 %), dental dilacerations (14 %), and early childhood caries (9 %) were types of squeals observed in infants after surgical cleft repair.

Oro-facial clefts is the most common congenital human malformation [5, 6]. It is due to a failure of fusion of maxillary and medial nasal prominences or between the palatal processes resulting in clefts of varying extent , unilaterally or bilaterally [5].

Our study has shown two descriptive aspects of oro-facial clefts. It has, firstly, proven its distribution in a part of natal Tunisian population and, secondly, described clefts' squeals' distribution in the pediatric dentistry population.

In one hand, our study has included a significant sample in comparison with international ones [7, 8]. Our study, in concordance with Mossey *et al*. 2009 [9], has confirmed that this defect is more prevalent in boys than in girls , and that complete unilateral clefts of lip and palate is the most frequent type diagnosed at birth [10].

Syndromic and non-syndromic orofacial clefts is a classification widely used in literature [6, 11]. In fact, some facial malformations like Down syndrome,

Pierre Robin syndrome may be associated to orofacial clefts as proven in our study [12–14]. Genetic factors and chromosomal aberrations may be hidden behind [1]. Besides, some maternal environmental factors (nutritional deficiencies, exposure to X-ray , maternal illness, tobacco) can lead to a non-syndromic oro-facial cleft form [6, 11]. In our study, data concerning maternal history and genetics aberrations were not included because they were not detailed during clinical interview.

In the other hand, we have concluded that, in north of Tunisia; there is a late management in pediatric dentistry section after surgical cleft repair. That may be due to a lack of mother's sensibilization, to the absence of a standardized oro-dental care program in such cases and to a long period of surgical cleft repair and medical impairment especially in cases of syndromic forms. So that a wide range of squeals are observed in clefts area at different ages of diagnosis. Malocclusions were the most frequent squeal observed in our cohort. That may be due to fibrous scars induced by early surgical cleft repair ,as long as late interceptive and orthodontic treatment [15, 16].

Besides, dental anomalies of form and number are frequently observed especially in the maxillary lateral incisors site [5,10,17]. That was explained by a deficiency of blood and mesenchyme support on the cleft area [5, 18].

CBCT is recommended in the European and American guidelines for the rehabilitation of lip and palate clefts [19]. That gave the rise to the use of CBCT images for the examination of dental anomalies in clefts side and on pre and post- grafting expansion when there is a clinical benefit and rational doses are used [17,19].

A long-term multidisciplinary management, from birth till adulthood, is required in cases of oro-facial clefts [3, 20]. It can be helpful in ensuring that the child undergoes proper specialty evaluations and in determining the most suitable and coordinated treatment options [1]. A specialized dental team support is then needed [1, 3]. The pediatric dentist provides general oral hygiene and dental advice , monitor dental development and jaw growth by insuring a regular program of follow-up and management, once standardized with surgeon [3, 16, 20, 21]. That one may normalize the inter-arch relationship, guarantee a normal midfacial growth and may avoid unnecessary surgical procedures [16, 20]. Functional therapy, pre-grafting expansion, slow and rapid maxillary expansion have shown a considerable results in those cases [13, 19, 22, 23].

In fact, the lack of a clear and normalized oro-dental follow-up program, in spite of a multidisciplinary approach from birth till adulthood in our department of

exercise, may have led to a high percentage of clefts' sequels and late dental management.

For the best management of children born with a cleft, a tertiary prevention program has been adopted for functional rehabilitation, growth monitoring and protection of the child's psychology. For those reasons, we have proposed, in our department of exercise, an oro-dental schedule, for infants born with clefts, from birth by restoring sucking function, and during childhood and adolescence by various prosthetic and interceptive appliances.

The diagram below (figure 1) summarizes the supply of pediatric dentist in the multidisciplinary management of oro-facial clefts after being normalized with surgeons.

New regular programs of follow-up have been adopted in the department of pediatric dentistry at Rabta university hospital is materialized by figure 2.

A future prospective study following the proposed program of follow-up is recommended. It needs to be generalized in all over the country. So that the prevalence will be determined in comparison with total live births and results will be more significant.

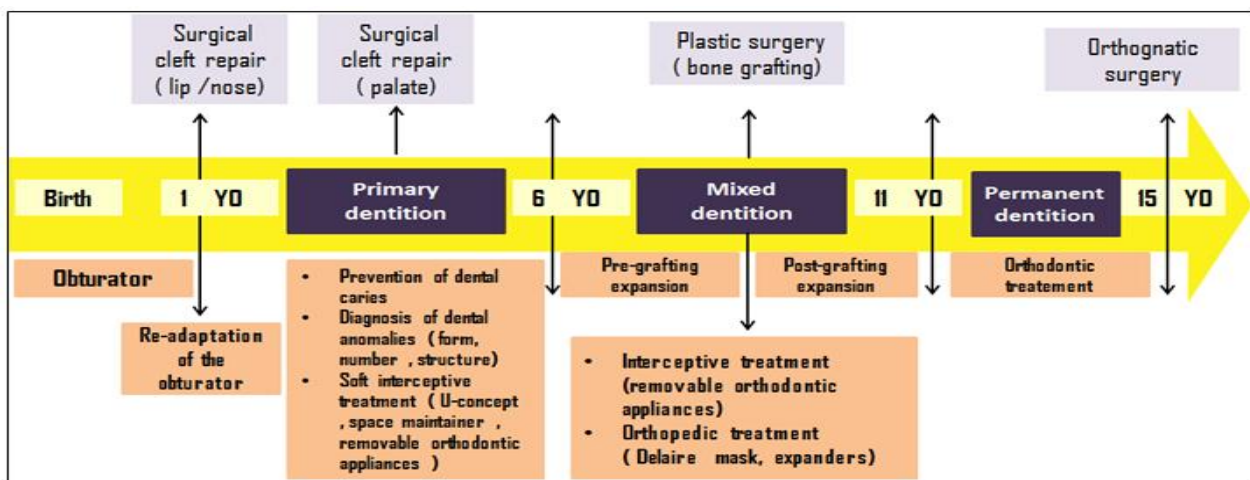


Fig-1: Oro-dental management of clefts adopted in pediatric dentistry section in Tunisia complementary to surgical approach

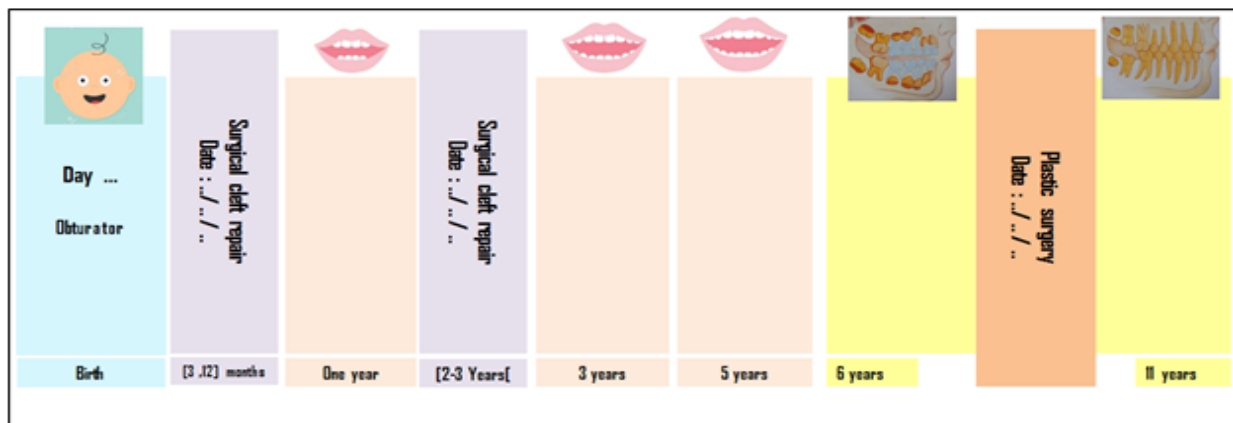


Fig-2: Schedule card for regular follow-up adopted in pediatric dentistry section in Tunisia

CONCLUSION

Prenatal diagnosis of clefts and early management may help to initiate treatment on time and on a proper manner. From a surgical point of view, the ideal timing of cleft repair is not yet known, but pre-surgical treatment plan is necessary in order to reduce scars extension and to achieve more aesthetic results. Dental team support starts from re-establishing sucking function and continue during temporary, mixed and

permanent dentition, in order to normalize facial growth and prevent profound squeals.

REFERENCES

1. Crockett, D. J., & Goudy, S. L. (2014). Cleft lip and palate. *Facial Plast Surg Clin North Am*, 22(4), 573-86.
2. Yang, C. J., Pan, X. G., Qian, Y. F., & Wang, G. M. (2012). Impact of rapid maxillary expansion in unilateral cleft lip and palate patients after

- secondary alveolar bone grafting: review and case report. *Oral surgery, oral medicine, oral pathology and oral radiology*, 114(1), e25-e30.
3. Berkowitz, S. (Ed.). (2006). *Cleft lip and palate: Diagnosis and management*. Springer Science & Business Media.
 4. Woo, A. S. (2017). Evidence-based medicine: cleft palate. *Plastic and reconstructive surgery*, 139(1), 191e-203e.
 5. Pegelow, M., Alqadi, N., & Karsten, A. L. A. (2012). The prevalence of various dental characteristics in the primary and mixed dentition in patients born with non-syndromic unilateral cleft lip with or without cleft palate. *The European Journal of Orthodontics*, 34(5), 561-570.
 6. Eshete, M., Butali, A., Abate, F., Hailu, T., Hailu, A., Degu, S., ... & Deressa, W. (2020). The role of environmental factors in the etiology of nonsyndromic orofacial clefts. *Journal of Craniofacial Surgery*, 31(1), 113-116.
 7. Panamonta, V., Pradubwong, S., Panamonta, M., & Chowchuen, B. (2015). Global birth prevalence of orofacial clefts: a systematic review. *J Med Assoc Thai*, 98(Suppl 7), S11-21.
 8. https://www.orpha.net/consor/cgi-bin/OC_Exp.php?lng=FR&Expert=141291.
 9. Mossey, P. A., Little, J., Munger, R. G., Dixon, M. J., & Shaw, W. C. (2009). Cleft lip and palate. *The Lancet*, 374(9703), 1773-1785.
 10. Jamilian, A., Lucchese, A., Darnahal, A., Kamali, Z., & Perillo, L. (2016). Cleft sidedness and congenitally missing teeth in patients with cleft lip and palate patients. *Progress in orthodontics*, 17(1), 1-4.
 11. Jia, Z. L., Shi, B., Chen, C. H., Shi, J. Y., Wu, J., & Xu, X. (2011). Maternal malnutrition, environmental exposure during pregnancy and the risk of non-syndromic orofacial clefts. *Oral diseases*, 17(6), 584-589.
 12. Stoll, C., Dott, B., Alembik, Y., & Roth, M. P. (2015). Associated congenital anomalies among cases with Down syndrome. *European journal of medical genetics*, 58(12), 674-680.
 13. Hsieh, S. T., & Woo, A. S. (2019). Pierre Robin Sequence. *Clinics in plastic surgery*, 46(2), 249-259.
 14. Baxter, D., Shanks, A.L. (2021). Pierre Robin Syndrome. In: StatPearls [Internet]. Treasure Island (FL): StatPearls Publishing; 2021 [cited 2021 May 16]. Available from: <http://www.ncbi.nlm.nih.gov/books/NBK562213/>
 15. Botticelli, S., Kùseler, A., Marcusson, A., Mølsted, K., Nørholt, S. E., Cattaneo, P. M., & Pedersen, T. K. (2020). Do infant cleft dimensions have an influence on occlusal relations? A subgroup analysis within an RCT of primary surgery in patients with unilateral cleft lip and palate. *The Cleft Palate-Craniofacial Journal*, 57(3), 378-388.
 16. Cassi, D., Di Blasio, A., Gandolfini, M., Magnifico, M., Pellegrino, F., & Piancino, M. G. (2017). Dentoalveolar effects of early orthodontic treatment in patients with cleft lip and palate. *The Journal of craniofacial surgery*, 28(8), 2021.
 17. Berniczei-Roykó, Á., Tappe, J. H., Krinner, A., Gredes, T., Végh, A., Gábor, K., ... & Botzenhart, U. U. (2016). Radiographic study of the prevalence and distribution of hypodontia associated with unilateral and bilateral cleft lip and palate in a Hungarian population. *Medical science monitor: international medical journal of experimental and clinical research*, 22, 3868.
 18. Kim, N. Y., & Baek, S. H. (2006). Cleft sidedness and congenitally missing or malformed permanent maxillary lateral incisors in Korean patients with unilateral cleft lip and alveolus or unilateral cleft lip and palate. *American journal of orthodontics and dentofacial orthopedics*, 130(6), 752-758.
 19. de Almeida, A. M., Ozawa, T. O., de Medeiros Alves, A. C., Janson, G., Lauris, J. R. P., Ioshida, M. S. Y., & Garib, D. G. (2017). Slow versus rapid maxillary expansion in bilateral cleft lip and palate: a CBCT randomized clinical trial. *Clinical oral investigations*, 21(5), 1789-1799.
 20. Farronato, G., Kairyte, L., Giannini, L., Galbiati, G., & Maspero, C. (2014). How various surgical protocols of the unilateral cleft lip and palate influence the facial growth and possible orthodontic problems? Which is the best timing of lip, palate and alveolus repair? Literature review. *Stomatologija*, 16(2), 53-60.
 21. Xu, X., Kwon, H. J., Shi, B., Zheng, Q., Yin, H., & Li, C. (2015). Influence of different palate repair protocols on facial growth in unilateral complete cleft lip and palate. *Journal of Cranio-Maxillofacial Surgery*, 43(1), 43-47.
 22. de Medeiros Alves, A. C., Janson, G., Mcnamara Jr, J. A., Lauris, J. R. P., & Garib, D. G. (2020). Maxillary expander with differential opening vs Hyrax expander: a randomized clinical trial. *American Journal of Orthodontics and Dentofacial Orthopedics*, 157(1), 7-18.
 23. de Medeiros Alves, A. C., Garib, D. G., Janson, G., de Almeida, A. M., & Calil, L. R. (2016). Analysis of the dentoalveolar effects of slow and rapid maxillary expansion in complete bilateral cleft lip and palate patients: a randomized clinical trial. *Clinical oral investigations*, 20(7), 1837-1847.

Cite This Article: Emna Bourguiba et al. What about Infants with Clefts? A 7-Years Descriptive Cross Sectional Study in Tunisian Pediatric Dentistry Departement. *EAS J Dent Oral Med*, 3(4), 105-108.