

## Case Report

## Indirect Approach for Personalized Transfer in Emergence Profile Recording for Anterior Implants

Hanan Boukhris<sup>1\*</sup>, Ameni Thabet<sup>1</sup>, Hajer Zidani<sup>1</sup>, Sabrine Jlassi<sup>1</sup>, Hayet Hajjami<sup>1</sup>, Souha Ben Youssef<sup>2</sup><sup>1</sup>Department of Fixed Prosthodontics, University Hospital Farhat Hached Sousse, LR12SP10, University of Monastir, Tunisia<sup>2</sup>Department of oral surgery, University Hospital Farhat Hached Sousse, LR12SP10, University of Monastir, Tunisia

## Article History

Received: 12.02.2025

Accepted: 17.03.2025

Published: 21.03.2025

## Journal homepage:

<https://www.easpublisher.com>

## Quick Response Code



**Abstract: Background:** The emergence profile of dental implants is essential for the aesthetic and functional success of implant restorations, particularly in the anterior sector. Proper management of the emergence profile contributes to natural-looking restorations and healthy peri-implant soft tissues. **Objective:** This case report aims to demonstrate the use of the conventional technique with personalized transfer to record the emergence profile for an implant restoration in the anterior sector. **Methods:** A 36-year-old female patient, H.A., sought treatment following the extraction of tooth 21. A provisional prosthesis was placed to guide soft tissue healing, and after osseointegration, the emergence profile was recorded using the conventional technique with a personalized transfer method. High- and low-viscosity silicone, flowable resin, and light-curing techniques were used to accurately capture and transfer the emergence profile from the provisional prosthesis to the implant model. **Results:** The use of the personalized transfer technique allowed for a precise replication of the provisional prosthesis's emergence profile, ensuring a natural appearance and integration of the final implant restoration. The procedure led to a favorable aesthetic and functional outcome, demonstrating the effectiveness of this technique in anterior implant restorations. **Conclusion:** The conventional technique with personalized transfer is a reliable and effective method for recording the emergence profile, particularly in the anterior sector where aesthetic demands are high. This technique ensures optimal soft tissue management and enhances the integration of the final prosthesis, offering predictable, functional, and aesthetically pleasing results.

**Keywords:** Emergence profile, dental implants, anterior sector, provisional prosthesis, personalized transfer, implant restoration, soft tissue management, aesthetic outcome, functional integration, conventional technique.

**Copyright © 2025 The Author(s):** This is an open-access article distributed under the terms of the Creative Commons Attribution **4.0 International License (CC BY-NC 4.0)** which permits unrestricted use, distribution, and reproduction in any medium for non-commercial use provided the original author and source are credited.

## INTRODUCTION

The emergence profile of dental implants plays a crucial role in both the aesthetic and functional success of implant restorations, particularly in the anterior sector where esthetics is of paramount importance. The emergence profile refers to the shape and contour of the implant restoration as it transitions from the implant platform to the surrounding soft tissues. A well-designed emergence profile helps ensure optimal integration of the implant with the gingiva, contributing to both the visual appeal of the restoration and its long-term health and stability [1].

In the anterior region, achieving an ideal emergence profile is particularly challenging due to the

esthetic demands and the delicate nature of the surrounding tissues. Poorly managed emergence profiles can lead to soft tissue recessions, aesthetic failures, or complications such as peri-implantitis, making it essential to carefully plan and execute the procedure for recording the emergence profile [2, 3].

This case report aims to illustrate the process of recording the emergence profile in the anterior sector using a conventional technique combined with a personalized transfer method. By describing the procedure in detail, this report seeks to highlight how this approach can optimize the aesthetics, function, and integration of the definitive prosthesis. Furthermore, it will demonstrate how a systematic and precise technique

\*Corresponding Author: Hanan Boukhris

Department of Fixed Prosthodontics, University Hospital Farhat Hached Sousse, LR12SP10, University of Monastir, Tunisia

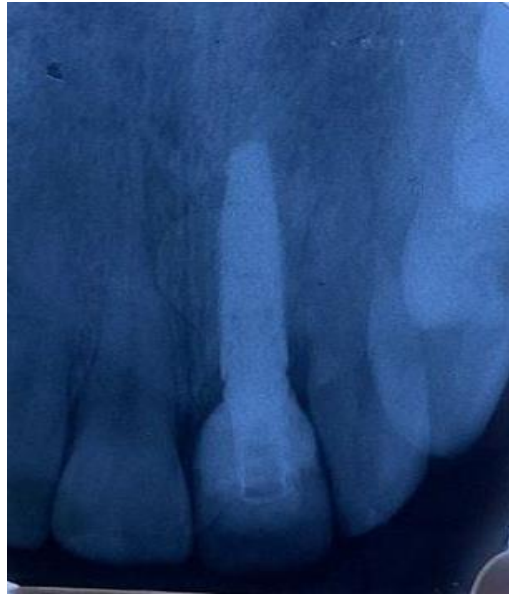can enhance the overall outcomes of implant therapy, ensuring both the longevity and the esthetic success of the restoration.

## CASE REPORT

A 36-year-old female patient, H.A., in generally good health, presented for treatment following the extraction of tooth 21. In order to preserve the adjacent structures and minimize invasiveness, an implant solution was selected. The approach focused on using the

least destructive method possible for optimal results. A provisional prosthesis was placed to guide the healing of the peri-implant tissues, ensuring proper soft tissue management during the osseointegration phase.

After successful osseointegration, the next crucial step was to record the emergence profile, which would play a significant role in achieving the desired aesthetic and functional outcome for the final prosthesis (Fig 1).



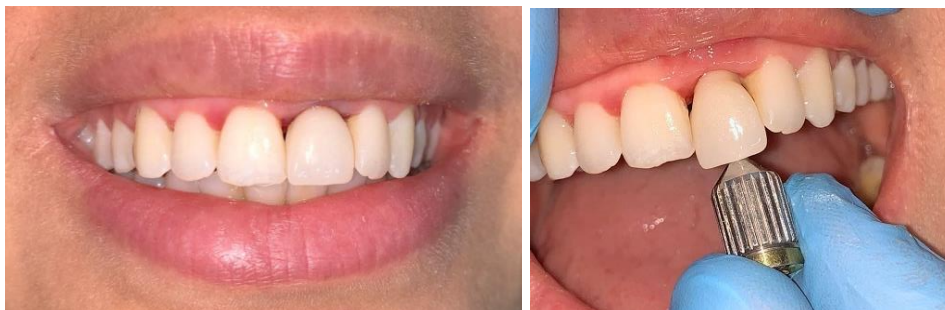**Fig 1: Control X-ray after complete osteointegration of the implant**

The **conventional technique** was chosen for this purpose, utilizing a personalized transfer method to capture the profile accurately. Here are the detailed steps followed in the case:

### Step-by-Step Procedure

#### 1. Aesthetic and Functional Validation of the Provisional Prosthesis

Before proceeding with the impression, the provisional prosthesis was carefully assessed for both aesthetic and functional purposes. The morphology of the provisional prosthesis was evaluated in the patient's mouth to ensure it was aligned with the natural dental arch. Any necessary corrections were made to the provisional prosthesis to optimize the soft tissue contouring and ensure proper healing of the peri-implant tissues (Fig 2).



**Fig 2(a-b): Removal of the screw-retained provisional prosthesis on the implant**

#### 2. Materials and Equipment Used

- **Perforated impression tray** to capture the shape of the implant area.
- **Pick-up impression transfer** to accurately record the implant position and emergence profile.
- **High- and low-viscosity silicone** for capturing detailed impressions of the soft tissues.

- **Flowable resin** to stabilize and secure the transfer during the procedure.
- **Light-curing lamp** for polymerizing the resin.
- **Implant analog** and **implant-specific screwdriver** for securing the transfer and provisional prosthesis.

### 3. Step-by-Step Emergence Profile Recording

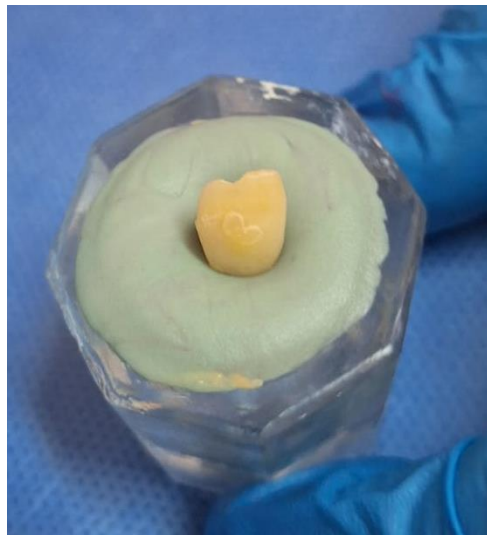
The provisional prosthesis was securely attached to the implant analog using the implant-specific screwdriver, ensuring accurate reproduction of the implant's position for precise recording of the emergence profile (Fig 3).



**Fig 3: Fixing the Provisional Prosthesis onto the Implant Analog**

A plastic cylinder was filled with high-viscosity silicone, poured to a height at least equal to the combined height of the implant analog and provisional prosthesis. This allowed for a complete impression of the implant's position and surrounding tissue contours. The analog-

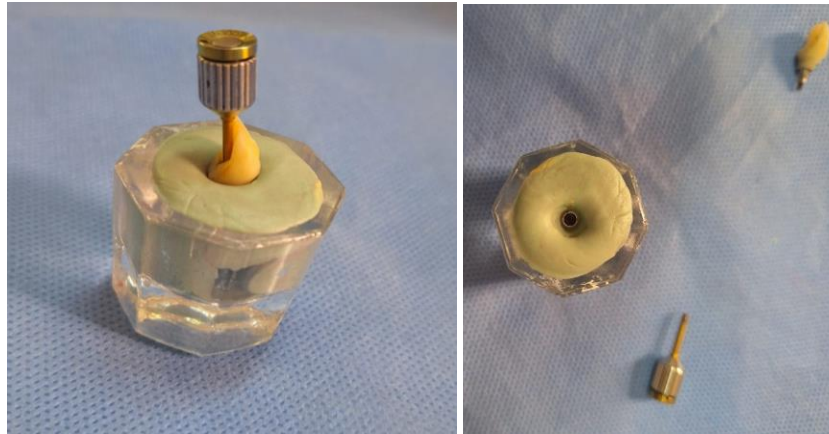provisional prosthesis assembly was then gently immersed into the silicone impression material, stopping halfway up the crown to capture both the implant's position and the emergence profile of the provisional restoration (Fig 4).



**Fig 4: Immersion of the Analog-Provisional Prosthesis Assembly into the Silicone**

After polymerization of the silicone, the vestibular surface was identified, and the provisional

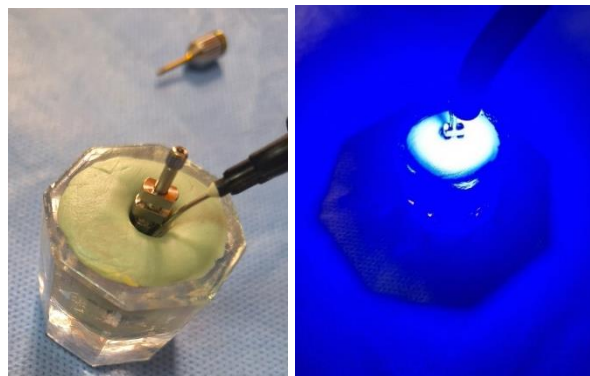
prosthesis was disconnected from the implant analog (Fig 5).



**Fig 5(a-b): After complete polymerization of the silicone, disconnection of the provisional crown**

A custom transfer impression was then attached to the implant analog, facilitating the accurate transfer of the emergence profile from the provisional prosthesis.

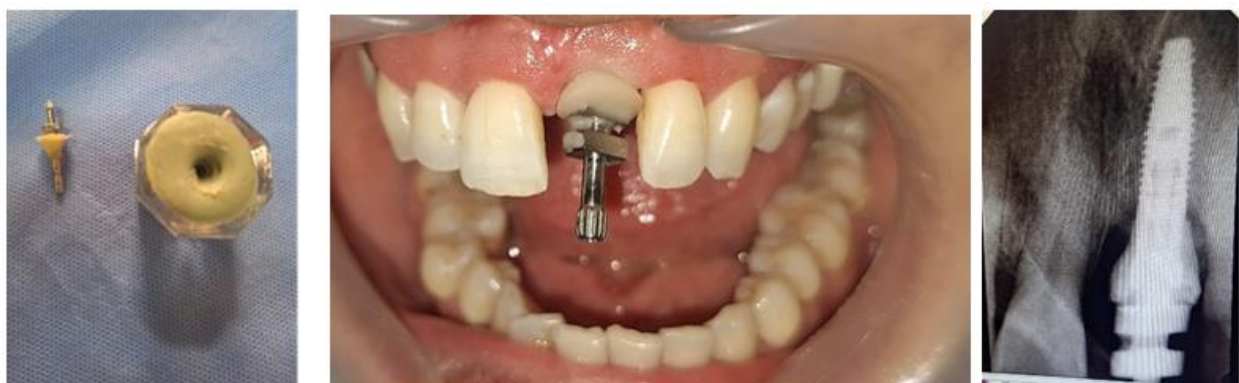Flowable resin was applied to the prosthetic cradle and light-cured to secure the transfer in place (Fig 6).



**Fig 6(a-b): Adding Flowable Resin and Light Curing**

Finally, the customized transfer was unscrewed from the impression and placed in the patient's mouth,

connecting it securely to the implant interface to ensure the emergence profile was accurately replicated (Fig 7).

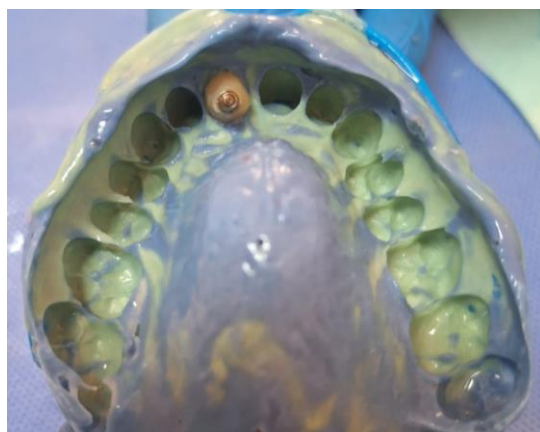

**Fig 7 (a-b-c): Placement of the custom transfer in place and control X-ray of its adaptation**

#### 4. Final Impression with Open Tray Technique (Pick-up Method)

The final impression was taken using the open tray (pick-up) technique, where the customized transfer recorded the emergence profile from the provisional

prosthesis onto the working model. This technique ensures that the profile captured during the provisional phase is accurately reproduced in the final prosthesis, achieving a perfect aesthetic result (Fig 8).



**Fig 8: Final Impression with Open Tray Technique**

## DISCUSSION

The emergence profile of a dental implant is one of the most critical factors in determining the final aesthetic and functional success of implant therapy. It influences not only the appearance of the restoration but also the long-term health of the surrounding soft tissues. In the anterior sector, where aesthetics are paramount, achieving an optimal emergence profile is especially important to ensure that the implant restoration mimics the natural tooth's contours and maintains healthy peri-implant tissues. This is particularly crucial for patients who are seeking functional restorations that also blend seamlessly into their smile [3].

The conventional method for recording the emergence profile, as demonstrated in this case report, is based on the use of a personalized transfer. This technique is widely regarded for its precision in replicating the contours of the provisional prosthesis onto the implant analog. By using a customized impression transfer, the technique ensures that the provisional restoration's emergence profile is captured accurately and transferred to the final prosthesis. The personalized transfer method allows the clinician to guide the peri-implant tissue healing and contouring in a manner that mirrors the shape and appearance of the natural tooth [4].

In this case, the provisional prosthesis served as a guiding tool, facilitating the appropriate soft tissue healing and the desired emergence profile. The use of silicone materials, along with a flowable resin and light-curing processes, ensured that the impression captured the delicate details of the implant's emergence. The transfer technique allowed for a customized fit, providing a robust base for the definitive prosthesis. This is critical in achieving an aesthetically pleasing result and in ensuring proper tissue integration, which is vital for long-term success [5].

One of the major advantages of the conventional technique with personalized transfer is its ability to control and optimize the soft tissue healing process. By shaping the emergence profile with a

provisional restoration and recording it accurately for the definitive prosthesis, the clinician can predictably manage the soft tissue contours around the implant. The procedure helps prevent tissue loss or unnatural tissue contours that can occur with less precise methods. This approach reduces the risk of complications such as peri-implantitis or soft tissue recession, which can compromise both function and aesthetics [5].

Additionally, the precision achieved through this technique allows for better prosthesis integration. The final restoration can be fabricated with a more accurate emergence profile, improving both the fit and function of the prosthesis. As a result, patients experience enhanced comfort, improved esthetics, and a lower likelihood of complications post-placement [6].

However, the proper validation of the provisional prosthesis in the mouth before recording the emergence profile is essential to ensure the aesthetic outcome matches the patient's expectations. Any discrepancies in the provisional restoration could result in an inaccurate emergence profile, which may affect the final prosthesis.

Despite these challenges, the personalized transfer method remains an essential and reliable tool in implantology, particularly in cases requiring high aesthetic demands, such as in the anterior sector. It provides an effective solution for clinicians to manage soft tissue contours and achieve optimal results for their patients.

## CONCLUSION

Accurate recording of the emergence profile is essential for the aesthetic and functional success of implant restorations, particularly in the anterior sector. While faster digital methods exist, the conventional technique with personalized transfer remains a reliable approach for capturing the emergence profile, ensuring optimal integration with the surrounding soft tissues and natural dentition. This method allows for controlled shaping of the peri-implant tissues, leading to a better aesthetic outcome. It also minimizes the risk of

complications while promoting the integration of the final prosthesis. However, digital techniques offer a quicker, more precise alternative, reducing procedure time while still achieving similar results.

## REFERENCES

1. Ntounis, A., & Petropoulou, A. (2010). A technique for managing and accurate registration of periimplant soft tissues. *The Journal of Prosthetic Dentistry*, *104*(4), 276-279.
2. Wittneben, J. G., Buser, D., Belser, U. C., & Brägger, U. (2013). Peri-implant soft tissue conditioning with provisional restorations in the esthetic zone: the dynamic compression technique. *International Journal of Periodontics & Restorative Dentistry*, *33*(4), 447-455.
3. Hegyi, K. E. (2016). Direct method of registering periimplant soft tissue forms for implant-supported fixed dental prostheses. *The Journal of Prosthetic Dentistry*, *115*(3), 267-270.
4. Papadopoulos, I., Pozidi, G., Goussias, H., & Kourtis, S. (2014). Transferring the emergence profile from the provisional to the final restoration. *Journal of esthetic and restorative dentistry*, *26*(3), 154-161.
5. Spyropoulou, P. E., Razzoog, M., & Sierraalta, M. (2009). Restoring implants in the esthetic zone after sculpting and capturing the periimplant tissues in rest position: a clinical report. *The Journal of Prosthetic Dentistry*, *102*(6), 345-347.
6. Figueras-Alvarez, O., & Real-Voltas, F. (2015). A method of temporarily preserving the emergence profile in implant dentistry. *Journal of Prosthetic Dentistry*, *113*(5), 491-492.

---

**Cite This Article:** Hanan Boukhris, Ameni Thabet, Hajer Zidani, Sabrine Jlassi, Hayet Hajjami, Souha Ben Youssef (2025). Indirect Approach for Personalized Transfer in Emergence Profile Recording for Anterior Implants. *EAS J Dent Oral Med*, *7*(2), 87-92.

---