

Original Research Article

Megaurethra and Hypospadias

António Gentil Martins, MD, Prof., FICS, OLY*

Department of Pediatric Surgery, Children's Hospital de D. Estefânia (Hospital of Lisbon's Central Hospitals), Lisbon, Portugal

Department of Childrens and Adolescents Oncology - Portuguese Cancer Institute Francisco Gentil, Lisbon, Portugal

Article History

Received: 27.09.2021

Accepted: 08.11.2021

Published: 12.11.2021

Journal homepage:<https://www.easpublisher.com>**Quick Response Code**

Abstract: It is described as an original technique developed hoping to correct an extremely rare penile anomaly of “mega-urethra and hypospadias” appearing in the context of a “Triad Syndrome” anomaly. A progressive folding of the penile shaft together with partial excision of penile skin and correction of the hypospadias with tubularization of the urethral mucosa and obtaining a quite satisfactory end result (both aesthetic and functional).

Keywords: Hypospadias; Triad Syndrome; Mega-Urethra.

Copyright © 2021 The Author(s): This is an open-access article distributed under the terms of the Creative Commons Attribution **4.0 International License (CC BY-NC 4.0)** which permits unrestricted use, distribution, and reproduction in any medium for non-commercial use provided the original author and source are credited.

INTRODUCTION AND OBJECTIVES

The Triad Syndrome is a well-known congenital syndrome, although infrequent. Nevertheless we have not found in the literature its association with mega-urethra and hypospadias, which thus required that an original approach had to be used.

MATERIAL AND METHODS

Six years old child, caucasian, suffering from the “Triad Syndrome” (megabladder, ureters and pelvis, cryptorchidism and hypoplasia of the anterior abdominal muscles) and having also posterior urethral valves. His penis was long and flaccid, with wrinkled skin and almost filiform corpora (with a diameter of almost 2 cm) ending in a balanic type of hypospadias.

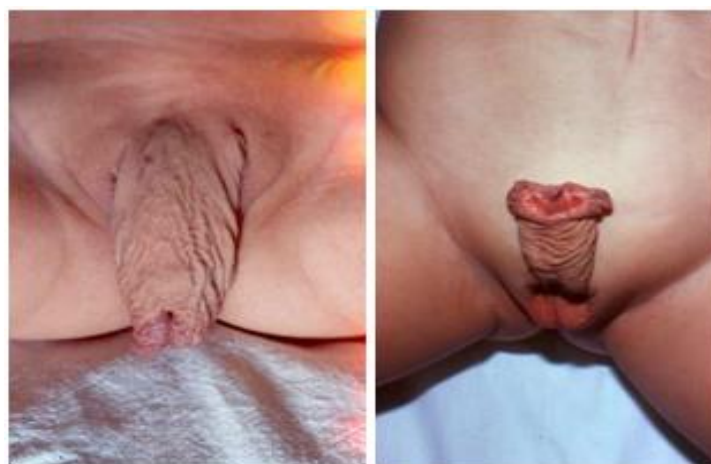

Fig-1: Aspect of the penis and aspect of the ventral penile surface, with rugged skin and wide meatus

Initially endoscopic resection of the posterior urethral valves was performed.

Surgical Technique

To correct the mega-urethra a coronal incision was performed, with posterior retraction of all the penile skin till its base.

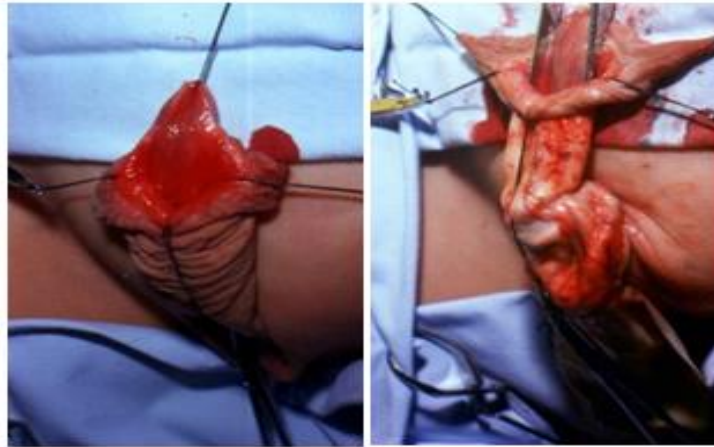


Fig-2: Aspect of the meatus, with stitches at the glands and preputial borders and enormous meatus within a flaccid penile skin.

Introducing a dilator it was easy to see the enormous wideness of the urethra. Then followed the resection of a large portion of the excessively large

ventral urethral mucosa, which was then tubularized till the end of the glans (already with the desired “normal” caliber).

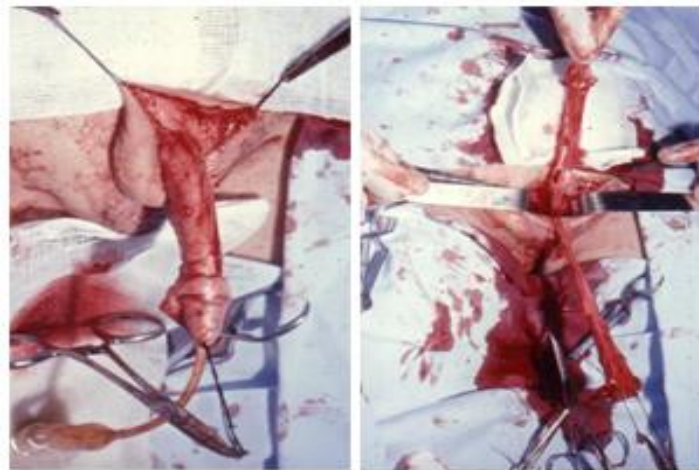


Fig-3: Penile skin retracted till the pubic area showing the long and flaccid penile shaft and excision of a ventral area on the penile ventral mucosa

Then the resection of a longitudinal strip of the excessive dorsal penile skin, all along the penis was performed, the shaft being completely uncovered.

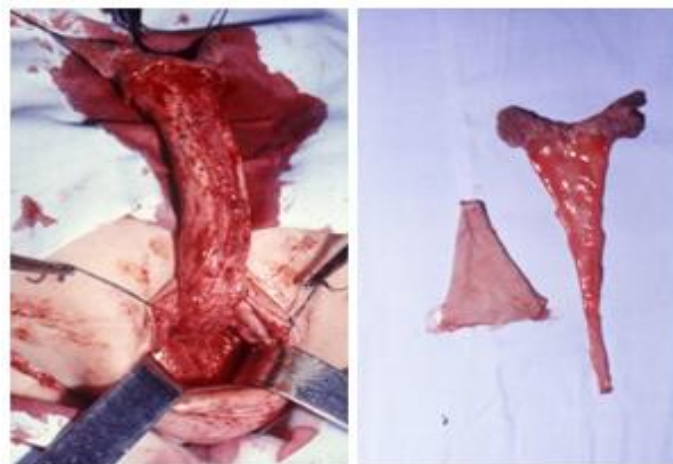


Fig-4: Penile skin completely retracted and fragments of the penile mucosa and skin resulting from the required partial excisions

That was followed by a radiated plication of the corpora cavernosa in 6 longitudinal columns (at 1,3,5,7,6,11 “hours”) in such a way as to preserve the vessels and nerves (medial and dorsal), thus markedly reducing the length of the penis (around one half), as well as increasing its diameter and consistency.

The retracted penile skin is then replaced, with excision of the now existent redundant skin (considering the obtained reduction in the penile length

and taking into account that already part of the dorsal skin had already been removed longitudinally).

The skin was longitudinally sutured dorsally after removing its excess. So, the skin suture remained on the opposite side to the ventral suture of the urethra, thus avoiding the possibility of the appearance of a fistula (the most frequent complication in the treatment of hypospadias).

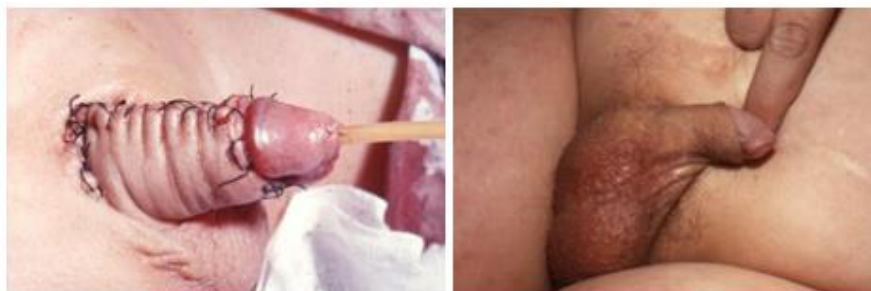

Fig-5: Sutures completed on the dorsal side and coronal sulcus of the penis and global postoperative appearance of the penis as if it had had only routine circumcision

Suprapubic drainage was kept for 12 days. Later the patient had also partial cystectomy, remodeling of the ureters and bilateral orchidopexy

Disclosure

- Conflict of interest (Please disclose all relevant and potential Conflict of interest as described in 4. ETHICAL CONSIDERATION in this guideline)
- Approval of the research protocol by an Institutional Review Board- N/A
- Informed Consent - N/A
- Registry and the Registration No. of the study/trial - N/A
- Animal Studies - N/A

DISCUSSION

This way the child remained with an almost normal penis, with a fair erection capacity and urinating normally.

Being a very rare and complex situation and not knowing of any described technique for its global correction, one had to simply rely on general rules of therapy to conceive how to deal with the malformation.

Disclaimer: The paper is a single author piece and presents no conflict of interests

Funding: No funding was received for this research

Consent: Patient not identified (consent not required)

REFERENCE

Pure original work.

No references: Never seen described

Cite This Article: António Gentil Martins (2021). Megaurethra and Hypospadias. *East African Scholars J Med Surg*, 3(11), 229-231.