

## Case Report

## Palmar Hyperhidrosis – Our Experience of a Rare Recurrent Hyperhidrosis of the Palm Following Endoscopic Thoracic Sympathectomy: A Case Report

Dr. Mahesh Chikkachannappa<sup>1\*</sup>, Dr. Farooq<sup>2</sup><sup>1</sup>MS (General Surgery) Aster CMI hospital, Bengaluru, India<sup>2</sup>Consultant surgeon, Aster CMI hospital, Bengaluru, India**Article History**

Received: 20.07.2021

Accepted: 25.08.2021

Published: 29.08.2021

**Journal homepage:**<https://www.easpublisher.com>**Quick Response Code**

**Abstract:** Primary or essential hyperhidrosis is a disorder characterized by excessive, chronic, sweating acquired during rest, unrelated to the need of heat loss of the body. It can affect one or more areas of the body, occurring predominantly in the hands, armpits, feet, head and also in the inguinal region. Palmar hyperhidrosis is a condition that has important consequences on the quality of life of individuals, causing social embarrassment and difficulties in school and professional environments. There are a variety of treatments available and the individual choice of the best option for each patient can help in improving their quality of life. Endoscopic thoracic sympathectomy is a safe and effective method used in the management of hyperhidrosis of the palms after all other non surgical modalities have been tried.

**Keywords:** Primary hyperhidrosis, Endoscopic thoracic sympathectomy.

**Copyright © 2021 The Author(s):** This is an open-access article distributed under the terms of the Creative Commons Attribution **4.0 International License (CC BY-NC 4.0)** which permits unrestricted use, distribution, and reproduction in any medium for non-commercial use provided the original author and source are credited.

### INTRODUCTION

Primary or essential hyperhidrosis is a disorder characterized by excessive, chronic, sweating acquired during rest, unrelated to the need of heat loss of the body. It can affect one or more areas of the body, occurring predominantly in the hands, armpits, feet, head and also in the inguinal region [1-3].

The prevalence of primary hyperhidrosis (PH), according to the literature, ranges from 1% to 3%. It occurs in all seasons, including winter. In situations of stress, anxiety, fear and nervousness, there is worsening of symptoms. PH nomenclature is related to the anatomical locations: face and scalp (craniofacial hyperhidrosis), palmar region (palmar hyperhidrosis), armpits (axillary hyperhidrosis), inguinal region (inguinal hyperhidrosis) and plantar regions (plantar hyperhidrosis) [4, 5].

It affects men and women, although there is a false impression of predominance among female due to increased demand for treatment by women. Clinical recognition usually occurs until the third decade of life, usually before 25 years, and may be earlier in individuals with palmar and axillary hyperhidrosis, who manifest the symptoms in childhood and adolescence. In addition, higher prevalence was reported in Japanese than in the Western population [6, 7].

27 year old gentle man Fredrick (name changed) a civil engineer by profession came to my

Outpatient department during the peak pandemic last year (June 2020) with debilitating complaints of excessive sweating of both palms he was so annoyed with his condition and was at the verge of leaving the job as his job demands lots of writing and drawing.

He has undergone endoscopic thoracic bilateral sympathectomy in January 2020 but his condition had remained the same. After thoroughly examining him I diagnosed that his problem of palmar hyperhidrosis persisted and he needed help. A second/redo thoracic sympathectomy surgery is very risky and we may not be able to help him and sometimes can be harmful due to adhesions of the lung parenchyma to the chest wall.

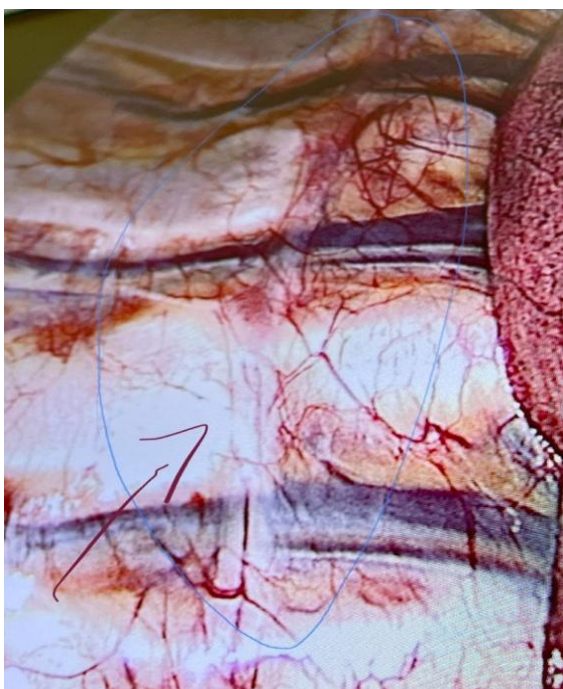
In view of the ongoing pandemic and the high risk involved in another thoracoscopy I counselled the patient to try conservative approaches before we settled down to surgical method, I referred him to our Anaesthesia colleague Dr Arunkumar who is specialised in pain management, Fredrick was put on a regular conservative medications and non-invasive treatment which helped him to a certain extent.

After few months Fredrick again came back with much more symptoms and he was adamant that he needs some permanent solution for his agony and insisted on a relook surgery.

After a detailed discussion and consultation with our pain specialist and a thorough counselling

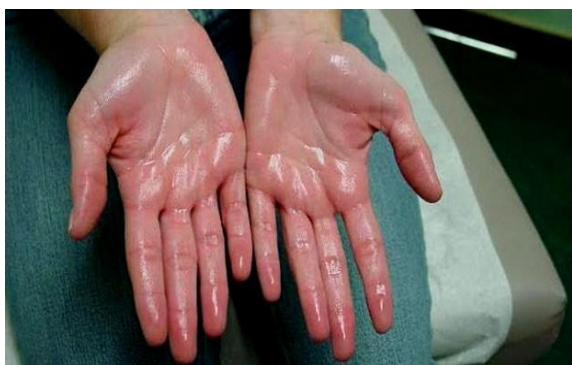secession with patient and his brothers, Fredrick was planned for a diagnostic thoracoscopy.

A CECT chest was done to have an overview of the inside of the thoracic cavity. After a thorough evaluation patient was planned for a Bilateral diagnostic thoracoscopy for our surprise there were no adhesions and the sympathetic chain was intact both sides. We completed the sympetectomy and took the nerve on both sided for confirmatory biopsy.



Postoperatively patient's symptoms had disappeared and he was extremely happy and in his own words "it was a new beginning" for him. He was overwhelmed with the results of the surgery and is under follow-up since last 10 months.

Excessive, uncontrollable sweating of the hands or palms is called palmar hyperhidrosis. This medical condition is an extremely stressful, embarrassing, and confidence-wrecking problem. From ruined paperwork to slippery handshakes, sweaty palms can negatively impact your social life, education, and career.



Research shows that nearly 5% of the world's population suffers from excessive sweating or hyperhidrosis. Of course no one's hyperhidrosis is exactly the same. Some people fill their shoes with sweat, some have dripping no-handshakes-please palms, some sweat through their shirts, others sweat through their jeans, Regardless of whether you sweat dramatically on your head or, we know the embarrassment, anxiety, and crippling effects on the individuals.

- For palmar hyperhidrosis, a low grade of involvement would be a moist palmar surface without visible droplets of perspiration. If palmar sweating extends toward the fingertips, the condition can be considered moderate, and if sweat drips off the palm and reaches all the fingertips, it is severe. Severity of sweating of other focal areas (craniofacial, buttocks, back, and groin, under the breasts) may best be determined by patient descriptions if not visible during the time of the exam.

A quantitative approach to assessing severity is gravimetric measurement, which can be done on the palm and in the axilla. It is important to note that while gravimetric measurement is sometimes still utilized in clinical trials (with debatable reliability), it is not - and need not - be part of routine clinical practice.

### Hyperhidrosis Diagnosis

There are two types of hyperhidrosis (Hh): primary and secondary. Secondary Hh is sweating that is caused by or is a symptom of another underlying medical condition or is a side effect of a medication. Ruling out secondary hyperhidrosis is the first step in Hh management. After this has been done, a diagnosis of primary (or idiopathic) Hh can be diagnosed. Primary Hh usually begins during childhood or adolescence. Because of stigma, shame, embarrassment, and/or a common belief that nothing can be done, most sufferers wait 10 years or more before asking for help. Patients with primary Hh usually do not sweat excessively during sleep. If your patient sweats only when asleep, consider secondary Hh and look for an underlying cause. If the sweating is problematic both day and night, a combination of primary and secondary hyperhidrosis is possible. For a primary Hh diagnosis, look for excessive sweating symptoms or episodes (2 or more per week) that started 6+ months ago and appear to be chronic. Most sufferers will experience episodes of varying frequency, length and degree. Extreme, uncontrollable sweating will likely not be continuous or constant for primary Hh patients. Most sufferers will experience episodes of varying frequency, length and degree. 2/3rds of primary Hh sufferers indicate other family members have Hh, too. Physicians should keep in mind, however, that due to potential stigma and shame associated with the condition, family members

may not talk about it and may keep it hidden from each other.

### Hyperhidrosis Treatment Overview

1. Topical Therapy.
2. Systemic Therapy.
3. Botulinum Toxin Type A.
4. Surgical Treatment.

In addition to medical treatments, there are many high-tech products on the market to help you manage excessive sweating symptoms and the day-to-day hassles that excessive sweating causes. Older treatments such as antiperspirants and iontophoresis have been improved. Relatively new treatments, like mira Dry, Botox injections, and lasers have started giving relief to those who never thought they'd find it. The newest addition is Qbrexza®, a topical anticholinergic medication self-applied at home using a medicated wipe. There are many ayurvedic treatments also available for hyperhidrosis. Due to side effects, oral medications may not be recommended as a long-term solution, but they certainly have their place when treating excessive sweating on large parts of the body, when multiple body areas are affected, or as a short-term solution during a special event (such as a presentation at work or an important family function.) Underarm surgeries, such as liposuction, for excessive underarm sweating are being refined, but less invasive treatments should still be considered first.

### Endoscopic thoracic sympathectomy (ETS)

ETS surgery, although heavily advertised, is reserved for certain severe cases of palmar hyperhidrosis (excessive sweating of the palms) that have not responded to any other treatment options or to combinations of treatments. Before considering ETS treatment, physicians and their patients must fully consider and discuss the real risks of permanent damage and side effects including compensatory sweating. After all other treatments have been tried, adjusted for individual circumstances, and still found to be ineffective, surgical treatment for excessive sweating may be an option considered. There are a few different types of surgery that may be used to treat hyperhidrosis. The most invasive of these is endoscopic thoracic sympathectomy. During ETS surgery, surgeons attempt to interrupt the transmission of nerve signals from the spinal column to the sweat glands and to thus prevent these nerve signals from "turning on" the sweat glands.

The procedure is performed with the patient under general anaesthesia. It is done by laparoscopic method. ETS is most often used to treat severely sweaty palms, sometimes the combination of sweaty palms and

sweaty underarms, and rarely facial flushing and sweating, but it is major surgery (even though it's called 'minimally invasive').

## CONCLUSION

Palmar hyperhidrosis is a condition that has important consequences on the quality of life of individuals, causing social embarrassment and difficulties in school and professional environments. There are a variety of treatments available and the individual choice of the best option for each patient can help in improving their quality of life. Endoscopic thoracic sympathectomy is a safe and effective method used in the management of hyperhidrosis of the palms after all other non surgical modalities have been tried.

## REFERENCES

1. De Campos, J. R. M., Kauffman, P., de Campos Werebe, E., Andrade Filho, L. O., Kusniek, S., Wolosker, N., & Jatene, F. B. (2003). Quality of life, before and after thoracic sympathectomy: report on 378 operated patients. *The Annals of thoracic surgery*, 76(3), 886-891.
2. Hornberger, J., Grimes, K., Naumann, M., Glaser, D. A., Lowe, N. J., Naver, H., ... & Stolman, L. P. (2004). Recognition, diagnosis, and treatment of primary focal hyperhidrosis. *Journal of the American Academy of Dermatology*, 51(2), 274-286.
3. Eisenach, J. H., Atkinson, J. L., & Fealey, R. D. (2005, May). Hyperhidrosis: evolving therapies for a well-established phenomenon. In *Mayo Clinic Proceedings* (Vol. 80, No. 5, pp. 657-666). Elsevier.
4. Wörle, B., Rappich, S., Heckmann, M. (2007). Definition and treatment of primary hyperhidrosis. *J Dtsch Dermatol Ges*, 5; 625-8.]
5. Vetrugno, R., Liguori, R., Cortelli, P., & Montagna, P. (2003). Sympathetic skin response. *Clinical autonomic research*, 13(4), 256-270.
6. Karimian-Teherani, D., Panhofer, P., Ringhofer, C., Jakesz, R., Prager, M., Zacherl, J., ... & Neumayer, C. (2009). New epidemiological aspects of patients with severe hyperhidrosis presenting for sympathetic surgery. *Journal of the European Academy of Dermatology and Venereology: JEADV*, 23(6), 651-655.
7. Cloward, R. B. (1957). Treatment of hyperhidrosis palmaris (sweaty hands). A familial disease in Japanese. *Hawaii Med J*, 16, 381-387.

---

**Cite This Article:** Mahesh Chikkachannappa & Farooq (2021). Palmar Hyperhidrosis – Our Experience of a Rare Recurrent Hyperhidrosis of the Palm Following Endoscopic Thoracic Sympathectomy: A Case Report. *East African Scholars J Med Surg*, 3(8), 146-148.