

Original Research Article

A Study of Difficulties and Complications Encountered in Patients with Pseudoexfoliation Syndrome Undergoing Manual Small Incision Cataract Surgery (MSICS)

Apeksha Raghunath^{1*}, O. K. Radhakrishnan¹, Aakriti Sharma²¹M.D., Department of Ophthalmology, Professor, Dr. D. Y. Patil Medical College and Research Hospital (Dr D Y Patil Vidyapeeth University), Pune, 411018, India²M.D., Department of Ophthalmology, Postgraduate Resident, Dr. D. Y. Patil Medical College and Research Hospital (Dr. D. Y. Patil Vidyapeeth University), Pune, 411018, India**Article History**

Received: 14.02.2022

Accepted: 20.03.2022

Published: 19.06.2022

Journal homepage:<https://www.easpublisher.com>**Quick Response Code**

Abstract: Pseudoexfoliation syndrome (PEX) is a systemic age-related disorder that is characterised by abnormal production of fibrillar extracellular matrix material and its deposition in tissues of the eye and other systemic tissues. They are classically seen as deposits on the anterior lens capsule as dandruff-like white powdery residue. The material deposits in all anterior segment structures including iris, pupillary margins, ciliary body, corneal endothelium, zonules and anterior capsule of lens. In the eye, these deposits cause deviancy from normal structure and function, resulting in poor pupil dilatation, zonular weakness, changes in corneal endothelium, secondary glaucoma and nuclear cataract formation. These changes caused in the eye due to Pseudoexfoliation Syndrome can be a challenge for a surgeon doing routine cataract extraction and intraocular lens implantation in such patients, as these manifestations of PEX can prove to be obstacles during the surgery and cause post operative complications. The surgeon also has to keep in mind associated secondary glaucoma during management of such a case. Thus visual outcome could be compromised.

Keywords: Pseudoexfoliation Syndrome, Cataract surgery, Preoperative complications, Intraoperative complications, Postoperative complications, MSICS.

Copyright © 2022 The Author(s): This is an open-access article distributed under the terms of the Creative Commons Attribution 4.0 International License (CC BY-NC 4.0) which permits unrestricted use, distribution, and reproduction in any medium for non-commercial use provided the original author and source are credited.

1. INTRODUCTION

There are 45 million blind people on the planet, with 12 million of them living in India [1]. The most prevalent cause of blindness is a cataract (62.6 percent), with surgical complications accounting for a tiny percentage (1.2 percent) [2]. According to the National Blindness Survey, the prevalence of blindness is 8% in people over the age of 50 [3]. Cataract causes 62.6 percent of all blindness, impacting 9-12 million people who are bilaterally blind. Every year in India, an estimated 20 lakh new instances of cataract are added to the load. Unoperated cataract was found in 58 percent of people aged 60 in north India (95 percent class interval, 56–60) and 53 percent of people aged 60 in south India (95 percent class interval, 51–55) p-value = 0.01 [4].

PEX is found all over the world, with prevalence rates ranging from 10% to 20% of the general population over the age of 60 [5]. In India,

hospital-based research has found a prevalence rate of 1.8 to 7.4 percent in persons over 45 years old [6, 7].

Lindberg, a Finnish ophthalmologist, was the first to report pseudoexfoliation syndrome in 1917. Georgiana Dvorak-Theobald, an eye pathologist, coined the phrase "Pseudoexfoliation Syndrome." Pseudoexfoliation syndrome is a systemic microfibrilopathy caused by the slow deposition of white fluffy amyloid-like proteinaceous material in the eye, which targets ocular tissues. The anterior chamber and its angle, trabecular mesh work, anterior surface of the iris, anterior capsule of the lens, and corneal endothelium are all frequent places for it to deposit. To distinguish it from actual exfoliation, which is caused by heat or infrared-related changes in the anterior lens capsule, it is referred to as "Pseudoexfoliation."

The most major risk factors for capsular rupture and vitreous loss have been identified as

*Corresponding Author: Apeksha Raghunath

M.D., Department of Ophthalmology, Professor, Dr. D. Y. Patil Medical College and Research Hospital (Dr D Y Patil Vidyapeeth University), Pune, 411018, India

pupillary diameter and zonular fragility. Lens dislocation, zonular dialysis, and vitreous loss are all 10 times more likely when you have zonular fragility. In eyes that have had PEX, postoperative problems such as posterior capsular opacification, capsule contraction syndrome, intraocular lens decentration, and inflammation are more common.

We aim to study the complications and surgical difficulties that are encountered in such patients during MSICS.

Aim

To study the difficulties faced by a surgeon and complications encountered in patients with Pseudoexfoliation syndrome (PEX) undergoing cataract surgery in Western Maharashtra, India.

Objective

To study the difficulties and complications encountered in patients with Pseudoexfoliation syndrome (PEX) undergoing Manual small incision cataract surgery (MSICS).

2. MATERIAL AND METHODS

This prospective, non-randomized, cross-sectional descriptive study was done in the Ophthalmology department of a tertiary care hospital on 52 eyes of 52 patients with cataract and PEX who underwent MSICS (manual small incision cataract surgery) from the duration of September 2019 to August 2021. Pseudoexfoliation syndrome was diagnosed clinically by the presence of grey “dandruff-like” flakes on the anterior lens capsule or at the pupillary margin or both.

Patients diagnosed with cataract and PEX were included in this study. Patients with both eye pseudophakia, patients less than 50 years old, and those with cataract due to uveitis, trauma, or systemic diseases were excluded from the study. Institutional and ethics committee clearance was acquired before the start of the study.

Patients underwent complete ophthalmic evaluation including demographic parameters like age, gender, ethnicity, medical and ophthalmologic history.

A medical history was taken, as well as the occurrence of chronic illnesses such as hypertension, diabetes, thyroid disease, bronchial asthma, and tuberculosis. A measured systolic blood pressure of 160 mm Hg and/or a diastolic blood pressure of 90 mm Hg or greater, or current use of systemic antihypertensive drugs is used to describe systemic hypertension.

A written and informed consent was taken from all the patients in a language understood by them, after explaining the procedure and related risk. Pre-existing anterior segment anomalies were documented

along with maximal pupillary dilatation. Procedure of cataract surgery and any problems encountered during the surgery was noted and later recorded in post operative notes.

The collected data was analysed.

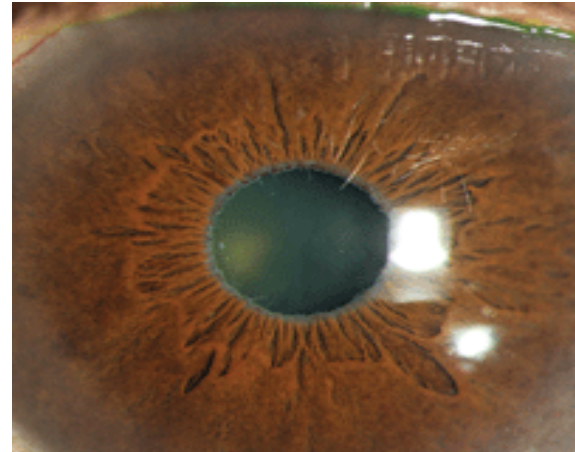


Figure i: PEX material pupillary margin

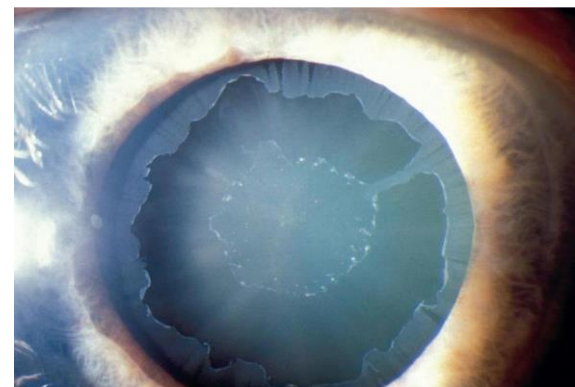


Figure ii: PEX material on anterior lens capsule (Target sign)

Statistical analysis

The data collected from the patients were coded and further tabulated. All data analysis had been done by using SPSS (version 22) for windows.

3. FINDINGS AND DISCUSSION

Table 1: Age wise distribution of patients

Age (years)	Frequency	Percentage
50-60	19	36.5%
61-70	23	44.2%
71-80	8	15.3%
81-90	2	3.8%
Total	52	100.0%

In our study, maximum patients were in the range of 61 to 70 years (44.2%), while 36.5% patients were in the range 50 – 60 years, 15.3% were in the range 71 to 80 year while only 3.8% were above 80 years.

Table 2: Gender wise distribution of patients

Gender	Frequency	Percentage
Male	27	52
Female	25	48
Total	52	100

In our study, 52.0% were male while 48.0% were female patients.

Table 3: Laterality of PEX Patients

Laterality	Frequency	Percentage
Unilateral	43	82.6%
Bilateral	9	17.3%

In our study, 82.6% patients had a unilateral condition while only 17.3% patients had bilateral condition.

Table 4: Pupillary dilatation

	Frequency	Percentage
<5 mm (poor)	10	19.2%
5-6 mm (moderate)	25	48.1%
>6 mm (good)	17	32.7%

In our study, in 48.1% patients had pupillary dilation of 5 to 6 mm (moderate), in 19.2% patients it was less than 6 mm (poor) while in 32.7% patients it was more than 6 mm (good).

Table 5: Zonular Dehiscence

Zonular Dehiscence	Frequency	Percentage
No	46	88.0%
Yes	6	12.0%
Total	52	100.0%

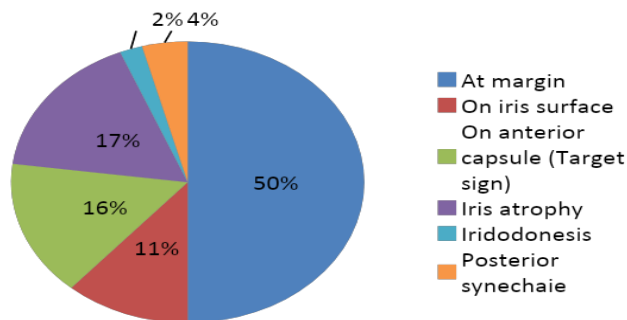
In our study, zonular dehiscence was seen in only 12.0% patients.

Table 6: PEX material location and iris features

PEX material location and iris features	Frequency	Percentage
PEX at pupillary margin	14	26.9%
PEX at Pupillary margin + iris surface	9	17.3%
PEX on anterior capsule (Target sign)	2	3.8%
PEX at Pupillary margin and anterior capsule	10	19.2%
Iris atrophy + PEX at pupillary margin	8	15.4%
Iris atrophy + PEX at pupillary margin and anterior capsule	2	3.8%
Iris atrophy + PEX at pupillary margin and iris surface	1	1.9%
Posterior synechiae + iris atrophy + PEX on anterior capsule	1	1.9%
Posterior synechiae + iris atrophy + PEX on anterior capsule and pupillary margin	1	1.9%
Posterior synechiae + iris atrophy + PEX on pupillary margin	2	3.8%
Iridodonesis + PEX on pupillary margin and anterior capsule	1	1.9%
Iridodonesis + Iris atrophy + PEX on anterior capsule	1	1.9%

In our study, the most common location of PEX material was at the pupillary margin alone being 26.9% (n=14), followed by PEX at pupillary margin and on the anterior capsule in 19.2% (n=10). PEX material was seen at pupillary margin and on iris surface in 17.3% (n=9) patients and PEX material at margin with iris atrophy was present in 15.3% (n=8) patients. The following anterior segment features were seen in 3.8% (n=2) patients each: PEX on the anterior capsule alone, PEX at pupillary margin and on anterior

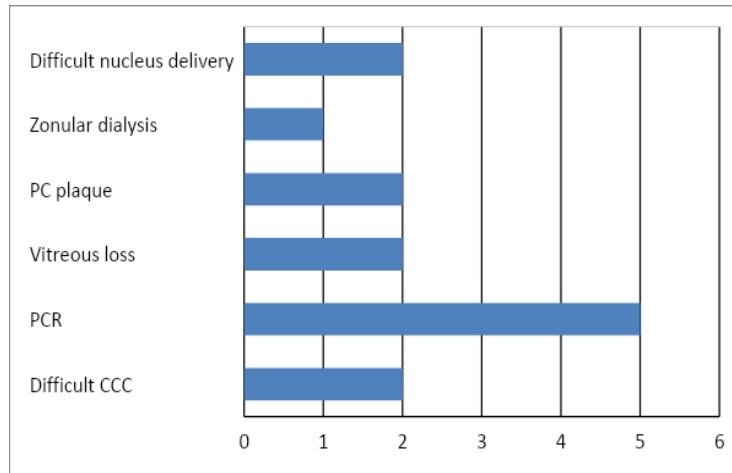
capsule along with iris atrophy, PEX on pupillary margin along with iris atrophy and posterior synechiae. The following features were seen in 1.9% (n=1) patients each: PEX at pupillary margin and on anterior capsule with iris atrophy, PEX on anterior capsule with iris atrophy and posterior synechiae, PEX on pupillary margin and on anterior capsule with iris atrophy and posterior synechiae, PEX on pupillary margin and anterior capsule with iridodonesis, PEX on anterior capsule alone with iris atrophy and iridodonesis.



Graph 1: Iris features and PEX distribution

Table 7: Intra-op complications- distribution of patients

Complications	Frequency	Percentage
Difficult CCC	2	3.8%
PCR	5	9.6%
Vitreous loss	2	3.8%
PC plaque	2	3.8%
Zonular dialysis	1	1.9%
Difficult nucleus delivery	2	3.8%



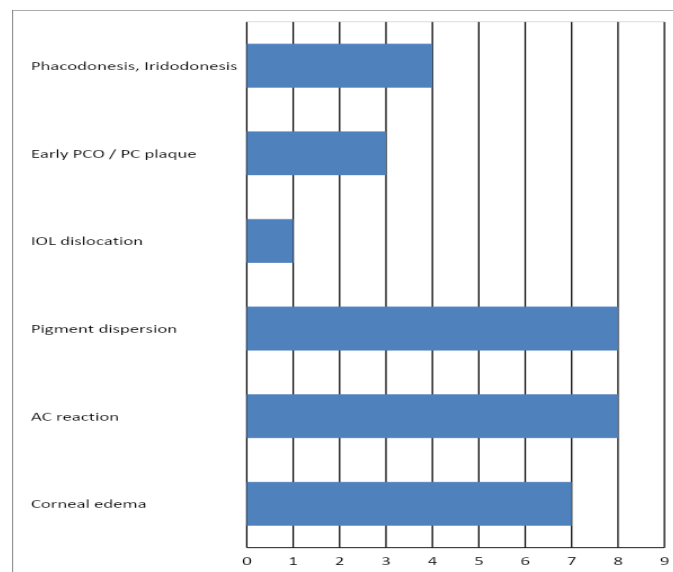
Graph 2: Intra-op complications: distribution of patients

Table 8: Post-op complications

Complication	Frequency	Percentage
Corneal edema	7	13.4%
AC reaction	8	15.3%
Pigment dispersion	8	15.3%
IOL dislocation	1	1.9%
Early PCO / PC plaque	3	5.7%
Phacodonesis, Iridodonesis	4	7.6%

In our study, in postoperative complications, in 15.3% patients were with AC reaction and pigment disruption, while 7.6% patients were with

Phacodonesis, Iridodonesis, 13.4% patients with corneal edema, 5.7% patients with early PCO and only 1.9% patients were found with IOL dislocation.



Graph 3: Post-op complications

Table 1: Age wise distribution of patients

Age (years)	Frequency	Percentage
50-60	19	36.50%
61-70	23	44.20%
71-80	8	15.30%
81-90	2	3.80%
Total	52	100.00%

Table 2: Gender wise distribution of patients

Gender	Frequency	Percentage
Male	27	52
Female	25	48
Total	52	100

Table 3: Laterality of condition

Laterality	Frequency	Percentage
Unilateral	43	82.6%
Bilateral	9	17.3%

Table 4: Pupillary dilatation

	Frequency	Percentage
<5 mm (poor)	10	19.23%
5-6 mm (moderate)	25	48.07%
>6 mm (good)	17	32.69%

Table 5: Presence of zonular dehiscence

Zonular Dehiscence	Frequency	Percentage
No	46	88
Yes	6	12
Total	52	100

Table 6: Iris features and distribution of PEX material

PEX material	Frequency	Percentage
At pupil margin	48	92.3%
On iris surface	11	21.15%
On anterior capsule (Target sign)	15	28.84%
Iris atrophy	16	30.76%
Iridodonesis	2	3.84%
Posterior synechiae	4	7.69%

Table 7: Intraoperative complications

Complications	Frequency	Percentage
Difficult CCC	2	3.8%
PCR	5	9.6%
Vitreous loss	2	3.8%
PC plaque	2	3.8%
Zonular dialysis	1	1.9%
Difficult nucleus delivery	2	3.8%

Table 8: Postoperative complications

Complication	Frequency	Percentage
Corneal edema	7	13.4%
AC reaction	8	15.3%
Pigment dispersion	8	15.3%
IOL dislocation	1	1.9%
Early PCO / PC plaque	3	5.7%
Phacodonesis, Iridodonesis	4	7.6%

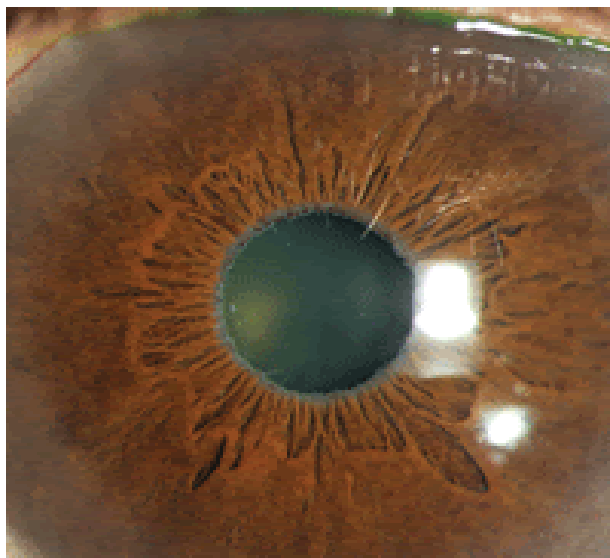


Figure 1: Pseudoexfoliation material at pupillary margin

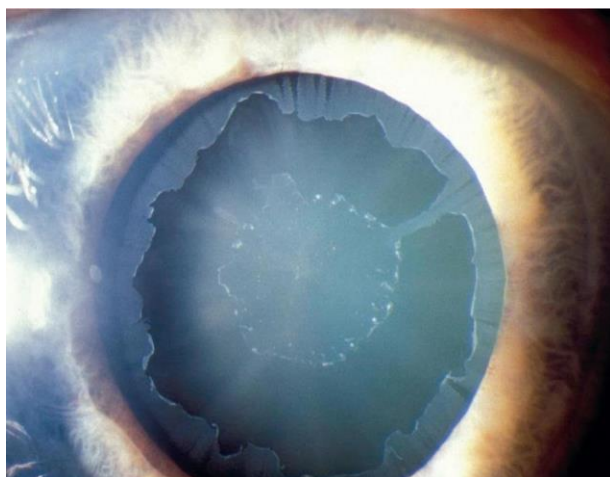


Figure 2: Pseudoexfoliation material on anterior lens capsule showing Target sign

DISCUSSION

In this study, (Table 1) most patients were in the age group of 61 to 70 years (44.2%). PEX occurs at different rates depending on the age, population and ethnicity. PEX is found to be directly proportional to the increased age. Mevlüt Yalaz *et al.*, conducted a study in Turkey that observed pseudoexfoliation in 11.2% of adults over 60 years of age. In Andhra Pradesh, an eye illness study discovered a prevalence of 0.7 percent, which rose to 3.0 percent in people over 40 years of age and 6.3 percent in people over 60 years of age. Within five to ten years after diagnosis, unilateral involvement is frequently a forerunner to bilateral involvement. It is shown that a unilateral condition may progress to a bilateral involvement with age. In a bilateral condition, prior cataract surgery in one eye can give a fair assessment of the possibility of complications like PCR in the cataractous eye with PEX.

Deposits of PEX material on the iris and pupillary edge are seen in 84 percent of patients,

according to a study by Ritch Schlotzer-Scherhardt¹ published at the same time. The exfoliative material at the pupillary border is thus the most obvious and constant clinical feature, second only to the deposition on the lens. Poor mydriasis in PEX was attributed by Asano N to degenerative alterations in the sphincter and dilator pupillae, as well as muscle cell involvement in PEX material fiber production. Degenerative alterations in both the stromal tissue and the muscle layer of the iris were discovered by Repo L.P. *et al.*, and this was thought to be one of the reasons for miosis. Bad dilatation, iridodonesis, phacodonesis and the presence of glaucoma have all been linked to posterior capsular rupture during cataract surgery. Preoperative assessment of pupillary dilation is a vital step prior to operating a patient of PEX. In patients with bad dilatation, mechanical aids like iris hooks and other pupil expansion devices are kept on standby to reduce or prevent the occurrence of intraoperative complications caused due to poor peripheral visibility.

Presence of zonular weakness can be combated by the use of CTR, which stabilizes the capsular bag by

redistributing forces from weak to intact zonules. Following surgical considerations are to be kept in mind while doing cataract surgery in patients with PEX: Main incision is placed opposite to the zonular weakness, Capsulorrhexis is initiated toward the weak zonules using the intact zonules for counter-traction, radial stripping of cortical matter is done to redistribute force and during IOL implantation, the leading haptic is inserted into the bag towards the area of zonular weakness and gently the haptics are trailed into the bag. Despite the fact that posterior capsule rupture (PCR) was the most common intraoperative complication (4.8 percent) in our study, the presence of pseudoexfoliation was not linked with PCR p-value > 0.05

Pseudoexfoliation causes inadequate pupillary dilatation and is an important element that raises the frequency of complications during cataract surgery, like zonular dehiscence and PCR. Patients with pseudoexfoliation had a higher rate of intraoperative and postoperative complications after cataract surgery. With thorough preoperative assessment and surgical precautions such as big capsulorhexis, minimal hydro procedure and nucleus rotation, careful AC wash and insertion of IOL done by minimal dialing, cataract surgery in patients with coexisting PEX can be done with minimal complications. Surgeons should be mindful of the dangers of cataract surgery in Pseudoexfoliation syndrome patients. Surgeons should use caution at every stage of cataract surgery in patients with PEX to avoid these complications and they should be aware of and experienced in complication management if they do occur.

3. CONCLUSION

This cross-sectional descriptive study was done in the Ophthalmology department of a Tertiary Care Hospital on 52 eyes of 52 patients with cataract and PEX who underwent MSICS surgery during the period from September 2019 to August 2021.

The most common location of PEX material was at the pupillary margin seen in 26.9%, followed by PEX at pupillary margin and on the anterior capsule in 19.2%. 48% showed pupillary dilatation of 5 to 6 mm, while 19.2% had poor pupil dilatation. Zonular dehiscence was seen in 12% i.e 6 patients. There was difficulty while performing CCC and difficult nucleus delivery in 2 patients i.e 3.8%. The most common complication was PC rent. Total intraoperative complications were seen in 25% patients and in a majority of 75% patients, no intraoperative complications were encountered by the surgeon. The most common postoperative complications were

corneal edema with anterior chamber reaction in 11.5% patients, followed by pigment dispersion in 9.6% patients. On comparing mean preoperative and postoperative IOP, there was no significant difference.

Patients with Pseudoexfoliation syndrome and cataract who have been planned for Manual small incision cataract surgery should be closely examined for Zonular weakness, inadequate mydriasis, phacodonesis and subluxation/dislocation of the cataractous lens, as these preoperative risk factors can cause surgical difficulties and thus affect the surgical outcome. Poor mydriasis is a major pre-operative risk factor in eyes with pseudoexfoliation syndrome and it contributes to intraoperative complications such as posterior capsular rent and vitreous loss. Sphincterotomy, synechiolysis, manual pupil stretching and use of pupil expanders enlarge the pupil size and lower the surgical complications. Although cataract surgery in Pseudoexfoliation is challenging, intraoperative difficulties can be handled and a favourable outcome can be obtained if the surgeon is aware of the condition prior to surgery and provides meticulous attention to surgical technique during manual small incision cataract surgery.

REFERENCES

1. National programme for control of blindness. (2010). Chandigarh: DGHS, Government of Punjab.
2. Jose, R. (2008). Present Status of the National Programme for Control of Blindness in India. *Community Eye Health*, 21(65), 103-104.
3. National Program for Control of Blindness in India, Directorate General of Health Services. Rapid Assessment of Avoidable Blindness. New Delhi: Ministry of Health and Family Welfare, Government of India; 2006-2007.
4. Vashist, P., Talwar, B., Gogoi, M., Maraini, G., Camparini, M., Ravindran, R. D., ... & Fletcher, A. E. (2011). Prevalence of Cataract in an Older Population in India. *Ophthalmology*, 118(2-19): 272-278.
5. Schlötzer-Schrehardt, U., & Naumann, G. O. (2006). Ocular and systemic pseudoexfoliation syndrome. *American journal of ophthalmology*, 141(5), 921-937.
6. Sood, N. N. (1968). Prevalence of pseudoexfoliation of the lens capsule in India. *Acta Ophthalmol (Copenh)*, 46, 211-214.
7. Lamba, P. A., & Giridhar A. (1984). Pseudoexfoliation syndrome (prevalence based on random survey hospital data), *Indian J Ophthalmol*, 32, 169-173.

Cite This Article: Apeksha Raghunath, O. K. Radhakrishnan, Aakriti Sharma (2022). A Study of Difficulties and Complications Encountered in Patients with Pseudoexfoliation Syndrome Undergoing Manual Small Incision Cataract Surgery (MSICS). *East African Scholars J Med Surg*, 4(6), 140-146.