

Original Research Article

Dermatofibrosarcoma of Darrier Ferrand Wide Surgical Excision of a Thoracic Location: About a Case and a Review of the Literature

Meskouri Karim^{1*}, A. Cherbal², R. Nemmar³, E. Kerboua⁴, A. Khelili², M. Cheriet²¹Professor Head of Department of Thoracic and Cardiovascular Surgery and Organ Transplantation MUSTAPHA University Hospital, Alger, Algeria²Assistant Physician in the Thoracic and Cardiovascular Surgery and Organ Transplantation Department at MUSTAPHA University Hospital, Alger, Algeria³Professor of Orthopedics Surgery and Traumatology CHU MUSTAPHA, Alger, Algeria⁴Professor in Medicine Oncology Piere Marie Curi Center, Algiers, Algeria**Article History**

Received: 03.03.2024

Accepted: 08.04.2024

Published: 10.04.2024

Journal homepage:<https://www.easpublisher.com>**Quick Response Code**

Abstract: Dermatofibrosarcoma (DFS) is a fibrous tumor of the skin, slow growing, with a very high risk of local recurrence, but with a low metastatic potential associated with a specific chromosomal translocation. It is found more frequently in adults and the elderly. The curative treatment is surgical by a wide excision laterally and in depth. This excision results in large losses of substances, the coverage of which is a real challenge for the surgeon and requires different means ranging from skin grafts to free musculo-cutaneous flaps. We report the case of a 49-year-old patient with a voluminous purplish polylobed anterior and upper thoracic mass. The radiological assessment revealed a superficial parietal dermal mass. He had a biopsy confirming the diagnosis of Dermatofibrosarcoma of Darrier and Ferrand. The excision surgery allowed a wide and complete resection with directed recovery with excellent postoperative results without recurrence at 06 months. The aim of this article is to present the therapeutic procedure for this pathology taking into account the site of the tumor, the size, the time of occurrence, the number of recurrences, the clinical signs, the operating protocol, the results of the pathological examination and post-operative complications with a review of the literature.

Keywords: Dermatofibrosarcoma of Darier and Ferrand, Thoracic; Surgical resection; skin coverage.

Copyright © 2024 The Author(s): This is an open-access article distributed under the terms of the Creative Commons Attribution **4.0 International License (CC BY-NC 4.0)** which permits unrestricted use, distribution, and reproduction in any medium for non-commercial use provided the original author and source are credited.

INTRODUCTION

Darier and Ferrand dermatofibrosarcoma (DFS) is a mesenchymal skin tumor with intradermal development first described by Taylor [1] as a sarcomatous tumor and then described by Jean Darier and Marcel Ferrand in 1924 [18]. It is a tumor, located between the benignity of the very common and harmless cutaneous fibroma and the malignancy of the true cutaneous fibrosarcoma. Its frankly malignant sarcomatous transformation with metastasis is exceptional. These tumors preferentially affect young adults. The diagnostic delay observed is on average 4 years. The trunk is the preferred location (60%), followed by the proximal extremities (30%).

Dermatofibrosarcomas, the frequency of which is not negligible in African countries [2], poses a problem linked to its unknown nature by the vast majority of doctors, its misleading clinical appearance evoking above all a keloid scar and often responsible for a delay

in diagnosis, its severity linked to its local aggressiveness and its destructive potential, its recurrent nature if the initial treatment has not respected the rigorous rules required for any management of this particular tumor.

This observation provides a presentation of a rare case of a large neglected thoracic skin tumor of Darrier Ferrand treated in our department, specifying the different epidemiological, clinical, prognostic and therapeutic characteristics of this very particular skin tumor.

MATERIALS AND METHODS

Year-old man admitted to our thoracic surgery department for the treatment of a very protuberant Darrier and Ferrand dermatofibrosarcoma of the neglected anterior chest wall evolving for 15 years following the increase in the size of the lesion the patient consulted or additional examinations confirmed the diagnosis. Physical examination reveals a large, painful

mass measuring 12 cm with a long mobile axis, multi-bundled, purplish and surrounded by collateral venous circulation, with no palpable peripheral lymphadenopathy, particularly in the latero -cervical, supra-clavicular and axillary areas (Fig 3).

A cervico-thoracic computed tomography (CT) scan was performed, revealing an anterior thoracic tissue mass measuring 70/82/94 mm with discreet infiltration of peri-lesional fat without invading muscular planes (Fig 1). MRI reveals a solid dermo-epidermal mass with multiple satellite nodules (Fig 2). Pathological examination of a fragment of a surgical biopsy of this mass revealed a CD34+ Dermatofibrosarcoma of Darried and Ferrand (Fig 8).

RESULTS

The patient underwent surgery and benefited from a very wide single-block excision of the tumor (Fig

4, 5 & 6) while respecting the safety margins on healthy skin tissue (at 4 cm) and in depth (at 3 cm) with skin rapprochement at the same operating time (Fig 9). The pathological study of the surgical specimen (Figure 7) confirmed the diagnosis.

The surgical outcomes were very favorable and the patient was discharged from the hospital on the 5th postoperative day and referred to plastic surgery for advice where directed healing was indicated without skin grafting. Reviewed in consultation, we note good healing with good thoracic adaptation and absence of recurrence at 06 months.

The result was deemed satisfactory aesthetically and functionally. However, minor complications were noted such as small areas of partial skin necrosis which were treated with small resections and directed healing.

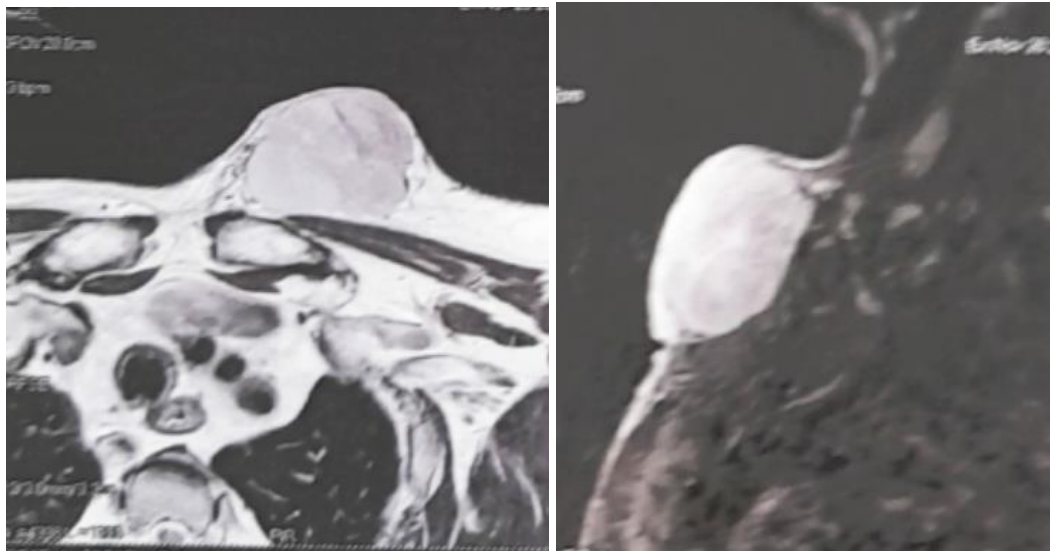


Fig 1: Appearance of the Tumor on Magnetic Resonance (K..MESKOURI collection)

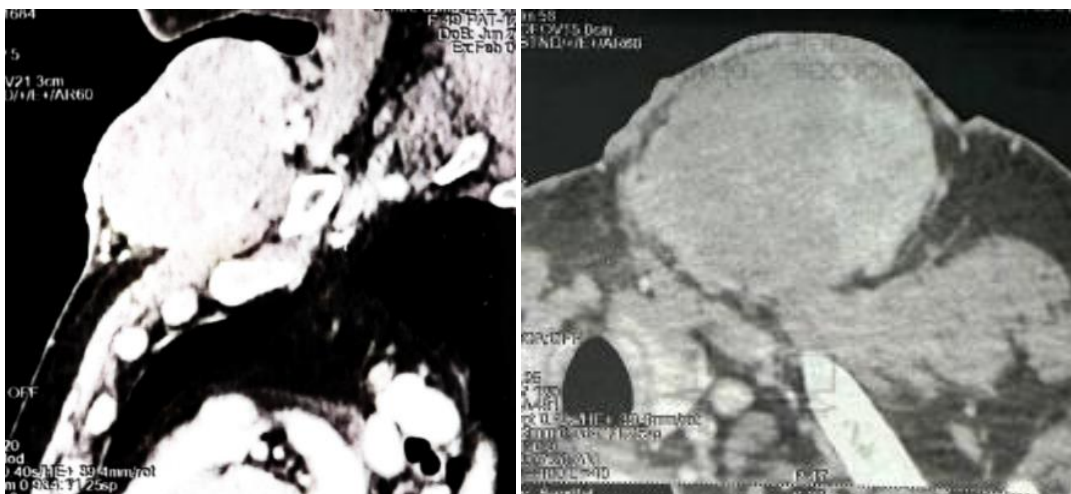

Fig 2: Appearance of the Tumor on cervicothoracic CT (K..MESKOURI collection)

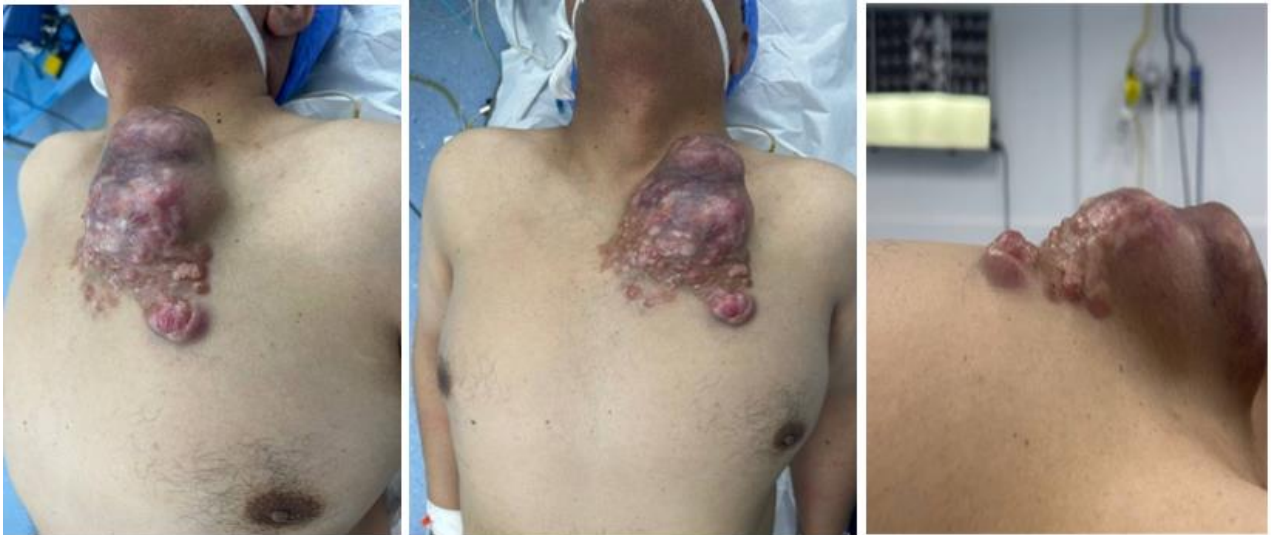

Fig 3: Macroscopic appearance of the anterior thoracic lesion (K..MESKOURI collection)

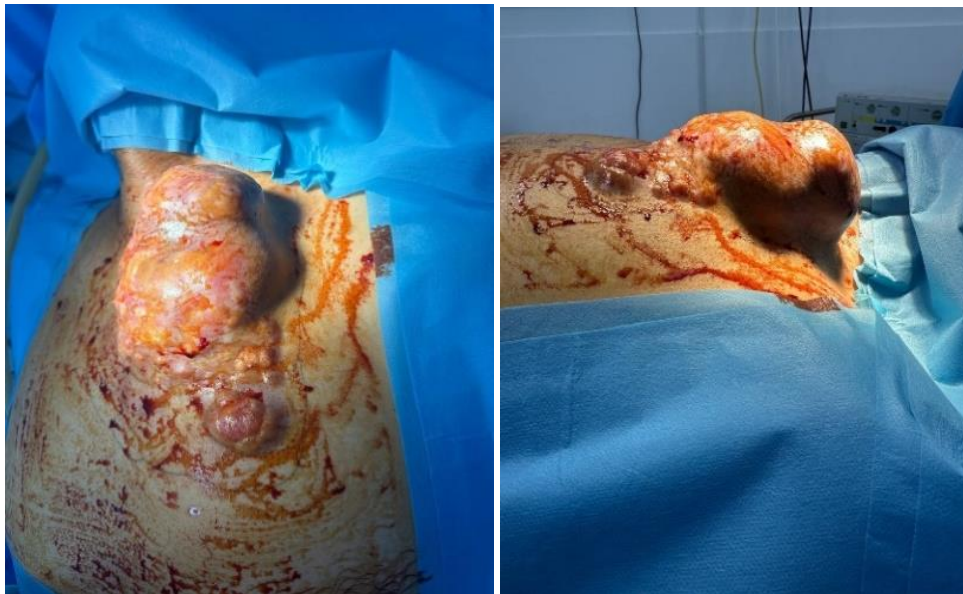


Fig 4: Installation of the patient in the operating room (K..MESKOURI collection)

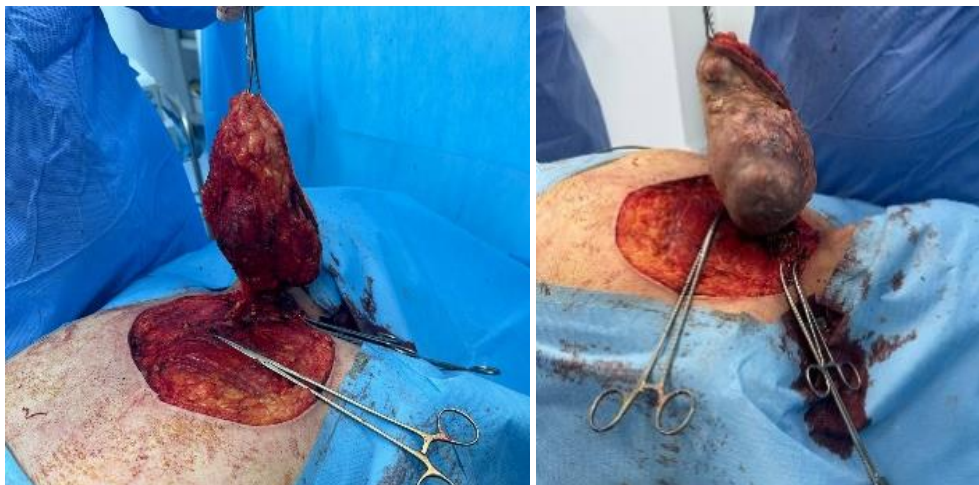

Fig 5: Complete excision of the tumor in one piece (K..MESKOURI collection)

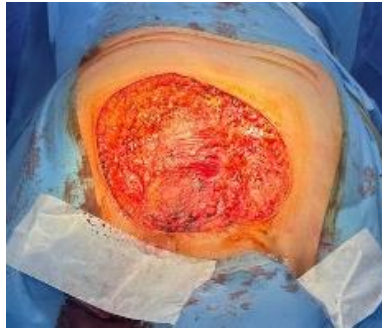

Fig 6: Wide safety margins after resection (K..MESKOURI collection)

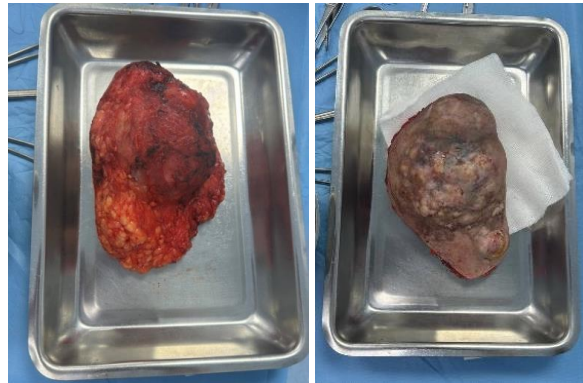


Fig 7: Operating part (K. MESKOURI collection)

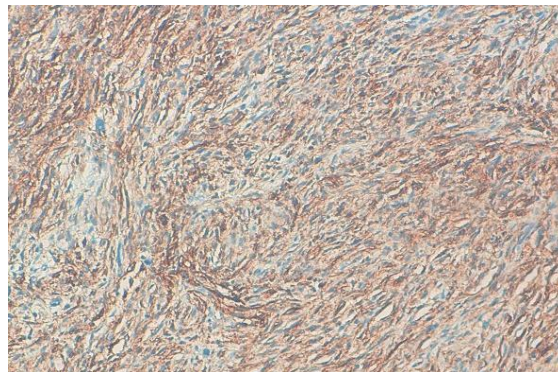


Fig 8: Pathological appearance Dermatofibrosarcoma of Darried and Ferrand CD34 + (K. MESKOURI collection)

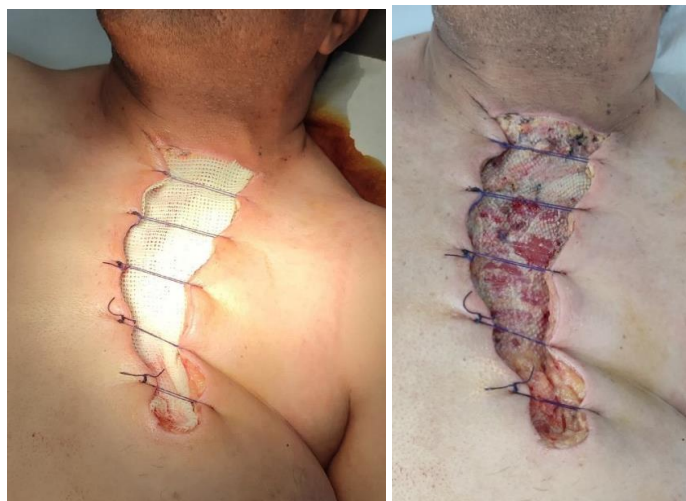

Fig 9: Final appearance after resection and skin approximation (K. MESKOURI collection)

DISCUSSION

Dermatofibrosarcoma (DFS) is a fibrous tumor of the skin, slow growing, with a very high risk of local recurrence, but with low metastatic potential. This tumor is rare but not exceptional, representing between 0.1% and 1% of malignant skin tumors [4].

Of all the definitions, that of DEGOS [3] seems to us the most complete: "it is a dermal connective tumor with spindle cells, more or less close in its histological structure to sarcomatous tumors, but which is opposed to true primary fibrosarcomas by its always cutaneous origin, and by its very slow evolution.

It can appear at any age, but usually occurs between the ages of 20 and 50; with averages varying between 28 and 47 years according to the authors [4]. With a male predominance [4, 5].

For our patient, we did not find any triggering factor (trauma, scar, etc.) as reported by some authors [4, 7]. Other authors also mention burn scars [8], vaccination scars [8], radiotherapy [8], syphilitic lesions [9], microtrauma on healthy skin [8, 9], on the clinical level our patient joins those in the literature with regard to tumor location, size, clinical appearance and delay in therapeutic demand [4-6, 8]. Development tends to be slow with deep local infiltration. The clinical appearance at the start, the lesion presents as an indurated plaque, covered with skin of normal appearance and coloring, sometimes whitish, pinkish, purplish or reddish, it is apparently well demarcated and is mobile in relation to the planes. deep. At a more advanced stage, the plaque spreads, its surface becomes irregular and bumpy, creating after a few months to a few years, a multinodular mass, often polychrome, of variable size. This evolution in two stages is not constant because certain forms are immediately uninodular or multinodular with secondary fusion of the nodules. Cases of "monstrous tumors" reaching 6.5 or even 7 kg [8] have been described. Tumors can reach enormous dimensions of up to 25 cm in diameter [4]. The lesion can develop in any part of the body [4] often in the trunk as in the case of our patient. Lymph node metastases and visceral metastases are exceptional and can only be found after long developments and sarcomatous transformation [10]. Absent in our patient.

Diagnosis can be made by histological analysis of the biopsy of the lesion, revealing characteristics of a well-differentiated fibroblastic tumor with bundles of spindle cells arranged in wheel spokes and positive CD34 staining and more than 90% of cases are associated with deregulated production of the growth factor PDGF (platelet-derived growth factor) which results from a chromosomal translocation or the formation of a supernumerary chromosomal ring derived from t(17;22). Imaging, such as MRI or CT, is more useful to estimate the depth of tumor invasion or to identify sites of metastases. The differential diagnosis

includes fibrosarcoma, dermatofibroma, neurofibroma and other soft tissue tumors.

The commonly used treatment for primary DFS is surgical ablation with healthy tissue excision margins with extemporaneous histological examination, is associated with a low risk of recurrence and could reduce the amount of tissue resected. We have opted, like the majority of authors [4-6, 8, 11], for a safety margin of 3 to 5 cm in surface area with sacrifice of a healthy anatomical barrier in depth. Coverage of substance losses caused by excision uses the different means offered by reconstructive plastic surgery ranging from skin grafting to complex microsurgery techniques by transfer of free micro-anastomosed musculo-cutaneous flaps. This coverage is often done, as for our patient, deferred after confirmation of the oncological nature of the excision by the anatomico-pathological study of the surgical specimen.

The overall recurrence rate for these teams is low (3%) [9-11] and the mortality rate is low (<3% at 10 years).

Concerning the evolution, several publications report the low rate of recurrence after extensive surgery from the outset compared to cases seen by second intention [3-5, 8]. This is confirmed for our patient, with no recurrence at 06 postoperatively. This tumor is rarely life-threatening due to its proliferation alone; on the other hand, the prognosis is linked to its locally destructive nature and the risk of recurrence which remains mainly linked to the quality of the first excision. The chances of recovery in the event of well-conducted primary surgery are significantly greater than those of salvage surgery. The tumor excision must therefore be wide on the surface, passing 5cm from the lesion and deep with sacrifice of a healthy barrier in depth. The systematic reduction of clinical surface excision margins to less than 5 cm unnecessarily places the patient at risk of recurrence and must be reserved for certain difficult anatomical locations. Improving the prognosis of DFS requires: early diagnosis in order to ensure rapid treatment of patients and therefore to avoid mutilating excisions, the repair of which is sometimes complex.

CONCLUSION

Darier and Ferrand DFS is a tumor whose prognosis and progressive risk are mainly linked to the diagnostic delay and the quality of the first excision. Late diagnosis makes excision and reconstruction surgery difficult. The possibilities of recovery in the case of well-conducted primary surgery are significantly greater than those of salvage surgery. Improving the prognosis requires early and codified multidisciplinary care, hence the importance of raising awareness and providing information to doctors for early diagnosis and the correct referral of these patients to specialized centers for treatment. in multidisciplinary care, involving different

specialists (dermatologists, surgeons; plastic surgeons and competent pathologists).

Conflict of Interest: The authors declare no conflict of interest.

REFERENCES

1. Taylor, R. W. (1890). Sarcomatous tumors resembling in some respects keloids. *Arch Dermatol*, 8, 384-387.
2. Kneebone, RL, Melissas, J. & Mannell, A. (1984). Dermatofibrosarcoma protuberans in black patients. *South african medical journal*, 66(24), 919-921.
3. Degos, H., Civatte, J., & Belaich, S. (1981). Dermatofibrosarcoma of Darier -Ferrand. (HOFFMANN's dermatofibrosarcoma protuberans) Edition Flammarion Paris: *Dermatology*; pp. 875-877.
4. Kasse, A., Dieng, M., Deme, A., & Fall, M. C. (1999). Dermatofibrosarcomas of Darier and Ferrand, about 22 cases and review of the literature. *Black African medicine*, 46(4), 222-227.
5. Joucdar, S., Kismoune, H., Boudjemia, F., Acha, D., & Abed, L. (2001). Dermatofibrosarcomas of Darier and Ferrand: retrospective analysis of 81 cases over ten years (1983-1994), *Ann Chir Plast Esthét*, 46(2), 134-140.
6. Gutierrez, G., Ospina, J. E., De Baez, N. E., & De Escorcia, E. K. (1984). Dermatofibrosarcoma protuberans. *Int J Dermatol*, 23(6), 396-401.
7. Vignon-Pennamen, M. D., Verola, O., & Champeau, F. (2002). *Encycl Méd Chir*. Paris: Editions Scientifiques et Médicales Elsevier SAS; 2002. Cutaneous sarcomas; p. 14. *Dermatology*, 98-650-A-10.
8. Burkhard, B. R., Soule, E. H., Chahbra, H., & Postel, A. (1966). Dermatofibrosarcoma protuberans: study of fifty six cases. *Am J Surg*, 111(5), 638-644.
9. Costa, O. G. (1924). Progressive recurrent dermatofibroma (Darier -Ferrand): anatomical study. *Arch Derm Syph Paris*, 5, 432-454.
10. Trembla, Y. M., Bonenfant, J. L., & Cliché, J. (1970). Dermatofibrosarcoma protuberans: clinico-pathological study and thirty cases with the ultrastructure of two cases. *Union Med Can*, 99(5), 871-876.
11. Arnaud, E. J., Perrault, M., Revol, M., Servant, J. M., & Banzet, P. (1997). Surgical treatment of dermatofibrosarcoma protuberans. *Plastic and reconstructive Surgery*, 100(4), 884-895.
12. Behbahani, R., Patenotre, P., Capon, N., & Martinot-Duquennoy, V. (2005). Towards a reduction of lateral margins in dermatofibrosarcomas of Darier and Ferrand? Retrospective study of 34 cases. *Ann Chir Plast Esthet*, 50(3), 179-185.
13. Revol, M., & Verola, O. (2005). Comments on the article: "Towards a reduction of lateral margins in dermatofibrosarcomas of Darier and Ferrand? Retrospective study of 34 cases, *Ann Chir Plast Esthet*, 50(3), 186-188.
14. Popov, P., Böbling, T., Asko-Seljavaara, S., & Tukiainen, E. (2007). Microscopic margins and results of surgery for dermatofibrosarcoma protuberans. *Plastic and Reconstructive Surgery*, 119(6), 1779-1784.
15. Pachet, C. Faculty of Medicine; 2007. Contribution of micrographic surgery in reducing the margins of dermatofibrosarcoma of Darier and Ferrand: study of 31 cases comparing wide excision and micrographic surgery and review of the literature Thesis for the doctorate in medicine, University of Paris 7-Denis Diderot year.
16. Ah-Weng, A., Marsden, J. R., Sanders, D. S. A., & Waters, R. (2002). Dermatofibrosarcoma protuberans treated by micrographic surgery. *British journal of cancer*, 87(12), 1386-1389.
17. Wright, T. I., & Petersen, J. E. (2007). Treatment of recurrent dermatofibrosarcoma protuberans with imatinib mesylate, followed by Mohs micrographic surgery. *Dermatologic surgery*, 33(6), 741-744.
18. Darier, J., & Ferrand, M. (1924). Progressive and recurrent dermatofibromas or fibrosarcomas of the skin. *Ann Dermatol Syph*, 5, 545-62.

Cite This Article: Meskouri Karim, A. Cherbal, R. Nemmar, E. Kerboua, A. Khelili, M. Cheriet (2024). Dermatofibrosarcoma of Darier Ferrand Wide Surgical Excision of a Thoracic Location: About a Case and a Review of the Literature. *East African Scholars J Med Surg*, 6(4), 131-136.
