East African Scholars Journal of Medicine and Surgery
Abbreviated Key Title: EAS J Med Surg
ISSN: 2663-1857 (Print) & ISSN: 2663-7332 (Online)
Published By East African Scholars Publisher, Kenya

OPEN ACCESS

Volume-8 | Issue-10 | Nov-2026 | DOI: https://doi.org/10.36349/easjms.2026.v08i10.003

Original Research Article

Adenocarcinoma of the Pancreatic Head: Results of Curative Treatment in a Series of 61 Cases

Abdelkrim Chetibi[1]*, Rachid Ghemit[1], Mohamed Oualid[1]

[1]Department of General and Oncological Surgery, Beni-Messous University Hospital Centre, Algiers, Algeria

Article History
Received: 21.09.2026
Accepted: 13.11.2026
Published: 21.11.2026

Journal homepage:
https://www.easpublisher.com

Quick Response Code

Abstract: ***Introduction*:** Curative resection of pancreatic adenocarcinoma (PDAC) is possible in only 10% of cases. Pancreaticoduodenectomy remains the standard operation. Five-year actuarial survival does not exceed 5%; however, after curative (R0) resection, it is 20% to 25% in recent surgical series. ***Objective*:** To assess the outcomes of curative treatment for adenocarcinoma of the pancreatic head. ***Patients and Methods*:** This was a retrospective, single-centre, observational study conducted from January 1, 2017, to September 30, 2023. Sixty-one patients were included in our study. The mean age of the patients was 66 years (range, 39 to 88 years). The study included 34 men and 27 women, giving a male-to-female sex ratio of 1.2. According to the American Society of Anesthesiologists (ASA) classification, most patients were ASA I or ASA II. ***Results*:** Clinically, jaundice and pain were found in 50 and 31 patients, respectively. Deterioration in general condition was observed in 23 patients. The time to diagnosis was 5 months (range, 3 to 18 months). Histological examination of the surgical specimen showed adenocarcinoma in 100% of cases. Surgery was performed in 14.7% of patients, and treatment was mainly palliative in 57.3% of cases. Morbidity after resection was 44.4%. Mortality after resection was 11%. ***Conclusion*:** Surgical resection is currently the only treatment that can provide prolonged survival; however, even after a curative procedure, five-year survival rates remain low.

Keywords: Adenocarcinoma, Pancreas, Resection, Histopathology, Outcomes.

Copyright © 2026 The Author(s): This is an open-access article distributed under the terms of the Creative Commons Attribution **4.0 International License (CC BY-NC 4.0)** which permits unrestricted use, distribution, and reproduction in any medium for non-commercial use provided the original author and source are credited.

INTRODUCTION

Curative treatment of pancreatic adenocarcinoma relies primarily on oncological surgical resection, which is possible in only 10% of cases. This cancer is most often diagnosed at an advanced stage. The results of radical surgery remain poor [1].

Lymph node and/or vascular involvement constitute highly adverse prognostic factors. However, lymph node extension limited to the first-echelon nodes and/or involvement of the mesentericoportal venous axis are not contraindications to resection [2]. Pancreaticoduodenectomy remains the standard operation. Its postoperative mortality has decreased considerably in experienced centres. Pancreatic fistula depends mainly on the quality of the pancreatic remnant parenchyma and on the diameter of the main pancreatic duct (Wirsung duct). Median survival after resection ranges from 12 to 18 months; five-year actuarial survival does not exceed 5%, but after curative (R0) resection it is 20% to 25% in recent surgical series [3]. Several scientific studies have demonstrated the value of preoperative chemoradiotherapy in locally advanced pancreatic cancer. This chemoradiotherapy could increase survival beyond two years [4].

PATIENTS AND METHODS

This was a retrospective, single-centre, observational study conducted from January 1, 2017, to September 30, 2023. Sixty-one patients were included in our study. According to the American Society of Anesthesiologists (ASA) classification, most patients were ASA I or ASA II.

The Following Variables Were Studied:

Patient age and sex, preoperative biological parameters, intraoperative findings, postoperative course, and postoperative morbidity and mortality.

General Patient Characteristics:

The mean age of the patients was 66 years (range, 39 to 88 years). The study included 34 men and 27 women, giving a male-to-female sex ratio of 1.2. According to the American Society of Anesthesiologists (ASA) classification, patients were ASA I in 39.3% of

***Corresponding Author:** Abdelkrim Chetibi
Department of General and Oncological Surgery, Beni-Messous University Hospital Centre, Algiers, Algeria

cases, ASA II in 29.3% of cases, and ASA III in 9.8% of cases.

Clinical, biological, morphological, and operative characteristics: The predominant clinical symptom was jaundice, reported by 81.96% of patients; abdominal pain occurred in 50.81% of cases, and deterioration in general condition in 37.70%.

The time to diagnosis was 5 months, with a range of 3 to 18 months. Mean preoperative haemoglobin was 11.32 g/L, and mean preoperative serum albumin was 38.43 g/L. The tumours were located in the pancreatic head in 100% of cases.

Table 1: General, clinical, and morphological characteristics of the patients

Characteristics	Values
ASA classification	
ASA I	24 (39.3%)
ASA II	31 (29.3%)
ASA III	06 (9.8%)
Clinical characteristics	
Jaundice	81.96 (50%)
Abdominal pain	42 (50.81%)
Deterioration in general condition	33 (37.70%)
Morphological investigations	
Abdominal ultrasound	61 (100%)
Computed tomography	61 (100%)
MRI	23/61 (37%)
ERCP	06/61 (9.8%)
Endoscopic ultrasound	4/61 (6.5%)
Mean preoperative Hb	11.32
Mean preoperative serum albumin (g/L)	38.43
Surgical approach	
Laparotomy	52 (85.52%)
Tumour location	
Pancreatic head	61 (100%)
Tumour resection (DPC)	09 (14.7%)

Table 2: Preoperative TNM classification

Characteristics	Values
Well differentiated	21 (34.42%)
Moderately differentiated	16 (26.22%)
Poorly differentiated	24 (39.34%)
cT1	00 (0%)
cT2	07 (11.47%)
cT3	20 (32.78%)
cT4	35 (57.37%)
cN0	05 (08.19%)
cN+	28 (45.90%)
cM0	25 (40.98%)
cM1	36 (59.01%)

The histological type was well-differentiated adenocarcinoma in 34.42% of cases. Contrast-enhanced thoracoabdominopelvic computed tomography was performed in all our patients, allowing assessment of local, locoregional, and distant tumour extension and classification of the tumours using the 8th edition of the UICC TNM classification, published in 2017. Tumours were classified as cT2 in 11.47% of cases, cT3 in 32.78% of cases, and cT4 in 57.37% of cases; cN+ stages accounted for 45.90% of cases. Tumours were classified as cM0 in 40.98% of cases and cM1 in 59.01% of cases.

Table 3: Postoperative parameters of the patients

Postoperative course	Values
Morbidity after resection	44.4%
Pancreatic fistula	22.2%
Gastroparesis	11.1%

Postoperative course	Values
Biliary fistula	11.1%
Morbidity without resection	22.8%
Mortality after resection	11%
Mortality without resection	9.3%
Survival after resection	
- Patient alive without recurrence at 3 years	01
- Patients alive without recurrence at 1 year	02

Postoperative parameters of the patients: Fifty-two patients underwent surgery during the inclusion period (January 1, 2017, to September 30, 2023) through a midline laparotomy. Pancreaticoduodenectomy was performed in 14.7% of patients. Postoperative parameters of the patients: the overall postoperative mortality rate in the series was 9.6%. We observed postoperative complications after resection in 44.4% of patients. These consisted of minor grade I and II complications according to the Clavien-Dindo classification in 02 patients (22.2) and major grade III and IV complications in 01 patient (11.1%).

Table 4: Postoperative pTNM classification

Parameters	Values
pT1	0 (0%)
pT2	07 (77.77%)
pT3	02 (22.22%)
pT4	0 (0%)
N+	8 (88.88%)
N-	1 (11.11%)
R0	8 (88.88%)
R1	1 (11.11%)

Histopathological Parameters:

77.77% of tumours were classified as pT2 and 22.22% as pT3. Surgical resection was classified as R0 in 88.88% of our patients. Lymph node involvement (N+) accounted for 88.88% of cases.

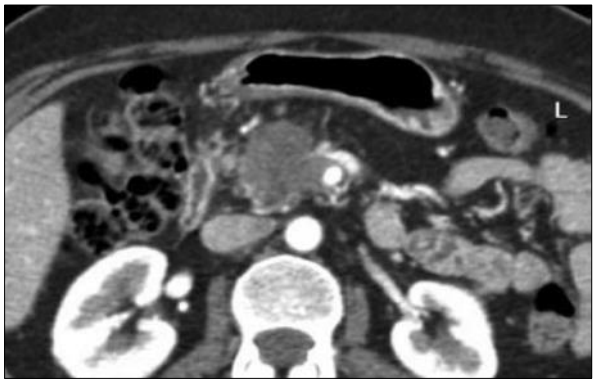

Figure 1: Axial section showing a mass in the head of the pancreas

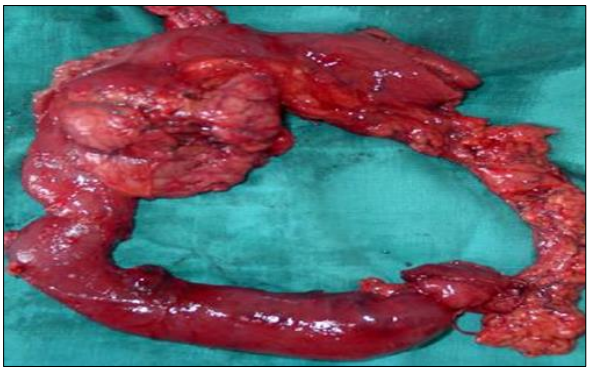

Figure 2: Surgical specimen from a pancreaticoduodenectomy

DISCUSSION

Pancreatic ductal adenocarcinoma accounts for 90% of pancreatic cancers and is the fifth leading cause of cancer-related death in developed countries [1]. It is most often diagnosed at an advanced stage. It is the digestive cancer with the poorest prognosis, with an overall five-year survival rate below 5% [1, 2]. This cancer ranks third among digestive cancers managed in our department.

The clinical presentation of pancreatic ductal adenocarcinoma (PDAC) is highly variable. The predominant symptom is jaundice. The pancreatic head is the most common site. In our study, delayed diagnosis, advanced age, and poor baseline condition account for the main difficulties in patient management.

Several scientific studies have shown that the pretherapeutic assessment (computed tomography) makes it possible to determine resectability with a high degree of accuracy, plan the surgical procedure according to vascular involvement, and anticipate the risk of pancreatic fistula [4-7].

In our series, preoperative morphological findings contributed consistently to therapeutic decision-making by reducing the risk of unnecessary laparotomy, which probably has a negative impact on survival. Multidisciplinary team meetings had a major impact on our therapeutic approach. Curative treatment of pancreatic adenocarcinoma relies primarily on oncological surgical resection [3, 4]. This study aims to assess the outcomes of curative surgical treatment of pancreatic adenocarcinoma. The interval between symptom onset and therapeutic management has an impact on patient survival [5-8]. All patients must be prepared for surgery through adequate nutritional support and preoperative correction of severe jaundice. Exocrine insufficiency and correction of poorly controlled diabetes are essential [9-27]. The objective of PDAC resection is to achieve complete oncological excision of the tumour with clear safety margins [13-19] (Figure 2). R0 resection is associated with a better prognosis, with median survival ranging from 30 to 40 months [20-23]. The resection margin with prognostic significance is the retrovascular margin, formed by the retroportal lamina [24-28]. In our series, the resectability rate was low (14.7%). This rate is mainly related to delayed diagnosis. Nevertheless, chemoradiotherapy (50 or 54 Gy combined with capecitabine) could improve the R0 resection rate and, consequently, long-term survival; however, a bias related to better patient selection could also explain our results. Resections extended to vascular structures and the techniques used to repair them have recently led to progress in pancreatic cancer surgery [29-31]. In the literature, palliative resection is not recommended because survival is identical to that achieved with chemotherapy, with a median of approximately 12 months [32-34]. The most commonly performed operation for PDAC is pancreaticoduodenectomy (DPC) with lymph node dissection. Several studies have shown that extended lymphadenectomy does not improve survival; therefore, there is no reason to perform an N2 lymph node dissection [18-25]. In expert centres, mortality after pancreaticoduodenectomy for PDAC is 4% to 5%, and early morbidity is 50%, including 20% to 25% pancreatic fistulas [31-36]. In our series, the morbidity and mortality rates were high (44.4% vs 11%). This increase may largely be explained by delayed management and by the level of expertise that the surgeon must acquire to ensure an adequate resection. Patient selection is essential to reduce operative mortality. Pancreaticoduodenectomy also carries a high risk of diabetes (20%) and exocrine insufficiency (50%). Patient selection is necessary to limit operative mortality [24-28].

Despite the poor prognosis of PDAC, surgery should not be offered to a patient whose predicted risk of mortality exceeds 10%, because, if death does not occur, morbidity will be substantial and will limit the possibility of adjuvant chemotherapy and adversely affect postoperative quality of life [37-40]. In our practice, we did not use targeted therapies or immunotherapy in the management of adenocarcinoma of the pancreatic head.

CONCLUSION

Curative treatment of pancreatic adenocarcinoma relies primarily on oncological surgical resection. This cancer is most often diagnosed at an advanced stage. The results of radical surgery remain poor. To improve patient management, multidisciplinary team meetings (MDT meetings) should be held, and referral of patients to specialist centres should be considered on each occasion.

Conflicts of Interest: The authors declare that they have no conflicts of interest related to this article.

Author Contributions

Abdelkrim Chetibi designed the study and wrote the manuscript. Mohamed Oualid and Rachid Ghemit read and corrected the manuscript. All authors read and approved the final version of the manuscript.

REFERENCES

1. Poruk KE et al. The clinical utility of CA 19-9 in pancreatic adenocarcinoma: diagnostic and prognostic updates. Curr Mol Med 2013; 13: 340-51.
2. Gobbi PG et al. The prognostic role of time to diagnosis and presenting symptoms in patients with pancreatic cancer Cancer Epidemiology, 2013; 37: 186-90.
3. Yeo CJ, Cameron JL, Lillemoe KD et al. Pancreaticoduodenectomy for cancer of the head of the pancreas: 201 patients. Ann Surg 1995; 221 :721-733

4. Pietrasz D et al. How Does Chemoradiotherapy Following Induction FOLFIRINOX Improve the Results in Resected Borderline or Locally Advanced Pancreatic Adenocarcinoma? AGEO- FRENCH Multicentric Cohort. Ann Surg Oncol. 2018 Oct 25. [Epub ahead of print].
5. Zims M. Imagerie de l'ADK pancréas. J Radiol 2005.
6. Kim JH et al. Visually isoattenuating pancreatic adenocarcinoma at dynamic-enhanced CT: frequency, clinical and pathologic characteristics, and diagnosis at imaging examinations. Radiology. 2010; 257: 87-96.
7. DeWitt et al. Comparison of endoscopic ultrasonography and multi detector computed tomography for detecting and staging pancreatic cancer. Ann. Intern Med 2004
8. Tamburrino D et al. Diagnostic accuracy of different imaging modalities following computed tomography (CT) scanning for assessing the resectability with curative intent in pancreatic and periampullary cancer. Cochrane Database systematic review 2016; 9: CD011515.
9. Pappas SG et al. Staging chest computed tomography and positron emission tomography in patients with pancreatic adenocarcinoma: utility or futility? HPB (Oxford) 2014; 16: 70-4.
10. Roche et al. CT and pathologic assessment of prospectif nodal staging in patients with ductal adenocarcinoma of the head of the pancreas AJR 2003
11. JL Cameron et al. One thousand consecutive pancreatoduodenectomies. Ann Surg 2006
12. Ta R et al. The Role of Staging Laparoscopy in Resectable and Borderline Resectable Pancreatic Cancer: A Systematic Review and Meta-Analysis Dig Surg. 2018 Apr 12. [Epub ahead of print].
13. Conroy T et al. FOLFIRINOX versus Gemcitabine as Adjuvant Therapy for Pancreatic Cancer. N Engl J Med 2018, 20; 379: 2395-2406.
14. Conroy T et al. FOLFIRINOX versus gemcitabine for metastatic pancreatic cancer. N Engl J Med. 2011; 364: 1817-25.
15. Khorana AA et al. Potentially Curable Pancreatic Cancer: American Society of Clinical Oncology Clinical Practice Guideline Update. J Clin Oncol. 2017; 35: 2324-2328.
16. Tempero MA et al. Pancreatic Adenocarcinoma, Version 1.2019, NCCN Clinical Practice Guidelines in OncologyJ Natl Compr Canc Netw. 2018. https://www.nccn.org/professionals/ physician_gls/pdf/pancreatic.pdf
17. Al Hawary MM et al. Pancreatic ductal adenocarcinoma radiology reporting template: consensus statement of the society of abdominal radiology and the American pancreatic association. Gastroenterology. 2014; 146: 291-304.
18. Isaji S et al. international consensus on definition and criteria of borderline resectable pancreatic ductal adenocarcinoma 2017. Pancreatology. 2018; 18: 2-11.
19. Gerritsen A et al. Preoperative characteristics of patients with presumed pancreatic cancer but ultimately benign disease: a multicenter series of 344 pancreatoduodenectomies. Ann Surg Oncol. 2014; 21: 3999-4006.
20. Rijkers AP et al. Usefulness of F-18-fluorodeoxyglucose positron emission tomography to confirm suspected pancreatic cancer: a meta-analysis. Eur J surg Oncol 2014; 40: 794-804.
21. Choi SY et al. Differentiating Mass-Forming Autoimmune Pancreatitis From Pancreatic Ductal Adenocarcinoma on the Basis of Contrast-Enhanced MRI and DWI Findings. Am J Roentgenol. 2016; 206: 291-300.
22. Matsubara J et al. Ultrasound-guided percutaneous pancreatic tumor biopsy in pancreatic cancer: a comparison with metastatic liver tumor biopsy, including sensitivity, specifi city, and complications. J Gastroenterol 2008; 43: 225–232.
23. Pedrazzoli S. Extent of lymphadenectomy to associate with pancreaticoduodenectomy in patients with pancreatic head cancer for better tumor staging. Cancer Treat Rev. 2015; 41: 577-87.
24. Schwarz L et al. Para-aortic lymph node sampling in pancreatic head adenocarcinoma Br J Surg. 2014; 101: 530-8.
25. Kim HR et al. Clinical impact of fluorine-18-fluorodeoxyglucose positron emission tomography/ computed tomography in patients with resectable pancreatic cancer: diagnosing lymph node metastasis and predicting survival. Nucl Med Commun 2018; 39: 691-698.
26. Scheufele F et al. Preoperative biliary stenting versus operation first in jaundiced patients due to malignant lesions in the pancreatic head: A meta-analysis of current literature Surgery. 2017; 161: 939-950.
27. Sauvanet A et al. Severe Jaundice Increases Early Severe Morbidity and Decreases Long-Term Survival after Pancreaticoduodenectomy for Pancreatic Adenocarcinoma.J Am Coll Surg. 2015; 221: 380-9.
28. Inamdar S et al. Comparison of Adverse Events for Endoscopic vs Percutaneous Biliary Drainage in the Treatment of Malignant Biliary Tract Obstruction in an Inpatient National Cohort. JAMA Oncol. 2016; 2: 112-7.
29. Neoptolemos JP et al. Comparison of adjuvant gemcitabine and capecitabine with gemcitabine monotherapy in patients with resected pancreatic cancer (ESPAC-4): a multicentre, open-label, randomised, phase 3 trial. Lancet. 2017; 389: 1011-1024.
30. Delpero JR et al. Prognostic Value of Resection Margin Involvement After Pancreaticoduodenectomy for Ductal Adenocarcinoma: Updates from a French

Perspective Multicenter Study.Ann Surg. 2017; 266: 787-796.
31. Giovinazzo F et al. Meta-analysis of benefits of portal-superior mesenteric vein resection in pancreatic resection for ductal adenocarcinoma. Br J Surg. 2016; 103: 179-91.
32. Farges O et al. The Theory and Practice of Pancreatic Surgery in France. Ann Surg. 2017; 266:797-804.
33. Delpero JR et al. Pancreatic adenocarcinoma with venous involvement: is up-front synchronous portal-superior mesenteric vein resection still justified? A survey of the Association Française de Chirurgie. Ann Surg Oncol. 2015; 22: 1874-83.
34. Neoptolemos JP et al. Adjuvant chemotherapy with fluorouracil plus folinic acid vs gemcitabine following pancreatic cancer resection: a randomized controlled trial. JAMA. 2010; 304: 1073-81.
35. Versteijne E et al. Meta-analysis comparing upfront surgery with neoadjuvant treatment in patients with resectable or borderline resectable pancreatic cancer. Br J Surg. 2018; 105: 946-958.
36. Jang JY et al. Oncological Benefits of Neoadjuvant Chemoradiation with Gemcitabine Versus Upfront Surgery in Patients with Borderline Resectable Pancreatic Cancer: A Prospective, Randomized, Open-label, Multicenter Phase 2/3 Trial. Ann Surg. 2018; 268: 215-222.
37. Cassinotto C et al. locally advanced pancreatic adenocarcinoma: reassessment of response with CT after neoadjuvant chemotherapy and radiation therapy. Radiology 2014; 273: 108-16.
38. Oettle H et al. Adjuvant chemotherapy with gemcitabine and long-term outcomes among patients with resected pancreatic cancer: the CONKO-001 randomized trial. JAMA. 2013; 310: 1473-81.
39. Valle JW et al. Optimal duration and timing of adjuvant chemotherapy after definitive surgery for ductal adenocarcinoma of the pancreas: ongoing lessons from the ESPAC-3 study. J Clin Oncol. 2014; 32: 504-12.
40. Sonbol MB et al. Second-line treatment in patients with pancreatic ductal adenocarcinoma: A meta-analysis. Cancer. 2017; 123: 4680-4686.

Cite This Article: Chetibi, A., Ghemit, R., & Oualid, M. (2026). Adenocarcinoma of the Pancreatic Head: Results of Curative Treatment in a Series of 61 Cases. *East African Scholars J Med Surg,* 8(10), 410-415. https://doi.org/10.36349/easjms.2026.v08i10.003