

Case Report

A dental case- Extra oral discharging sinus with root decay dealt complementarily with Homoeopathy & Dental treatment

Dr. Tridibesh Tripathy¹, Dr. S.K. Kar², Dr. Umakant Prusty³ and Dr. Chitamani Nayak⁴

¹Homoeopathic, Public Health Expert & Subject Expert, Master of Public Health (Community Medicine) course, Department of Social Work, Lucknow University, Lucknow, UP, India

²Associate Professor Faculty of Dental Surgery, M.K.C.G. Medical College, Berhampur, Odisha, India

³Research officer (Homoeopathy), Regional Research Institute (Homoeopathy), Government of India, Puri, Odisha, India

⁴Asst. Professor, National Institute of Homoeopathy, Kolkata, West Bengal, India

Article History

Received: 21.05.2020

Accepted: 06.06.2020

Published: 16.06.2020

Journal homepage:

<https://www.easpublisher.com/easjdom>

Quick Response Code



Abstract: Many clinical trials & case control studies have been published about the effectiveness of Homoeopathic remedies for oral & maxio facial problems. In dentistry, Homoeopathic remedies have been proposed for oral ulcers, sialorrhoea, neuralgia, temporo mandibular joint disorders, xerostomia, oral lichen plannus & bruxism. It is incumbent on physicians to be aware of & to have working knowledge of complementary medicine that has become a rule rather than exception especially in dentistry. The current case is an example of this complementarity. Homoeopathy is useful for toothache, early dental abscess, dry socket, diseases of pulp & periapical region, trigeminal neuralgia, post-surgical bleeding, decay of milk teeth. The current case is such an example where both Allopathy & Homoeopathy systems of medicine were used simultaneously. One study mentions that Homoeopathic medicines can be taken together with allopathic drugs without causing interaction between them.

Keywords: clinical trials, oral ulcers, sialorrhoea, neuralgia.

Copyright @ 2020: This is an open-access article distributed under the terms of the Creative Commons Attribution license which permits unrestricted use, distribution, and reproduction in any medium for non commercial use (NonCommercial, or CC-BY-NC) provided the original author and source are credited.

INTRODUCTION

All Homoeopaths are basically General Practitioners (GP). As drugs are proved on the entire human being, the symptoms are elicited from all the parts of the body out of which the oral cavity, teeth, gums & the mandible related symptoms are elicited (Sarkar, B. K. 1984).

Subsequently, when these medicines are tried on patients with success on these areas, the field of dentistry in Homoeopathy evolved.

Various systems of the body work in tandem to maintain the dental health of the individual. Homoeopathy is a system of medicine that keeps various systems in harmony while treating a dental case (Sinha N *et al.*, 2015).

Homoeopathy is not a replacement for the skills of the dentist but is a vital adjunct in many cases. The remedies increase the patient's ability to heal & enable the patient to handle the dental experience with confidence (Wander, P. 2004).

CASE REPORT

The case was of a girl named Ms. Jyoti, aged 16 years who came to see the lead author in November 2017 with a complain of extra oral discharging sinus from the right side of the jaw since a month. She had pain in the site of the discharge & pain in the gums locally for the site under the discharge. She had been treated by local dentists with recurrent episodes of the discharge where the discharge subsided for few days after the treatment only relapse again. She came to see the lead author in the last week of November 2017.

The first prescription was Hepar Sulph-30 CH in one-dram globules number 40 sizes & Calcarea Sulph-6X, 15 grams in tablets to check the discharge & reduce the swelling³ & she was asked to report after 7 days. The dose of Hepar Sulph was 2 globules 4 times a day (morning, afternoon, evening, night) along with 4 tablets from Calcarea Sulph.

The discharge had reduced after 7 days & the second prescription was based on addressing the cause

of the discharge & on observation, it was found that these were from the root of the 6th & 7th teeth on the right side of the jaw. Using Allen's key notes (Allen, H. C. 1993), she was prescribed Acid Flour-30 CH in one-dram globules number 40 size where the dosage was same as mentioned above. The prescription was made on the basis of what Allen mentions in Acid Flour for tooth decay. As the case indicates decay of the roots of the teeth, the symptom was prioritized. Allen mentions in Acid Flour as given below.

Acid Flour- 'Rapid caries of teeth, fistula dentalis (Allen, H. C. 1993)'.

Along with Acid Flour, Mezereum- 30 CH was also prescribed in same amount & dose. This medicine was prescribed on the basis that the crowns of the teeth were intact & the roots were decayed.

Under Mercurius, Allen writes while comparing with Mezereum as per the sentence given below.

Mercurius- Crowns of teeth decay, roots remain (Crowns intact, roots decay- Mezereum) (Allen, H. C. 1993).

Clinically, Mezereum also controls pus (Allen, H. C. 1993). This was another dimension to prescribe Mezereum.

The doses of both the medicines were same as given above for other medicines.

The case reported back after a week & there was no discharge, no pain, no discomfort.

To prevent recurrence, the lead author again prescribed Calcarea Sulph-6x in the same dosage along with Thuja- 1000CH, one dram in globules number 40 size, 4 globules in one dose daily in the morning till the dram finished.

Thuja was prescribed as a constitutional medicine as the generalities of the patient matched Thuja while as a particular, the teeth related symptom also matched. Allen writes under Thuja as per the sentence given below.

Thuja- Teeth decay at the roots, crowns remain sound (Allen, H. C. 1993). When the case reported back, and very slight watery discharge had started to flow occasionally without any pain & discomfort.

The lead author referred the case to Dr. Kar, a practicing dentist in Lucknow who was also a faculty at Saraswati Dental College, Lucknow. He got the X-ray of the teeth done & found that the roots were decayed & infected. As the case had no swelling & discomfort, he extracted the teeth & the case recovered & the sinus healed.

The treatment adhered by the dentist is clearly supported by academic studies. The first study refers to the process of drainage of the said abscess in the case. It mentions that acute periapical abscesses drain along a path of least resistance through an intraoral or extraoral opening in the form of a sinus tract or spread to the deeper tissues causing facial space infection. The opening of the intraoral or extraoral sinus tracts depends on the path of the inflammatory process follows in relationship to muscle attachments of the face finally causing the perforation in the cortical plate. After formation of a sinus tract, the inflammation at the apex of the root may persist for a long period because of the drainage through the sinus tract, a chronic abscess can remain asymptomatic for extended period of time (Laskin, D.M. 1964).

The second study refers to the location of the sinus with the offending tooth. It mentions that most of the sinus tracts of dental aetiology are located intraorally. The extraoral dental sinus tract often is located in close relation to the offending tooth (Cioffi, G. A. *et al.*, 1986).

Finally, the treatment approach followed by the dentist also adheres to the academic angle. The related article cites that the treatment of these teeth depends on the overall health, cooperation, the tooth position, clinical and radiographic findings. The surgical and non- surgical modalities can be used to treat these cases. In the present case the concerned teeth had very poor prognosis, so surgical extraction was performed (Swales, K. L. *et al.*, 2016).

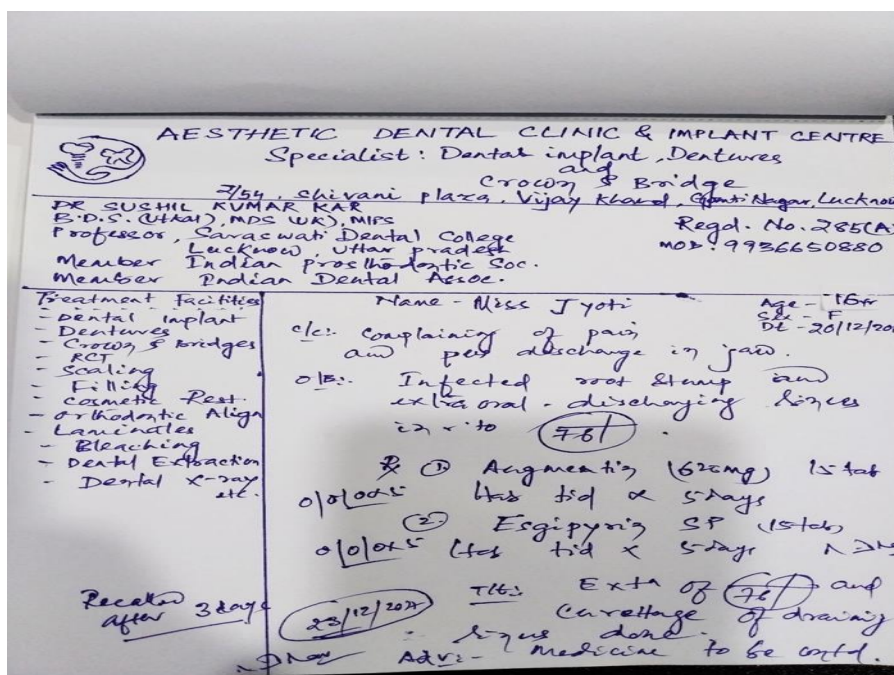


Figure 1. The Details of the Treatment

During the course of antibiotics & the post extraction period, the lead author prescribed Arnica-30 CH & Hypericum-30CH in one-dram quantity each in globules number 40 sizes. Dosages were same as above. The medicines were given to prevent any muscular or gum trouble & any nerve trouble respectively (Sivaraman, P. 1993).

Thereafter, having completed the course of antibiotics, the lead author prescribed her Calcarea Sulph-12X, in the same dosage & amount mentioned above along with Syphilinum-30CH as an anti syphilitic on the basis of miasmatic prescription(Sarkar, B. K. 1984).The amount & dosage was like the one-dram medicines explained above. This prescription was given to nullify chances of any recurrence & to prevent the other teeth (Sarkar, B. K. 1984).

CONCLUSION

The case is a classic example of benefits of medical pluralism where the professionals need to have an open mind to complement systems of medicine for better benefits of the society. Surgical procedures of the dentistry science can be complemented through integration of homoeopathic medicine in pre & post stage of surgery as the case demonstrated. As in all the fields, inclusion & not exclusion should be the principle for optimization of benefits. The dissemination of the case study among the professionals is expected to enhance the principle of inclusion.

Acknowledgement

The lead author thanks Dr. Kar for providing inputs in the case as a dentist & for treating the case. His inputs are for the non-Homoeopathic portions of the

case. The lead author also thanks Dr. Prusty & Dr. Nayak for their inputs in the Homoeopathic section.

Conflict of Interest

Nil

Funding

Nil

Declaration

The authors declare that their opinions are suggestive in nature & that the approach was specific to the case. It may be noted that Dr. Kar was at Lucknow in 2017. His current designation is given in the citation.

REFERENCES

- Allen, H. C. (1993). Key notes and characteristics with comparisons of some of the leading remedies of the Homoeopathic Materia Medica with Bowel Nosodes, Reprint edition, B. Jain publishers Pvt. Ltd.
- Bhateja, S., Arora, G., & Mahna, R. (2013). Complementary & Alternative Therapy In Dentistry: "Homeopathy"-A Review.
- Cioffi, G. A., Terezhalmay, G. T., & Parlette, H. L. (1986). Cutaneous draining sinus tract: an odontogenic etiology. *Journal of the American Academy of Dermatology*, 14(1), 94-100.
- Darby, P. (2011). How Homoeopathy can be used in dental practice? *Dent Nurs*. 7, 634-637.
- Fischer, R.D. (1985). Dentistry & Homoeopathy, an overview, *J Am Inst Homoeopath*, 78,140-7.
- Goel, P., Torwane, N. A., Hongal, S., & Chandrashekar, B. R. (2014). Homeopathic

- Medicine-An Adjuvant for Dentistry: A Review. *IAMJ*, 2(2), 203-10.
7. Hoseinishad, M., Nosratipour, A., Moghaddam, S. M., & Khajavi, A. (2015). Homeopathy in dentistry: A review. *Int J Contemp Dent Med Rev*, 2015, 1-5.
 8. Laskin, D.M. (1964). Anatomic considerations in diagnosis and treatment of odontogenic infections. *J Am Dent Assoc*, 69, 308-316
 9. Newadkar, U., Chaudhari, L., & Khalekar, Y. (2016). Homeopathy in dentistry: Is there a role?. *Pharmacognosy research*, 8(3).
 10. Sarkar, B. K. (1984). *Organon of Medicine* by Hahnemann, M. Bhattacharya & Co. 1st edition 1955, 8th edition.
 11. Sinha N et al, (2015). Review of the role of Homoeopathic application in dentistry. *Int J Oral Health Med Res*. 2(4), 77-80.
 12. Sivaraman, P. (1993). Tooth troubles cured with Homoeopathic medicines, B. *Jain Publishers pvt.ltd.*
 13. Swales, K. L., Rudralingam, M., & Gandhi, S. (2016). Extraoral cutaneous sinus tracts of dental origin in the paediatric patient. A report of three cases and a review of the literature. *International Journal of paediatric dentistry*, 26(5), 391-400.
 14. Thierry, C. (2011). Can Homoeopathy & Allopathy be taken together? *Hpathy Ezine*, March 2011.
 15. Wander, P. (2004). How Homoeopathy can help make dental treatment more comfortable, Dental Homoeopathy, *British Homoeopathic Association*.