

## Case Report

# Chronic Trapezo-metacarpal Instability Treated with Eaton-Littler's Ligamentoplasty -A Case Report

M. El Abdi<sup>1\*</sup>, H. Zejjari<sup>2</sup>, R. Roukhsi<sup>3</sup>, J. Louaste<sup>2</sup>, L. Amhajji<sup>2</sup>

<sup>1</sup>Orthopaedic Surgeon, Department of Orthopaedic Surgery, Military Hospital of Laayoun, Morocco

<sup>2</sup>Professor, Department of Orthopaedic Surgery, Military Hospital of Meknes, Morocco

<sup>3</sup>Professor, Department of Radiology, Military Hospital of Laayoun, Morocco

### Article History

Received: 13.12.2020

Accepted: 29.12.2020

Published: 11.01.2021

### Journal homepage:

<https://www.easpublisher.com>

### Quick Response Code



**Abstract:** The trapezo-metacarpal dislocation is an uncommon event. Usually caused by indirect mechanism. We present a case of a 26-year-old man patient who developed a chronic instability of the right thumb carpometacarpal joint, after two episodes of recurrent dislocation. The patient underwent rewarding management by Eaton-Littler's ligamentoplasty technique using flexor carpi radialis tendon. Functional result was satisfactory.

**Keywords:** Carpometacarpal joint instability, Thumb, Eaton-Littler's ligament reconstruction.

Copyright © 2021 The Author(s): This is an open-access article distributed under the terms of the Creative Commons Attribution 4.0 International License (CC BY-NC 4.0) which permits unrestricted use, distribution, and reproduction in any medium for non-commercial use provided the original author and source are credited.

## INTRODUCTION

The thumb carpometacarpal (CMC) joint is a very mobile joint whose articular surfaces are biconcaves [1-2]. Joint stability is provided by a complex ligament system reinforced by five ligaments [2-4].

Trapeziometacarpal dislocation is a rare lesion [2, 4-6]. Left neglected or even following closed treatment; this injury can be complicated by the instability joint to trapeziometacarpal osteoarthritis, also known as osteoarthritis at the base of the thumb or as rhizarthrosis [1, 3, 6, 7]. A variety of therapeutic options of ligament reconstruction are described [4, 8].

We report a case of thumb carpometacarpal instability treated by Eaton-Littler's ligamentoplasty technique. We describe the technique and we present the result at 24 months follow-up evaluation.

## CASE REPORT

A 26-year-old soldier, right hand dominant was admitted with instability of the right thumb carpometacarpal joint. Her surgical history included a closed traumatic dislocation of the thumb CMC joint in January 2017 treated by closed reduction with

percutaneous pinning for 45 days. 15 months later in april 2018, he sustained a second closed dislocation following another injury to his right hand. He received same treatment.

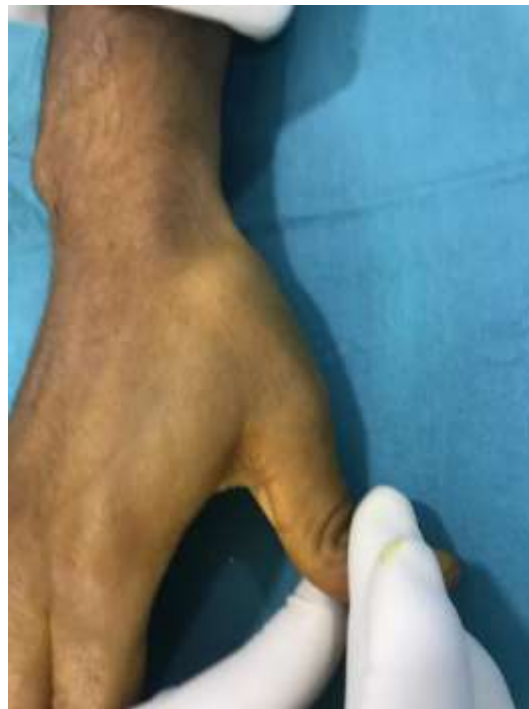After metal implant removal, the patient presented pain and impaired thumb pinch strength with the feeling of the thumb CMC joint moving when doing basic activities. Physical examination revealed small deformity at the base of the thumb. Provocative ligament testing was positive (Fig-1). X ray demonstrated a trapeziometacarpal subluxation without joint degeneration. CMC joint instability diagnosis was retained. This prompted to apply a Eaton-Littler's ligament reconstruction by Wagner thenar surgical approach (Fig-2).

The patient underwent harvesting of a hemi flexor carpi radialis tendon by separate incisions in the forearm without its disinsertion on the base of the index metacarpal M2. Hemi tendon transfer was carried through an extra-articular bone tunnel located 1 cm to the thumb metacarpal base and parallel to its articular surface, then was sutured at bifurcation point of the FCR with good tension to obtain a correction the instability. First commissural space of the hand was

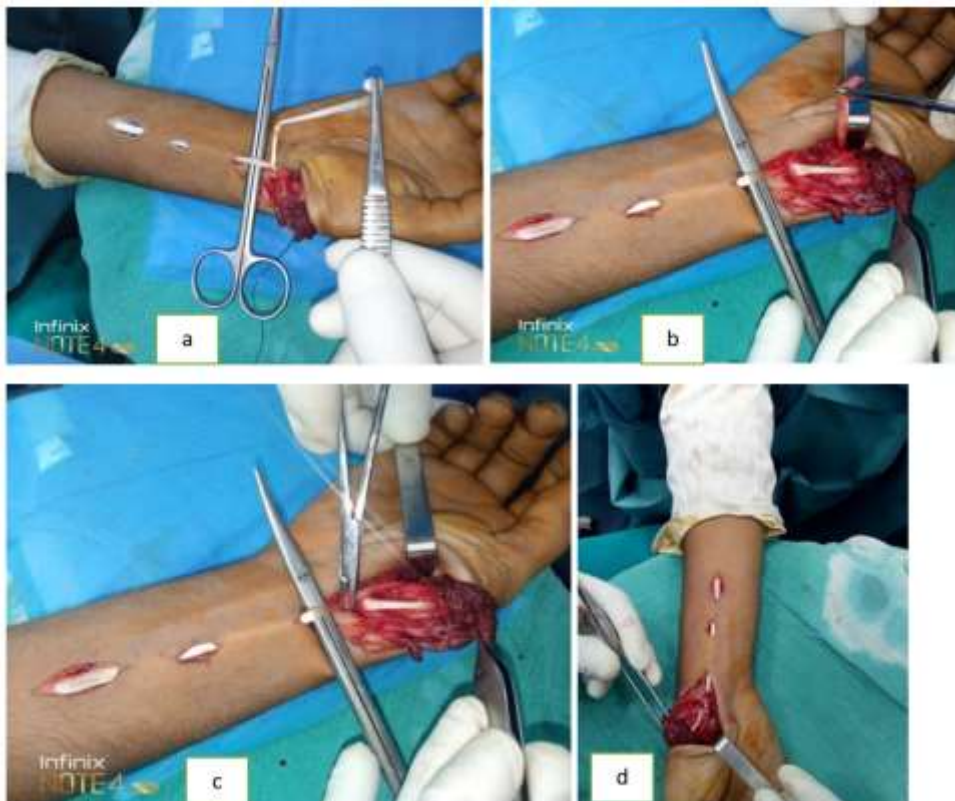
fixed by 2 intermetacarpal Kirschner wires M1M2 (ISELIN technique) for 6 weeks (Fig-3).

The patient began rehabilitation therapy, which improved gradually thumb motions. 24 months

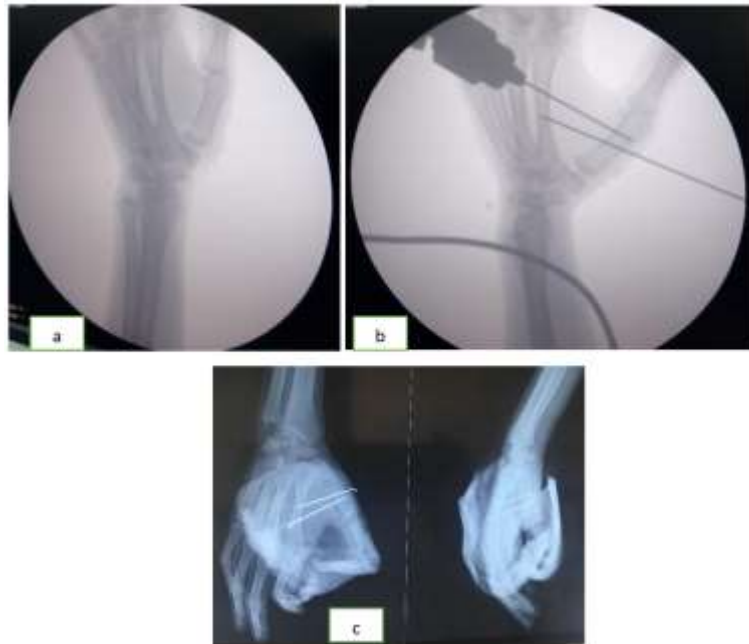postoperatively, at the periodic consultations and at the radiological follow-up, the patient had no recurrence with comfortable function of the hand (Fig 4 and 5).



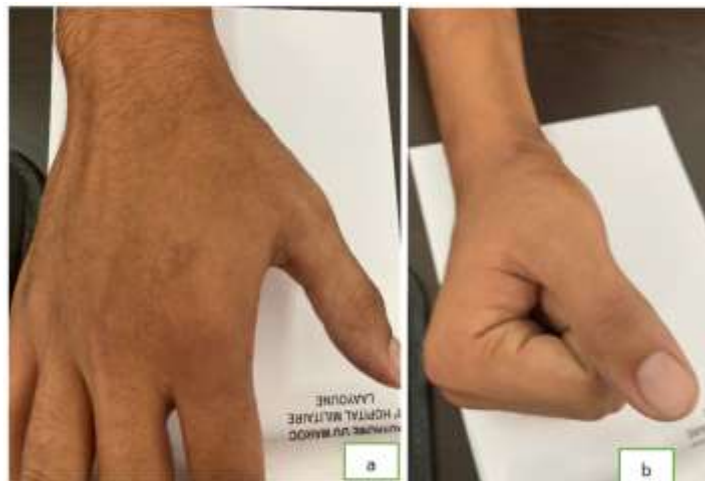**Fig-1:** Clinical aspect revealing provoked trapeziometacarpal dislocation



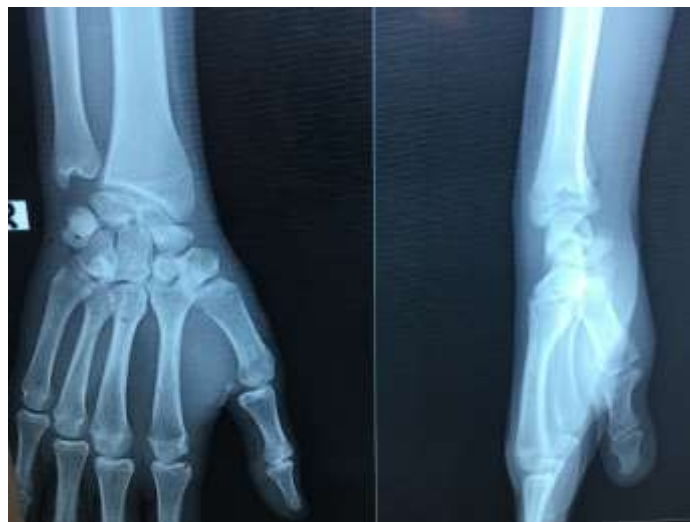**Fig-2(a, b, c and d):** Eaton-Littler's ligament reconstructive surgery showing FCR tendon harvesting, its slip through the bone tunnel, and bifurcation point suture



**Fig-3(a, b, c):** Kirschner wires fixation of first committal space (ISELIN technique). X-ray appearance



**Fig-4(a, b):** Postoperative result showing the proper recovery



**Fig-5:** Radiological control after removal of material objectifying good articular congruency at the carpometacarpal joint of the thumb

## DISCUSSION

The trapeziometacarpal joint plays a fundamental role on the thumb opposition. This mechanism grants system of gripping of the hand that has an important functional value [1, 3].

The articular surfaces are biconcave saddle [1, 2]. The range of motions determined by several surrounding ligaments [2-4]. Although ligamentous structures support the CMC joint of thumb, the authors consider that two main stabilizers prevent dislocation, the anterior oblique ligament or the beak according Eaton and Littler [3, 6, 9, 10], and the dorsoradial ligament according other studies [1, 6, 11].

Dislocation of the trapeziometacarpal joint is a rare occurrence, that account for 1 % of all hand injuries [2, 4-6]. However, it can cause a residual instability, which is a source of rhizarthrosis [1, 3, 6, 7].

Our case represents an post-traumatic instability of the thumb carpometacarpal joint, the diagnosis is evoked in front of a chronic pain and localized swelling with decreased grip force [9, 12]. Conventional X-ray using the method by Kapandji is fundamental to the practice of diagnostic imaging [13-15]. Stress radiographs appreciate articular laxity and reduction quality [4, 15]. This plain radiographs does have limitations, however, we suggest that the context of recurrent dislocation is sufficient to make a diagnosis of joint instability and suspect ligament injuries.

For chronic instability secondary to recurrent dislocation of 1st CMC, the therapeutic choice is based on ligament reconstruction with or without pinning [8, 16-18]. The aim of this surgery pattern is to obtain a stabilized correction without decreased joint amplitudes.

Several surgical interventions have been proposed, using different ligaments (abductor pollicis longus, extensor carpi radialis longus, palmaris longus, flexor carpi radialis FCR, and even palmar carpal ligament) [9, 10, 12, 19-21]. The variety of recommended surgical techniques underlines the authors' difficulty in identify an appropriate therapeutic response. We describe a condition of trapeziometacarpal instability which has benefited the Eaton-Littler's ligamentoplasty using FCR tendon. This surgical method provided a better result, by deformity correction and restoring of thumb function.

## REFERENCES

1. Edmunds, J. O. (2011). Current concepts of the anatomy of the thumb trapeziometacarpal joint. *The Journal of hand surgery*, 36(1), 170-182.
2. Sawalha, S. (2008). Volar dislocation of the thumb carpometacarpal joint: A case report. *Injury extra*, 39(10), 332-4.
3. Imaeda, T., An, K. N., Cooney III, W. P., & Linscheid, R. (1993). Anatomy of trapeziometacarpal ligaments. *The Journal of hand surgery*, 18(2), 226-231.
4. Glickel, S., Barron, A., & Catalano, L. (2005). Dislocations and ligament injuries in the digits. In: Green, D., Hotchkiss, R., Pederson, W., Wolfe, S. (editors). *Green's operative hand surgery*. 5th ed. Philadelphia, Pennsylvania: Churchill livingstone. 382-6.
5. Hove, L. M. (1993). Fractures of the hand: distribution and relative incidence. *Scandinavian journal of plastic and reconstructive surgery and hand surgery*, 27(4), 317-319.
6. Strauch, R. J., Behrman, M. J., & Rosenwasser, M. P. (1994). Acute dislocation of the carpometacarpal joint of the thumb: an anatomic and cadaver study. *The Journal of hand surgery*, 19(1), 93-98.
7. Pequignot, J. P., Giordano, P., Boatier, C., & Allieu, Y. (1988, January). Luxation traumatique de la trapézo-métacarpienne. In *Annales de Chirurgie de la Main* (Vol. 7, No. 1, pp. 14-24). Elsevier Masson.
8. Pizon, A. F., & Wang, H. E. (2010). Carpometacarpal dislocation of the thumb. *J Emerg Med*. 38(3):376-7.
9. Eaton, R. G., & Littler, J. W. (1973). Ligament reconstruction for the painful thumb carpometacarpal joint. *JBJS*, 55(8), 1655-1666.
10. Eaton, R. G., Lane, L. B., Littler, J. W., & Keyser, J. J. (1984). Ligament reconstruction for the painful thumb carpometacarpal joint: a long-term assessment. *The Journal of hand surgery*, 9(5), 692-699.
11. Van Brenk, B., Richards, R. R., Mackay, M. B., & Boynton, E. L. (1998). A biomechanical assessment of ligaments preventing dorsoradial subluxation of the trapeziometacarpal joint. *The Journal of hand surgery*, 23(4), 607-611.
12. Takwale, V. J., Stanley, J. K., & Shahane, S. A. (2004). Post-traumatic instability of the trapeziometacarpal joint of the thumb: diagnosis and the results of reconstruction of the beak ligament. *The Journal of bone and joint surgery. British volume*, 86(4), 541-545.
13. Kapandji, A. (1980). La Radiographie Spécifique De L'articulation Trapezo-Métacarpienne: Sa Technique, Son Interet. *Ann Chir*, 9:719-726.
14. Brunelli, G., Monini, L., & Brunelli, F. (1988). Trapeziometacarpal stabilisation in arthrosis. *Italian journal of orthopaedics and traumatology*, 14(3), 363-368.
15. Chiavaras, M. M., Harish, S., Oomen, G., Popowich, T., Wainman, B., & Bain, J. R. (2010). Sonography of the anterior oblique ligament of the



- trapeziometacarpal joint: a study of cadavers and asymptomatic volunteers. *American Journal of Roentgenology*, 195(6), W428-W434.
16. Okita, G., Anayama, S., Sato, N., & Haro, H. (2011). Surgical reconstruction using suture anchor for dislocation of the carpometacarpal joint of the thumb: a case report. *Archives of orthopaedic and trauma surgery*, 131(2), 225-228.
  17. Fotiadis, E., Svarnas, T., Lyrtzis, C., Papadopoulos, A., Akritopoulos, P., & Chalidis, B. (2010). Isolated thumb carpometacarpal joint dislocation: a case report and review of the literature. *Journal of orthopaedic surgery and research*, 5(1), 16.
  18. Bosmans, B., Verhofstad, M. H. J., & Gosens, T. (2008). Traumatic thumb carpometacarpal joint dislocations. *The Journal of hand surgery*, 33(3), 438-441.
  19. Brunelli, G., Monini, L., & Brunelli, F. (1989). Stabilisation of the trapezio-metacarpal joint. *The Journal of Hand Surgery: British & European Volume*, 14(2), 209-212.
  20. Lahiji, F., Zandi, R., & Maleki, A. (2015). First carpometacarpal joint dislocation and review of literatures. *Archives of Bone and Joint Surgery*, 3(4), 300-303.
  21. Iyengar, K., Gandham, S., Nadkarni, J., & Loh, W. (2013). Modified Eaton-Littler's Reconstruction for Traumatic Dislocation of the Carpometacarpal Joint of the Thumb—A Case Report and Review of Literature. *Journal of hand and microsurgery*, 5(1), 36-42.

**Cite this article:**

M. El Abdi *et al* (2021). Chronic Trapezo-metacarpal Instability Treated with Eaton-Littler's Ligamentoplasty -A Case Report. *EAS J Orthop Physiother*, 4(1), 1-5.