

## Original Research Article

# Comparative Study of the Surgical Treatment of Congenital Club Foot between McKay and Turco Procedure

Dr. Mohammad Sazzad Hossain<sup>1\*</sup>, Dr. Sharif Md. Musa<sup>1</sup><sup>1</sup>Medical Officer, Department of Orthopaedic Surgery, Bangabandhu Sheikh Mujib Medical University, Dhaka, Bangladesh**Article History**

Received: 24.06.2023

Accepted: 29.07.2023

Published: 17.08.2024

**Journal homepage:**<https://www.easpublisher.com>**Quick Response Code**

**Abstract: Background:** Congenital clubfoot is one of the common congenital disorders. Surgery plays an important role in the treatment of patients with this deformity. Comparative studies after surgical treatment might be beneficial. **Hypothesis:** Surgical treatment of congenital idiopathic club foot by McKay procedure gives better results than Turco procedure. **Objectives:** To compare the outcome of surgical treatment of congenital idiopathic club foot between McKay procedure and Turco procedure. **Methods:** This is a prospective interventional study carried out at Orthopaedic Department of Bangabandhu Sheikh Mujib Medical University, Shahbag, Dhaka, during the period of January 2007 to December 2008. 25 patients with 36 feet were selected in which Group-I consisted of 13 patients with 19 feet treated with surgery by McKay's procedure and Group- II consisted of 12 patients with 17 feet treated with surgery by Turco's procedure. All the ethical considerations were fulfilled. A questionnaire was designed and prepared by the researcher himself. Diagnosis was confirmed by detailed medical history, clinical examinations and relevant investigations. Then through Turco or cincinnati incision surgery was done in two groups. Statistical analysis were done by SPSS (Statistical Package for the Social Science). **Results:** There were satisfactory results (Excellent + Good) in 17 feet (89.47%) and unsatisfactory results (fair + poor) were in 2 feet (10.53%) in McKay's procedure. Where as satisfactory results (Excellent + Good) were in 9 feet (52.94%) and unsatisfactory results (fair + poor) were in 8 feet (47.06%) in Turco's procedure. **Conclusion:** Operative treatment of congenital clubfoot deformity is always an accepted method of treatment. The final outcome of the results shows that in McKay's procedure satisfactory results was found in 89.47% which is more than Turco's procedure 52.94%.

**Keywords:** Congenital clubfoot, Comparative studies, Turco procedure, surgery.

**Copyright © 2024 The Author(s):** This is an open-access article distributed under the terms of the Creative Commons Attribution **4.0 International License (CC BY-NC 4.0)** which permits unrestricted use, distribution, and reproduction in any medium for non-commercial use provided the original author and source are credited.

## INTRODUCTION

Congenital club foot is a variable three-dimensional deformity of a complex system of joints [1]. Secondary and adaptive structural changes involving skeletal and soft tissues are already well established at birth and radiography is unhelpful in the first year of life. The assumptions are that the essential deformities in the mid-tarsal joints; that the other elements of the deformity. Including varus deformity of the heel, are secondary and adaptive; and that all correction of the primary deformity combined with adequate release of all contracted soft tissues will yield a reasonably normal foot. The history of clubfoot dates back to the Hippocrates period. Since then for centuries surgeons dealt with this subject regarding its etiology,

pathoanatomy and management gaining varied opinion. It was not until 1831 when Stroneyer began using tendoachiles lengthening that surgery became the part of the management of clubfoot [2].

The importance of early treatment of clubfoot is worth nothing "start the treatment before the delivery of head breech presentation" [3].

The incidence of congenital club foot is 1 to 2 per 1000 live births. It has a male predominance of 2:1 and bilateral in 49 percent of cases, 29% has right foot and 22% has left foot affection [4]. It is a multifactorial (Polygenic) disorder but in some cases, it is transmitted as an autosomal dominant pattern with incomplete (40%)

\*Corresponding Author: Dr. Mohammad Sazzad Hossain

Medical Officer, Department of Orthopaedic Surgery, Bangabandhu Sheikh Mujib Medical University, Dhaka, Bangladesh

penetrance [5]. CTEV is associated with joint laxity, congenital dislocation of the hip, tibial torsion, absence of some tarsal bones and a history of other foot anomalies in the family [6].

The classification of congenital club foot is related to the severity of involvement [7]. Club foot deformity may be divided into three parts; adduction, inversion and equinus deformities. The fore foot is adducted when compared with the hind foot.[8] The OS calcis is related inward under the astragalus, causing the entire foot to assume an inverted position. The equinus deformity may be divided into two parts. The forefoot is plantar-flexed when compared to the hind foot, giving "forefoot equinus". The entire foot is plantar-flexed in the ankle joint, giving "ankle equinus". Each of these three deformities must be completely corrected in the order mentioned. The postural or mild club foot is uncommon and can be corrected possibly with little difficulty. The moderate club foot is fairly supple, a transverse crease is absent and the heel is easily definable. Fortunately a foot in their group which is the target, respond most often to gentle manipulation or realignment followed by the application of a corrective plaster cast [10]. Severe club foot always requires surgical correction [9]. The foot is quite short, exhibits transverse crease in the sole and has vary tight skin.

The goal of treatment of congenital club foot is a functional, pain free, plantigrade foot, with good mobility and without callosity, that does not necessitate the wearing of modified shoes [11]. Most authors still agree that all congenital club foot initially should be treated non-operatively the initial treatment consist of daily manipulation of the foot, without anaesthesia, for three months, followed by adhesive-tape strapping of the foot in the position of correction [12, 13]. If the deformity did not respond to this regimen after three months, surgical, intervention was advised [14]. In planning the surgical correction of the club foot, it is important to remember that equinus, varus and adduction occur simultaneously rather than as separate isolated movements of the foot and ankle [15].

Operating at an earlier age have suggested that realignment of the talus, calcaneus, and the navicular results in better remodeling of the articular surfaces. The surgical procedure that are currently in use can be divided into three basic groups. Those that involve soft tissue. Those that involve bone and combined soft tissue and bone procedures. Procedures that involve bone are usually done in older children and sometimes regarded as salvage procedure [14]. There are different procedure for the operative treatment of congenital club foot - the posteromedial release as the Turco procedure, the posteromedial and limited lateral release as the carroll procedure and the full posteromedial lateral release as the McKay procedure [16]. Turco introduced the one stage soft tissue posteromedial release which is still used widely today. The posterior medial and subtalar soft

tissue contractures are released to permit the realignment of the abnormal anatomy of the bones and the corrected alignment is secured with a single kirschner wire, which transfixes the talonavicular joint. Meckay one stage subtalar soft tissue release is, in effect, a circumferential soft tissue release involving the posterior, medial, lateral and planter aspects of the foot. Which is designed particularly to correct the horizontal subtalar rotation of the calcaneus that is associated with congenital club foot [14]. In 1985, Simons compared the results of the McKay one stage circumferential release with those of the Turco one-stage posterior medial release. They noted that in the McKay procedure a transverse circumferential incision is used, the transverse plane deformity corrected by a complete subtalar release and early motion of the foot is permitted by the use of a hinged cast [17]. They concluded that the patients who has the McKay procedure appeared to have better results compared with those who had the posteromedial release, complications involving the wound occurred less frequently, correction was more complete and the range of motion was greater [14].

The posteromedial release, as described by Turco, has gained wide popularity since its introduction in 1971. It has often failed to produce complete correction, however, and in some feet it has produced overcorrection [18].

The complete subtalar release or McKay technique provides more satisfactory results than the posteromedial release [18]. A greater degree of correction is attained with the complete subtalar release (both clinically and radiographically), superior alignment of the foot and knee is achieved and the incidence of complication is less.

In Turco, the foot is approached by a single, medial incision extending from the base of the first metatarsal proximally under the medial malleolus to the Achilles tendon. The lateral extent of the posterior release in a blind transaction of the talofibular and calcaneofibular ligament. Both the Achilles tendon and posterior tibial tendon are lengthened and only the sheaths of the flexor digitorum longus and flexor hallucis longus tendons are resected.

Most recently, McKay presented his theories of morbid anatomy and surgical approach to the club foot in 1982 and 1983.[16] He related a radically different concept by explaining foot the underlying structural problem of the clubfoot was a rotational deformity in the subtalar complex consisting of three joints (The talocalcaneal, talonavicular and calcaneal cuboid joints) in which the calcaneus moved medially under the head of the talus anterior to the ankle joint and laterally toward the fibular malleolus posterior to the ankle joint. McKay recommends operating on the club foot early, as early as age 2 months, and for the same reasons. Early operation maximizes preservation of articular cartilage and

promotes growth of the talus. Operatively, the foot is approached through the transverse Cincinnati incision that extends medially from the base of the first metatarsal around the heel laterally to the level of the calcaneal cuboid joint. This incision, especially laterally, affords a direct view and complete release of the lateral ankle and subtalar joints as well as the calcaneal cuboid joint.

Out of the congenital deformities clubfoot is the most common that are found in Orthopaedic Out Patient Department, BSMMU, Dhaka. A good number of cases usually come to us late due to illiteracy, lack of health education, ignorance, poverty, superstitions, communications gap, maltreatment by indigenous method etc. the results of surgery as a whole, is satisfactory provided the appropriate type for each case is employed. Patients need postoperative serial plaster, club foot shoe and follow up, as there may be postoperative complications and recurrence until the child is school going. In the present time many surgeons have accepted a less invasive surgery as the method of choice in the treatment of rigid type of congenital talipesquinovarus deformity [19].

This prospective study regarding surgical treatment of congenital clubfoot by McKay and Turco procedure to compare the final outcome after surgical treatment of both this procedure might be beneficial for our people. Henceforth this study was undertaken to compare the surgical treatment of congenital clubfoot by McKay and Turco procedure.

## OBJECTIVES

To compare the outcome of surgical treatment of congenital idiopathic club foot between McKay procedure and Turco procedure.

## METHODS

This is a prospective interventional study carried out at orthopaedic department of Bangabanghu Sheikh Mujib Medical University, Shahbag, Dhaka during the period of January 2007 to December 2008. 25 patients with 36 feet were selected in which Group-I consisted of 13 patients with 19 feet treated with surgery

by McKay's procedure and Group- II consisted of 12 patients with 17 feet treated with surgery by Turco's procedure. All the ethical considerations were fulfilled. A questionnaire was designed and prepared by the researcher himself.

### Inclusion Criteria:

1. Child having congenital idiopathic club foot.
2. Age of child from 3 months to 3 years.
3. Both sex.
4. Unilateral or bilateral clubfoot.
5. Rigid type of club foot.

### Exclusion Criteria:

1. Age below 3 months and above 3 years.
2. Non rigid type of club foot.
3. Resistant rigid type of club foot.
4. Relapsed club foot.

### Statistical Analysis:

Collected data were managed by the following steps:

- Collected data were edited manually.
- Then it were entered into a SPSS computer software program.
- The entered data were checked and verified.
- Data were analyzed by computer bases program SPSS (Statistical Package for Social Science).

## RESULTS

During the period extending from January 2007 to December 2008 a total number of 25 patients with congenital club foot were selected as per inclusion criteria. Therefore 25 cases with 36 feet were available for comparison. Out of 36 feet 19 feet were treated with surgery by McKay procedure and 17 feet were treated with surgery by Turco procedure. All the relevant findings have been presented as tables and figures.

Table 1 showing distribution of patients by age. The majority percents of the patients were 06-11 age group. In McKay's procedure it was 30.76% and in Turco's procedure it was 33.33%. Next common age group was 12-17 age group. In McKay's procedure it was 23.07% and in Turco's procedure it was 25.0%.

**Table 1: Age distribution of patients (n=25)**

Age group (Months)	McKay's procedure No. (%)	Turco's procedure No. (%)
Upto 5	02(15.38)	01(8.33)
6-11	04(30.76)	04(33.33)
12-17	03(23.07)	03(25.0)
18-23	02(15.38)	02(16.66)
24-30	01(7.69)	01(8.33)
31-36	01(7.69)	01(8.33)

Table 2 showing the comparison of age between 2 groups. In McKay's procedure mean age was 14.76 ±9.36 and in Turco's procedure mean age was

15.59±9.59. Student t-test reveals no statistically significant difference (p. > 0.05).

**Table 2: Comparison of age in 2 groups**

	Mean ± SD	t-value	p-value
McKay's procedure	14.76 ± 9.36	1.31	0.091
Turco's procedure	15.59 ± 9.59		

Table 3 showing the distribution of the patient's operative procedure and sex. In Turco group 75% were male and 25% were female. In McKay's group 61.53% were male and 38.46% were female. No statistically

significant association was found in sex distribution of the patients of different groups through Pearson  $\chi^2$  test ( $\chi^2= 1.312$ ,  $df=1$ ,  $p= 0.67$ ).

**Table 3: Sex distribution of patients (n=50)**

Sex	McKay's procedure No. (%)	Turco's procedure No. (%)	P value
Male	08(61.53)	09(75.0)	0.67
Female	05(38.46)	03(25.0)	

Table 4 showing that in McKay's procedure right foot involvement in 4(21.05%) patients, left foot involvement in 3(15.80%) patients and both foot involvement in 6(31.5%) patients. In Turco's procedure

right foot involvement in 4(23.50%) patients, left foot involvement in 3(17.65%) patients and both foot involvement in 5(58.85%) patients.

**Table 4: Distribution by side involvement**

Side of involvement	McKay's Procedure N=19		Turco's Procedure N=17	
	No.	%	No.	%
Right foot	04	21.05	04	23.50
Left foot	03	15.80	03	17.65
Both foot	06	31.5	05	58.85
Total foot	19	100.0	17	100.0

Table 5 showing that in McKay's procedure unilateral foot involvement in 7(36.85%) patients and bilateral foot involvement in 6(31.5%) patients. In

Turco's procedure unilateral foot involvement in 7(41.18%) patients and bilateral foot involvement in 5(58.82%) patients.

**Table 5: Distribution by foot involvement**

Type	McKay's Procedure N=19		Turco's Procedure N=17	
	No.	%	No.	%
Unilateral	07	36.85	07	41.18
Bilateral	06	31.5	05	58.82
Total Foot	19	100.0	17	100.0

Table 6 showing distribution of the patients by Complications (late). Among this patients Stiffness 01(7.69) of McKay's procedure, 01(8.33) of Turco's

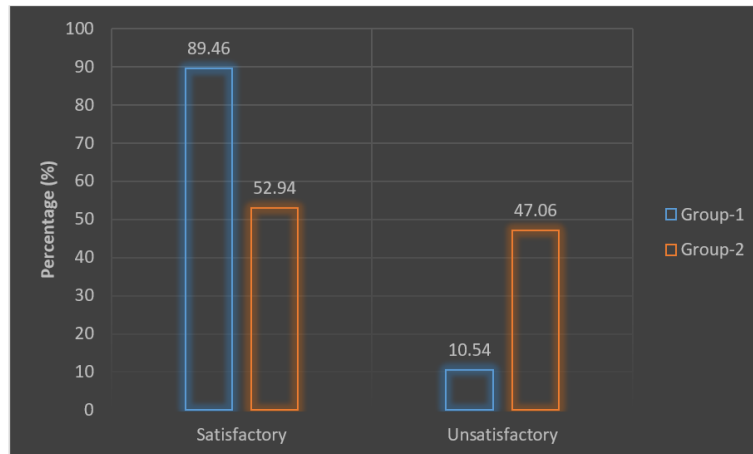
procedure, Deformity 01(7.69) of McKay's procedure, 02(16.66) of Turco's procedure. p value was 0.893, that was not statistically significant.

**Table 6: Postoperative complications (Late)**

Complication (late)	McKay's procedure	Turco's procedure	P value
Stiffness	01(7.69)	01(8.33)	0.893
Deformity	01(7.69)	02(16.66)	

Figure 1 showing distribution of the final outcome. In McKay's procedure 89.46% had satisfactory outcome and 10.54% had unsatisfactory outcome. In

Turco's procedure 52.94% had satisfactory outcome and 47.06% had unsatisfactory outcome. Fisher's exact test reveals statistically significant difference.  $p < 0.05$ .



**Figure 1: Comparison of final satisfactory (Excellent + Good) and unsatisfactory (Fair + Poor) results in McKay’s Procedure and in Turco’s Procedure**

## DISCUSSION

In the present study 7 patients (in both Group-I and Group-II) had a positive family history of clubfoot (28%) out of 25 patients.

In the present study 5 patients had (in both Group-I and Group-II) other congenital anomalies (25%) out of 25 patients of rigid type of clubfoot deformity. In Group- I, 1 patient had syndactyly and 2 patients had cleft lip and in Group-II, 1 patient had syndactyly and 1 patient had cleft lip.

In the present study there were 8 male and 5 female in Group-I and 9 male and 3 female were in Group-II. Total male were 17 (68.0%) and female were 8(32.0%). There are more male patients than in the studies (53.4%), (84.62%), (66.67%) [20].

Unilateral clubfoot was found in 7 patients in Group-I and 7 patients in Group- II. Total 14 patients (56.6%) in both Group-I and Group-II and bilateral involvement was found in 6 patients in Group-I and 5 patients in Group-II. Total 11 patients (44.0%) in both Group-I and Group-II. Bilateral involvement is higher than 60.0% and 65.38% but nearer to 46.16% and 42.6% [20, 21].

In the present series, the age of the patients in Group-I varied from 3 months to 36 months (3 years) with a mean of 14.76 ±SD 9.36 months And in Group-II the age varied from 3 months to 36 months (3 years) with a mean of 15.91±SD9.59 months. In Group-I 13 patients with 19 feet were treated with surgery by McKay’s procedure and in Group-II 12 patients with 17 feet were treated with surgery by Turco’s procedure.

In this study most patients belong to age group 6-11 months (30.76%) in Group-I and 33.33% in Group-II. While the next common age group belong to 12-17 months (23.07% in Group-I) and (25% in Group-II).

Of the total 13 cases in Group-1 4 feet (30.76%) were involved in right side and 3 feet (25%) were involved in left side.

In this study out of 25 cases 13 cases (52%) were treated with surgery by McKay’s procedure and 12 cases (48%) were treated with surgery by Turco’s procedure.

For the expected result selection of cases, pre-operative plaster cast, aseptic and expertise surgical technique, post operative cast immobilization, regular attendance postoperatively for a long time is a prerequisite.

Patients were finally evaluated clinically and radiologically between 3-4 months and 6-8 months postoperatively, respectively. The results between the two groups were compared. The mean follow-up period was in Group- I 18.92±SD2.39 months (range 5 to 13 months) and the mean follow-up period was in Group- II 12.08± SD4.07 months (range 6 to 17 months).

In Group- I Excellent results were obtained 15 feet (78.94%) and good results were obtained in 2 feet (10.52%), so satisfactory (Excellent + Good) results were obtained in 17 feet (89.47%) and unsatisfactory (Fair + Poor) in 2 feet (10.53%). In Group- II excellent results were obtained in 07 feet (41.18%) and good results were obtained in 02 feet (11.76%). So satisfactory obtained in 02 (Excellent+good) results were in 9 feet (52.94%) and unsatisfactory (Fair+poor) results were obtained in 8 feet (47.06%). Soft tissue release in 55 feet with average 3 years 2 months follow up. Good to Excellent results were in 82% cases and fair to poor results were in 18% cases [22].

Clubfoot surgery through three different procedures between 1981 to 1985 at Columbus Children Hospital with a follow-up of 16 months [16]. They showed satisfactory results 48% by Turco procedure,

62.5% by McKay procedure and 45.8% by Carol procedure.

In the present study early post-operative complications developed in 3 cases (23.07%) in Group-I, among them blister in 1 patient (7.69%, case no- 7), skin necrosis in 1 patient (7.69%, case no- 9) and skin infection in 1 patient (7.69%, case no- 11).

In Group-II early postoperative complications developed in 4 cases (33.33%), among them blister in 2 patients (16.66%, case no- 8), skin necrosis in 1 patient (8.33%, case no- 8) and skin infection in 1 patient (8.33%, case no- 10). Patients developing skin necrosis and infection were treated with dressing through a window in the plaster and third generation cephalosporin. In Group- I late complications developed in 2 patients (15.38%), among them stiffness developed in 1 patient (7.69%, Case no- 3) and deformity developed in 1 patient (7.69%, Case no- 5). In Group- II late complications developed in 3 patients (24.99%), among them stiffness developed in 1 patient (8.33%, Case no- 4) and deformity developed in 2 patients (16.66%, Case no- 6).

## CONCLUSION

Operative treatment of congenital clubfoot deformity is always an accepted method of treatment. The final outcome of the results shows that in McKay's procedure satisfactory results found in 89.47% which is more than Turco's procedure 52.94%. From this result it may be concluded that McKay's procedure is better method of operation than Turco's procedure.

## REFERENCES

1. Dillwyn-Evans, C. W. (1961). Relapsed club foot. *J Bone Joint Surg*, 43-B(4), 722-733.
2. Brokman, W. R. (1930). Family study and cause of congenital clubfoot. *J Bone Joint Surg*, 46-B, 936-41.
3. Lehman, W. B. (1980). The club foot 1st ed. Philadelphia and Toronto. *J.B. Lippincott company*.
4. Weinstein, S. L. (1994). The paediatric foot. In: Weinstein, SL, Buckwalter, JA, editors. *Turek's orthopaedics: principles and their applications*. 5th ed. Philadelphia: J.B. Lippincott Company, pp. 641-44.
5. Beaty, J. H. (2003). Congenital, clubfoot. In: Canale ST, editor. *Cambell's operative orthopaedics*. 10th ed. St. Louis London: Mosby. pp. 988-1006.
6. Wynne-Davis, R. (1964). Family studies and the cause of congenital clubfoot. *J Bone Joint Surg*, 46-B, 453-63.
7. Barenfeld, P. A., & Weseley, M. S. (1972). Surgical treatment of congenital clubfoot. *Clinical Orthopaedics and Related Research (1976-2007)*, 84, 79-87.
8. Kite, J. H. (1939). Principles involved in the treatment of congenital club foot. *J Bone Joint Surg Am*, 21(3), 595-606.
9. Rocher, H. L. (1966). Recurrent of congenital club foot. *J Bone Joint Surg*, 48-A, 331-337.
10. Ponseti, I. V., & Smoley, E. M. (1933). Congenital club foot, The results of treatment. *J Bone Joint Surg*, 45-A(1), 261-269.
11. Ponseti, I. V. (1992). Treatment of congenital club foot. *J Bone Joint Surg Am*, 74- A(3), 448-454.
12. McKay, D. W. (1983). New concept of and approach to club foot treatment: Section II correction of the club foot. *J PediatrOrthop*, 3(1), 10-21.
13. Bensahel, H., Csukonyi, Z., Desgrippes, Y., & Chaumien, J. P. (1987). Surgery in residual clubfoot: one-stage medioposterior release "a la carte". *Journal of Pediatric Orthopaedics*, 7(2), 145-148.
14. Commings, R. J., & Lovell, W. W. (1988). Operation treatment of congenital idiopathic club foot. *J Bone Joint Surg Am*, 70(7), 1108-1112.
15. Turco, V. J. (1975). Resistant congenital clubfoot. *AAOS Instructional Course Lectures*, 24, 104-20.
16. Magone, J. B., Torch, M. A., Clark, R. N., & Kean, J. R. (1989). Comparative review of surgical treatment of the idiopathic club foot by three different procedure at Columbus children's Hospital. *J. Pediatr. Orthop*, 9(1), 49-58.
17. McKay, D. W. (1982). New concept of and approach to club foot treatment section-I principle and morbid anatomy. *J PediatrOrthop*, 2(4), 347-356.
18. George, W. S., & Miwaukee, W. (1985). Complete sbutalar release in clubfoot, part- II- comparison with less extensive procedure. *J Bone Joint Surg*, 67-A(7), 1056-1065.
19. Sullivan, J. A. (1996). 'The child's foot'. In: Lovell and Winters PaediatricOrthopaedics. 4th edition, Philadelphia, Lippincott, Raven publishers, pp. 1103-13.
20. Rumyantsev, N. J., & Ezrohi, V. E. (1997). Complete subtalar release in resistant clubfeet: a critical analysis of results in 146 cases. *Journal of Pediatric Orthopaedics*, 17(4), 490-495.
21. Alam, A. S. M. M., Ahmed, S. A., Islam, M. M., & Kairy, R. R. (2004). Evaluation of the result of surgical correction of congenital talipesquinovarus (CTEV) by modified Attenborough procedure. *Journal of Bangladesh Orthopaedic Society*, 19, 37-41.
22. McKay, D. W. (1983). New concept of and approach to club foot treatment: Section III evaluation and results. *J PediatrOrthop*, 3(2), 141-147.

**Citation:** Mohammad Sazzad Hossain & Sharif Md. Musa (2024). Comparative Study of the Surgical Treatment of Congenital Club Foot between McKay and Turco Procedure. *EAS J Orthop Physiother*, 6(4): 64-69.