

Original Research Article

A Comparison of Plate Fixation and Intramedullary Nailing in Shaft of Humerus Fractures in Adult

Md. Zakir Hossain^{1*}, Syed Muhammad Abdullah², Dr. Sanjeeda Saad³¹Md. Zakir Hossain, Associate Professor, Department of Orthopaedics, Jahurul Islam Medical College Hospital, Bangladesh²Syed Muhammad Abdullah, Assistant Professor, Combined Military Hospital, Dhaka, Bangladesh³Dr. Sanjeeda Saad, Associate Professor, Department of Surgery, Jahurul Islam Medical College Hospital, Bangladesh

Article History

Received: 04.12.2024

Accepted: 10.01.2025

Published: 22.02.2025

Journal homepage:

<https://www.easpublisher.com>

Quick Response Code



Abstract: Background: Humeral shaft fractures (HSFs) represent 3% of the fractures of the locomotor apparatus, and the middle third of the shaft is the section most affected. In the majority of cases, it is treated using nonsurgical methods, but surgical indications in HSF cases are increasingly being adopted. They are most common in males between 21 and 30 years old and females between 60 and 80 years old. **Objective:** To compare the intramedullary nailing and plate fixation in adult humeral shaft fractures. **Materials and Methods:** This was a prospective comparative study carried out in the Department of Orthopedics, Jahurul Islam Medical College & Hospital, Bhagolpur, Bajitpur, Kishoregonj for 2 years based on the patient presentation at both emergency room and outpatient clinic department between June 2021 and March 2023 in which fifty adult patients with humeral shaft non-union were recruited. Coagulopathies, on drugs like steroids, anti-neoplastic that may interfere with healing and those with significant co-morbidities such as Diabetes Mellitus, Neoplasia were all excluded from the study. **Results:** The nailing group operated for 84.11 ± 8.98 minutes, while the plating group took 115.66 ± 9.56 minutes. The result was statistically significant ($P < 0.05$). The nailing group lost 75.02 ± 9.57 mL of blood during surgery, significantly less than the plating group's 132.79 ± 8.64 mL ($P < 0.05$). Of the 25 patients in the plating group, nine (36%) had outstanding results and eight (32%) had good results. In the nailing group, 11 (44%) achieved great outcomes, and 9 (36%) had good results. The two groups did not differ statistically from one another. **Conclusion:** The nailing group required less operating time and had less blood loss than the plating group. There were no significant differences in functional outcomes between the intramedullary nailing and plating groups.

Keywords: Plate fixation, intramedullary nailing, shaft fractures of humerus.

Copyright © 2025 The Author(s): This is an open-access article distributed under the terms of the Creative Commons Attribution 4.0 International License (CC BY-NC 4.0) which permits unrestricted use, distribution, and reproduction in any medium for non-commercial use provided the original author and source are credited.

INTRODUCTION

Humeral shaft fracture is a common injury which can be treated either conservatively with functional bracing or with surgical fixation. Current evidence shows an increase in the rate of nonunion after conservative treatment, suggesting that indications for conservative treatment may need to be re-examined [1]. Updates trends in treatment for humeral shaft fracture. Indications for surgery, both for plate osteosynthesis with open reduction and internal fixation (ORIF) as well as for minimally invasive plate osteosynthesis (MIPO) and intramedullary nail (IMN) are described [1].

Humeral shaft fractures significantly contribute to musculoskeletal injuries and are more common in men than in women; they constitute 3–5% of all adult fractures and impact 20% of humeral fractures in the adult population [2]. The incidence of humeral shaft fractures has a dual-peaked age distribution, [3,4] and with the increasing elderly population, there is concern that the incidence of these fractures could increase [5].

Patients with HSF present with pain, disability, a swollen upper extremity and visible deformity. The deformity is usually a varus angulation for most fractures located distal to the deltoid tuberosity but a valgus deformity is also possible for fracture lines between the pectoralis major insertion and the deltoid tuberosity. The

*Corresponding Author: Md. Zakir Hossain

Md. Zakir Hossain, Associate Professor, Department of Orthopaedics, Jahurul Islam Medical College Hospital, Bangladesh

skin must be carefully inspected to rule out an open wound [6]. Several options are possible for the management of HSF: conservative management, open reduction and internal fixation (ORIF) with a plate, or closed reduction and nailing. An external fixator is also an option, however rarely indicated. Undisplaced or minimally displaced HSF are routinely treated conservatively [7].

Operative intervention lowers the possibility of nonunion and could produce improved functional outcomes. To treat these fractures, surgical intervention is being used more frequently nowadays. The best surgical method, however, is still up for discussion. The two surgical techniques that are most frequently employed are open reduction with plate fixation and intramedullary nailing [8,9]. Utilizing a dynamic compression plate necessitates a lengthy procedure that involves extensive dissection of soft tissues from the bone and problems because the radial nerve is close by in the field of dissection [10]. It is theoretically possible to stabilize the fracture using the intramedullary nailing with less invasive surgery, with a biomechanical advantage as it functions by sharing the load, reduced stress shielding, a decreased chance of refracture after implant removal, and auto graft availability during reaming [11].

MATERIALS AND METHODS

This was a prospective comparative study carried out in the Department of Orthopedics, Jahurul Islam Medical College & Hospital, Bhagolpur, Bajitpur, Kishoregonj for 2 years based on the patient presentation at both emergency room and outpatient clinic department between June 2021 and March 2023 in which fifty adult patients with humeral shaft non-union were recruited. The inclusion criteria are adult patients with isolated closed humeral shaft fracture nonunion while patients with pathological fractures, open fractures, chronic osteomyelitis of humerus, fracture with bone loss which required bone lengthening or major bone grafting, coagulopathies, on drugs like steroids, anti-neoplastic that may interfere with healing and those with significant co-morbidities such as Diabetes Mellitus, Neoplasia were all excluded from the study. Ethical clearance was obtained from the research ethics committee of the hospital and informed consent obtained from all patients involved in the study.

A purposive non-randomized sampling method was used with help of study assistant who allotted the patients numbers (1 to 50) that were grouped Group I (Plating 25 samples) and Group II (intramedullary nailing 25 samples) groups. Patient was evaluated through the tripods of detailed clinical history, clinical examination and appropriate investigations including radiological imaging. Assessment was done at or before the determination of the definitive management. Pre-operative radiographs were done for all patients to confirm diagnosis and classification of the humeral shaft

non-union fracture. Operation was carried out in aseptic conditions under general anaesthesia during 1 to 5 days of admission. This study was to compare the results of the intramedullary interlocking nail and plating for the treatment of humeral shaft fractures in terms of time to achieve union, functional outcome (DASH score) and complications of surgery in adults. The DASH is scored in two components: the disability/symptom questions (30 items, scored 1-5) and the optional high performance sport/music or work section (4 items, scored 1-5). DASH Disability/Symptom Score = [(sum of n responses / (n)-1] x 25, where n is the number of completed responses.) For DCP, the fractures in the upper and middle 1/3 s were reached via the anterolateral approach while those in the distal 1/3 were reached via the posterior approach. All LIMNs were done in ante-grade fashion. All patients had standard intra- and post-operative care including wound care and physiotherapy. Appropriately sized LDCP (with minimum of 6 cortices on either side of the fracture), were used for the plating, and an appropriately sized LIMN for the nailing. Orthogonal view radiographs were done immediate post operatively and at every six weekly intervals until radiologic union were achieved or up to 6 months follow up period. All patients were followed up for a period of 6 months at which time radiologic union is expected to have occurred. Any patients without radiologic union at 6 months were regarded as having recurrent non-union. All the participants were followed up six weekly intervals where progress in clinical union, radiologic union and general well-being of the patients were noted and recorded. Clinical and radiological outcome assessments were done. The patients with complications were evaluated and treated accordingly. All post-operative findings including imaging feature of fracture healing were collected and recorded by other study assistants and the data collected were analyzed using SPSS Version 25 and the statistical inferences were made. The patients who belong to group I or Group II were made known during the analysis. The results were reported in words, tables, Chi Square was used while considering P value < 0.05 as statistical significant.

RESULTS

Table 1 shows in plating group 18-40 yrs were 14(56%) 41-60yrs were 7 (28%), >60 yrs 4(16%). In response of nailing group 18-40yrs were 13(52%), 41-60yrs were 10 (40%) and >60yrs 2(8%). Plating group 13 (52%) were male and 12 (48%) were female. In nailing group 15 (60.0%) were male and 10 (40.0%) were in female. Most of the patients in our study were males in both the plating and the nailing groups. Table 2 shows in response to the injury causes, the plating group had 14 (56%) RTAs, 7 (28%) assaults, and 4 (16) domestic falls; the nailing group had 10 (40%) RTAs, 8 (32%) assaults, and 7 (28%) domestic falls. Table shows that nailing group's operating time was 84.11±8.98 minutes, and plating group's 115.66 ± 9.56 minutes. That was statistically significant (p <0.05). Compared to the plating group, which experienced an intraoperative blood

loss of 132.79 ± 8.64 mL were in plating group, the nailing group's blood loss was 75.02 ± 9.57 ml that was statistically significant ($P < 0.05$). The Mean duration of union is 14.26 ± 3.17 weeks and 16.13 ± 3.81 weeks for nailing and plating respectively (Table-3). Out of the 25

patients in the plating group, nine (36%) had excellent results, while eight (32%) had good results. In the case of the nailing group, 11 (44%) had excellent results, while 9 (36%) had good results. The two groups did not differ statistically from one another (Table-4).

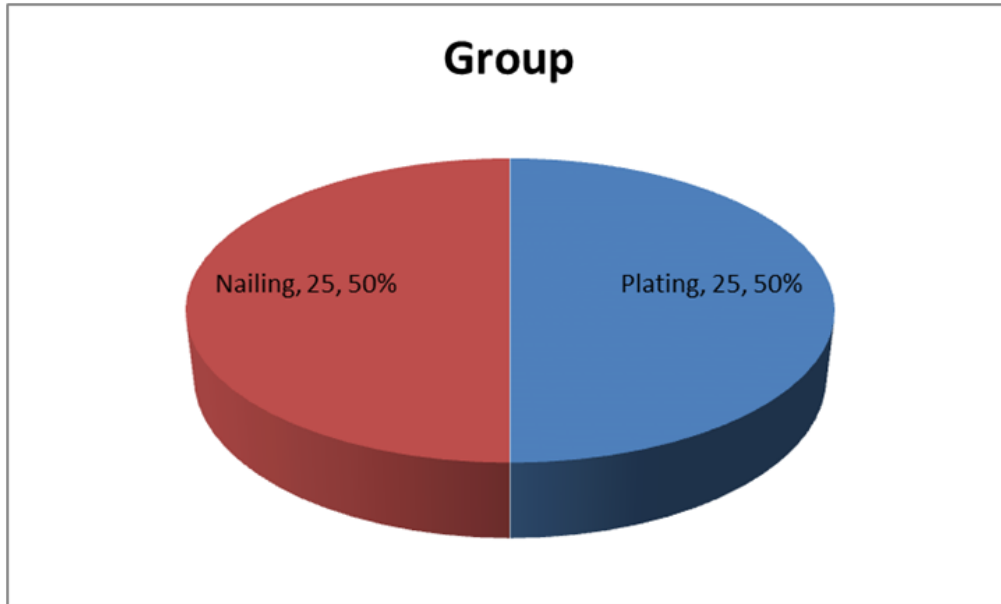


Figure I: Surgical protocol of the study subject (n=50)

Table 1: Demographic characteristic distribution of the study population (n=50)

	Study group		Total	P value
	Group I n=25(%)	Group II n=25(%)		
Age in year				
18-40 yrs	14 (56)	13 (52)	27	0.77
41-60 yrs	7 (28)	10 (40)	17	
> 60 yrs	4 (16)	2 (8)	6	
Sex				
Male	13 (52)	15 (60)	28	0.94
Female	12 (48)	10 (40)	22	
Total	25 (100)	25 (100)	50	

Table 2: Causes of injury characteristic distribution of the study population (n=50)

Causes of injury	Group		Total
	Group I n=25(%)	Group II n=25(%)	
RTA	14 (56)	10 (40)	24
Assault	7 (28)	8 (32)	15
Domestic Fall	4 (16)	7 (28)	11

Table 3: Duration of operating time, union time and mean blood loss (n=50)

	Study group		p value
	Group I n=25(%)	Group II n=25(%)	
Duration of operating time (min)	115.66 ± 9.56	84.11 ± 8.98	<0.001
Mean blood loss(ml)	132.79 ± 8.64	75.02 ± 9.57	<0.001
Mean duration of union for plated fractures	14.26 ± 3.17	16.13 ± 3.81	0.11

Table 4: Indications for surgery between both groups (n=50)

Functional outcome	Study group		Total
	Group I n=25(%)	Group II n=25(%)	
Excellent	9 (36)	11 (44)	20
Good	8 (32)	9 (36)	17
Fair	6 (24)	5 (20)	11
Poor	2 (08)	0	2
Total	25 (100)	25 (100)	50

DISCUSSION

In this study majority age group were 14(56%) and 13(52%) between 18-40 yrs in plating and nailing groups respectively. Most of the patients in our study were males in both the plating and the nailing groups. In the Changulani *et al.*, study in the dynamic compression plating group, there were 19 men (79.2%) and five females (20.8%), compared to 20 males (86.9%) and three females (13%) in the nailing group [10]. Most of the patients in Angachekar *et al.*, [13] study were males in both the plating and the nailing groups.

In this study observed that response to the injury causes, the plating group had 14 (56%) RTAs, 7 (28%) assaults, and 4 (16%) domestic falls; the nailing group had 10 (40%) RTAs, 8 (32%) assaults, and 7 (28%) domestic falls. Mahesh and Zelshon study revealed that road traffic accident was the most common mode of injury (53.33%) and assaults cause of injury [12]. Angachekar *et al.*, reported in both groups, automobile accidents were the most frequent cause of injuries and assaults cause of injury [13].

In this study observed that nailing group's operating time was 84.11±8.98 minutes, and plating group's 115.66 ± 9.56 minutes. That was statistically significant (P <0.05). Compared to the plating group, which experienced an intraoperative blood loss of 132.79 ± 8.64 mL were in plating group, the nailing group's blood loss was 75.02 ± 9.57 ml that was statistically significant (P <0.05). The mean duration of union is 14.26± 3.17 weeks and 16.13± 3.81 weeks for nailing and plating respectively. Angachekar *et al.*, [13] revealed that the nailing group's operating time was 82.1±7.61 minutes, which was much smaller (P value <0.05) than the plating group's 119.59 ± 10.16 minutes. Compared to the plating group, which experienced an intraoperative blood loss of 130.59 ± 11.44 mL, the nailing group's blood loss was considerably smaller (p value <0.05) at 71±7.38 mL. All nailing procedures were closed under fluoroscopic guidance without opening the fracture site. Similar observation as found Mahesh and Zelshon study observed that the average time taken for union is 13.8 weeks and 15.1 weeks for nailing and plating respectively [12].

Present study observed, Nine (36%) and eight (32%) of the 25 patients in the plating group had excellent and good results, respectively. Of the nailing

group, 9 (36%) had good outcomes and 11 (44%) had exceptional results. There was no statistically significant difference between the two groups. Similar observation was found Mahesh and Zelshon study also reported the 12 patients in nailing group 5(41.66%) patients had excellent results, 6(50%) patients had good functional outcome and 1(8.33%) patient had fair result [12]. Among the 18 patients in plating group 7 (38.88%) patients had excellent functional outcome, 6 (33.33%) patients had good functional outcome, 4 (22.22%) patients had good functional outcome and 1 (5.55%) patient had poor results. The results are not statistically significant (P> 0.05) [12]. Angachekar *et al.*, reported out of the 17 patients in the plating group, five (29.41%) had excellent results, while eight (47.06%) had good results. In the case of the nailing group, four (40%) had excellent results, while three (30%) had good results [13].

CONCLUSION

In conclusion, neither plating nor nailing is superior in all conditions for a specific fracture, and each case must be evaluated individually. Operating time and blood loss were significantly higher in the plating group compared to the nailing group, although the average duration of union was not statistically different between the two groups. This study concluded that both nailing and plating are effective in terms of fracture union, time to achieve union, and functional outcome; however, complications were found to be higher in the plating group, with the main concerns being radial nerve injury and infection rate. Though dynamic compression plating patients have better shoulder function than patients receiving antegrade humeral interlocking, this is due in part to uncooperative patients, discomfort, and rotator cuff impingement by nail and fibrosis. However, this restriction can be rectified by removing the nail following consolidation, followed by movement and physiotherapy.

REFERENCE

1. Orapiriyakul, W., Apivatthakakul, V., Theppariyapol, B., & Apivatthakakul, T. (2023). Humerus shaft fractures, approaches and management. *Journal of Clinical Orthopaedics and Trauma*, 102230.
2. Nshimiyimana, A., Ingabire, J. D. L. C. A., Byiringiro, J. C., Habumugisha, B., & Mwizerwa, J. L. (2024). The outcome of nonoperative treatment

- for adult humeral shaft fractures using a U-shaped slab in resource-limited settings: a prospective cohort study. *Journal of Orthopaedic Surgery and Research*, 19(1), 316. doi: 10.17511/ijmrr.2015.i10.218. [DOI] [Google Scholar]
3. Tsai, C. H., Fong, Y. C., Chen, Y. H., Hsu, C. J., Chang, C. H., & Hsu, H. C. (2009). The epidemiology of traumatic humeral shaft fractures in Taiwan. *International orthopaedics*, 33, 463-467. doi: 10.1007/s00264-008-0537-8. [DOI] [PMC free article] [PubMed] [Google Scholar]
 4. Tytherleigh-Strong, G., Walls, N., & McQueen, M. M. (1998). The epidemiology of humeral shaft fractures. *The Journal of Bone & Joint Surgery British Volume*, 80(2), 249-253. doi: 10.1302/0301-620X.80B2.0800249. [DOI] [PubMed] [Google Scholar]
 5. Schoch, B. S., Padegimas, E. M., Maltenfort, M., Krieg, J., & Namdari, S. (2017). Humeral shaft fractures: national trends in management. *Journal of Orthopaedics and Traumatology*, 18, 259-263. doi: 10.1007/s10195-017-0459-6. [DOI] [PMC free article] [PubMed] [Google Scholar]
 6. Gallusser, N., Barimani, B., & Vauclair, F. (2021). Humeral shaft fractures. *EFORT Open Reviews*, 6(1), 24-34.
 7. Shields, E., Sundem, L., Childs, S., Maceroli, M., Humphrey, C., Ketz, J. P., ... & Gorczyca, J. T. (2016). The impact of residual angulation on patient reported functional outcome scores after non-operative treatment for humeral shaft fractures. *Injury*, 47(4), 914-918.
 8. Kurup, H., Hossain, M., & Andrew, J. G. (2011). Dynamic compression plating versus locked intramedullary nailing for humeral shaft fractures in adults. *Cochrane Database of Systematic Reviews*, (6).
 9. Liu, G. D., Zhang, Q. G., Ou, S., Zhou, L. S., Fei, J., Chen, H. W., ... & Gu, J. W. (2013). Meta-analysis of the outcomes of intramedullary nailing and plate fixation of humeral shaft fractures. *International Journal of Surgery*, 11(9), 864-868.
 10. Changulani, M., Jain, U. K., & Keswani, T. (2007). Comparison of the use of the humerus intramedullary nail and dynamic compression plate for the management of diaphyseal fractures of the humerus. A randomised controlled study. *International orthopaedics*, 31, 391-395.
 11. Habernek, H., & Orthner, E. (1991). A locking nail for fractures of the humerus. *The Journal of Bone & Joint Surgery British Volume*, 73(4), 651-653.
 12. Mahesh, D. V., & Zelshon, A. (2020). Comparative study of intramedullary nailing versus plating for shaft fractures of humerus in adults. *International Journal of Orthopaedics*, 6(3), 921-5.
 13. Angachekar, D., Patel, S., Shetty, S., Atal, S., Dhond, A., Sharma, R., ... & Angachekar, D. (2024). A Retrospective Analysis of Dynamic Compression Plating Versus Intramedullary Nailing for the Management of Shaft of Humerus Fractures in an Urban Trauma Care Center. *Cureus*, 16(1).

Citation: Md. Zakir Hossain, Syed Muhammad Abdullah, Sanjeeda Saad (2025). A Comparison of Plate Fixation and Intramedullary Nailing in Shaft of Humerus Fractures in Adult. *EAS J Orthop Physiother*, 7(1): 5-9.
