

Case Report

“Kissing Ovaries” Sign on Ultrasonography in a Case of Endometriosis

Dr. Eldho Sajeev^{1*}, Dr. Riya Deshmukh¹, Dr. Manpreet Singh¹, Dr. M. Prabakaran²

¹Post graduate Resident, Department of Radiodiagnosis, Sree Balaji Medical College and Hospital, Chromepet, Chennai – 600044, India

²Professor and Head, Department of Radio-diagnosis, Sree Balaji Medical College and Hospital, 7 Works Road, Chromepet, Chennai, Tamilnadu, 600044, India

Article History

Received: 20.09.2020

Accepted: 11.10.2020

Published: 21.10.2020

Journal homepage:

<https://www.easpublisher.com/easjrit>

Quick Response Code



Abstract: Endometriosis is a chronic gynaecological condition that can cause pelvic pain and infertility, affecting women of reproductive age. It has three distinct manifestations: ovarian endometriomas, peritoneal implants and deep pelvic endometriosis. Here we present a case of bilateral ovarian endometrioma with a classic sign called kissing ovaries.

Keywords: Endometriosis, Ovary, Endometrioma.

Copyright © 2020 The Author(s): This is an open-access article distributed under the terms of the Creative Commons Attribution **4.0 International License (CC BY-NC 4.0)** which permits unrestricted use, distribution, and reproduction in any medium for non-commercial use provided the original author and source are credited.

INTRODUCTION

Endometriosis is defined as the presence of endometrial tissue outside the endometrium and the myometrium. The reference standard for the diagnosis of pelvic endometriosis is laparoscopic biopsy of lesions with a suspicious appearance, followed by histologic confirmation. Imaging, however, may play an important role in the detection of this disease [1]. Endometriosis has a high incidence in women in the reproductive years and can cause chronic pelvic pain, interfering with quality of life and determining infertility. Endometriomas, also known as chocolate cysts or endometriotic cysts, are a localized form of endometriosis and are usually within the ovary. They are readily diagnosed on ultrasound, with most demonstrating classical radiographic features [2]. Endometriomas contains dark degenerated blood products following repeated cyclical hemorrhage. The cysts may be up to 20 cm in size although they are

usually smaller (2-5 cm). Using B-mode, an ovarian endometrioma was suspected in the presence of round-shaped cysts with thick walls, regular margins, and homogeneous low echogenicity. The diagnosis of “kissing ovaries” was made when both ovaries were joined together behind the uterus in the cul-de-sac [3].

CASE DESCRIPTION

A 28 year old woman with complaints of chronic lower abdominal pain aggravated during menstruation presented for evaluation of infertility. No other significant past history. On ultrasound both ovaries were located in the midline posterior to the fundus of uterus in close proximity to each other. Both ovaries showed cystic lesions with low level internal echoes measuring ~ 3.5 x 2.5 cm in the right ovary and 2.1 x 1.8 cm in the left ovary – suggestive of ovarian endometrioma (Fig-1).

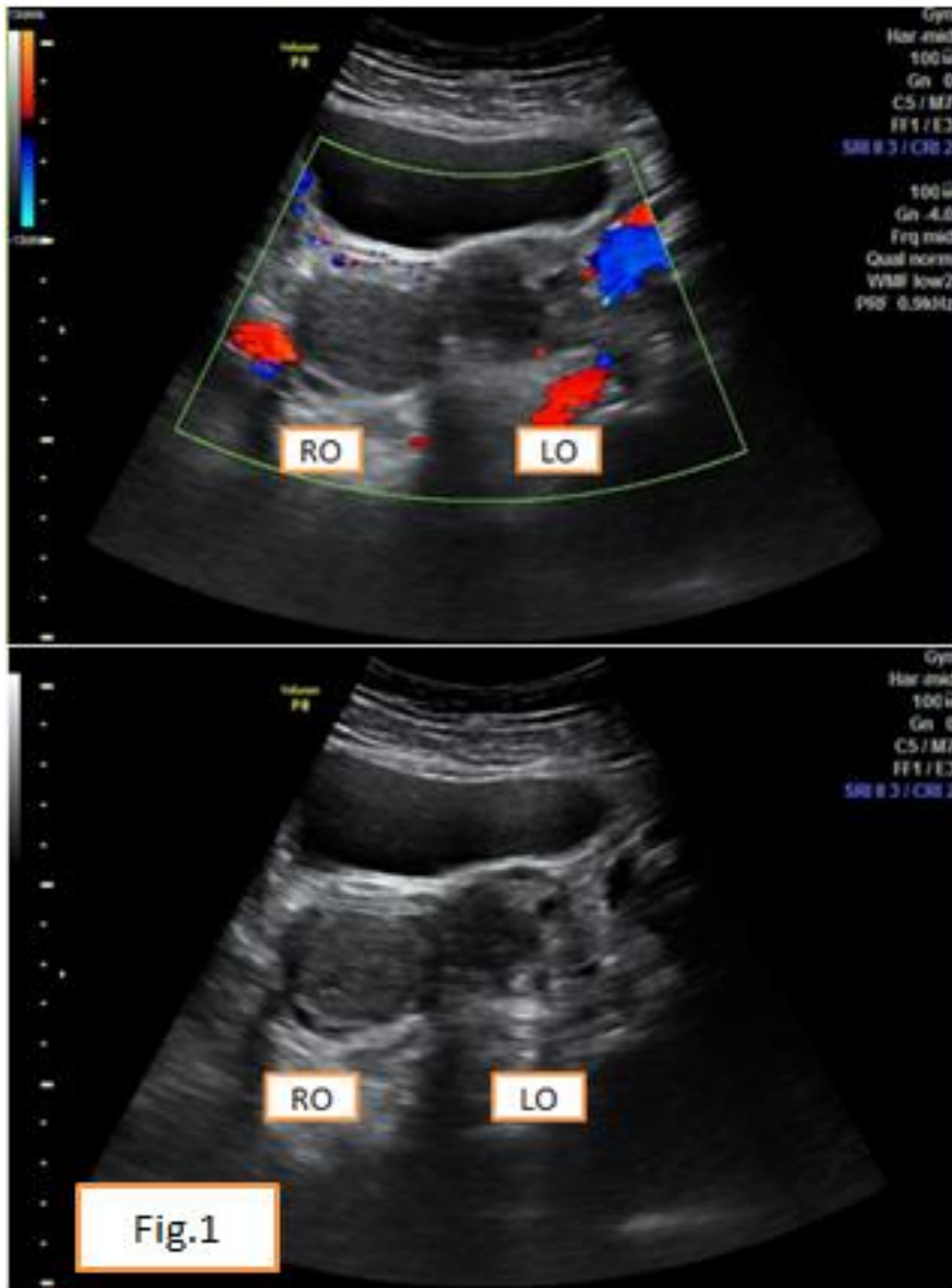


Fig-1: Both ovaries showed cystic lesions with low level internal echoes measuring ~ 3.5 x 2.5 cm in the right ovary and 2.1 x 1.8 cm in the left ovary – suggestive of ovarian endometrioma.

DISCUSSION

Endometriosis is a common disorder, yet it is among the most enigmatic of gynecologic diseases. The literature on endometriosis is extensive, though often contradictory or inadequate, and reflects our frequent inability to decipher even the most fundamental aspects of common diseases. Recent studies have produced new insights into this complex disorder. The kissing ovaries sign refers to the appearance seen when both ovaries are placed in near proximity or are touching each other in the pouch of Douglas, usually due to pelvic adhesions, which can be seen on ultrasound, CT or MRI [4].

This sign is most commonly associated with the extreme form of pelvic endometriosis, in which frequent bleeding produces adhesions to the midline with the pulling of the ovaries, but may also be seen in pelvic inflammatory disease with pyosalpinx / pelvic abscess, although MRI may distinguish between the two conditions.

Conflict of Interest: Author declares that they have no conflict of interest.

Ethical approval (animals): This article does not contain any studies with animals performed by any of the author(s).

Authors' Contributions

1. **Dr. Eldho Sajeev (ES):** Substantial contributions to the conception or design of the work; or the acquisition, analysis, or interpretation of data for the work – MP, ES, RD, MS.
2. **Dr. Riya Deshmukh (RD):** Drafting the work or revising it critically for important intellectual content – ES, RD, MS, MP.
3. **Dr. Manpreet Singh (MS):** Final approval of the version to be published – ES, RD, MS, MP.
4. **Dr. M. Prabakaran (MP):** Agreement to be accountable for all aspects of the work in ensuring that questions related to the accuracy or integrity of any part of the work are appropriately investigated and resolved – ES, RD, MS, MP.

REFERENCES

1. Keyhan, S., Hughes, C., Price, T., & Muasher, S. (2015). An update on surgical versus expectant management of ovarian endometriomas in infertile women. *BioMed research international*, 2015:1-9.
2. Alborzi, S., Keramati, P., Younesi, M., Samsami, A., & Dadras, N. (2014). The impact of laparoscopic cystectomy on ovarian reserve in patients with unilateral and bilateral endometriomas. *Fertility and sterility*, 101(2), 427-434.
3. Jayaprakasan, K., Becker, C., & Mittal, M. (2018). The effect of surgery for endometriomas on fertility: scientific impact paper no. 55. *BJOG-AN International Journal Of Obstetrics And Gynaecology*, 125(6), E19-E28.
4. Somigliana, E., Vigano, P., Filippi, F., Papaleo, E., Benaglia, L., Candiani, M., & Vercellini, P. (2015). Fertility preservation in women with endometriosis: for all, for some, for none?. *Human Reproduction*, 30(6), 1280-1286.