

## Original Research Article

## Histologic, Progestational and Antiestrogenic Effects of Methanolic Extract of *Asparagus pubescens* (Roots) on the Male Reproductive Organs of Rabbit

Ilegbedion, Ikhide Godwin<sup>1\*</sup>, Babepere, Prosper Ikechukwu<sup>2</sup>, Mirinn, Kenneth Ebiakpo<sup>3</sup>, Chukwuedo, Judith Nkechi<sup>4</sup>

<sup>1,2,4</sup>Department of Medical Laboratory Science, Faculty of Basic Medical Science, College of Health Science, Niger Delta University, Wilberforce Island, Bayelsa State, Nigeria.

<sup>3</sup>Medical Laboratory Services, Federal Medical Center, Yenagoa, Bayelsa State, Nigeria.

**Article History**

**Received:** 02.06.2024

**Accepted:** 09.06.2024

**Published:** 23.07.2024

**Journal homepage:**

<https://www.easpublisher.com>

**Quick Response Code**

**Abstract:** This study investigates the effect of methanolic root extract of *Asparagus pubescens* on the male reproductive system in rabbits. Male reproductive organs is essential for producing and maintaining sperm, secreting testosterone, and transporting sperm to the female reproductive tract, include the testicles and accessory organs such as the epididymis, vas deferens, and prostate gland. The testicles, being the primary site of sperm and testosterone production, play a critical role in male fertility. Experimental animals were divided into four treatment groups and corresponding control groups. The plant extract was administered at low (250 mg/kg) and normal (500 mg/kg) doses for 14 and 21 days, respectively. Control groups, which received no treatment, showed no abnormal physical observations. Fertility assays included female rabbits, all of which became pregnant, confirming the fertility of the male rabbits used. Post-mortem analysis of testes from treated groups revealed no gross pathological changes. Histological examination indicated no disruptions in spermatogenesis across all treated groups, comparable to controls. The absence of pathological changes suggests that *Asparagus pubescens* does not exhibit visible contraceptive effects on male reproductive organs based on histological techniques. Estrogen's role in regulating fluid reabsorption in the male reproductive tract suggests that the extract's antiestrogenic activity might produce a contraceptive effect. Further research is necessary to explore its potential as a male contraceptive.

**Keywords:** Rabbits, *Asparagus pubescens*, reproductive tract.

**Copyright © 2024 The Author(s):** This is an open-access article distributed under the terms of the Creative Commons Attribution **4.0 International License (CC BY-NC 4.0)** which permits unrestricted use, distribution, and reproduction in any medium for non-commercial use provided the original author and source are credited.

## INTRODUCTION

Organs of the male reproductive system can be defined as specialized organs to produce and maintain the male sex cell (sperm), secrete male sex hormone (testosterone), and to transport sperm cells with other supporting fluids to the female reproductive tract. The male reproductive organ can therefore be separated into two wide groups; the essential sex organ which includes the two testicles and the auxiliary (accessory) sex organ which can too be classified into two groups; the internal auxiliary sex organs include the epididymis, vas deferens, seminal vesicle, prostate organ, bulbourethral gland (Babakhanzade *et al.*, 2020). The testicles can subsequently be respected as the most important male reproductive organ because it is within the "testicles that sex hormones and sperm cells are produced (Heinrich & DeFalco 2020). The testicles are combined oval organs

measuring around 5cm (2 inches) in length and 2 1/2cm (1 inch) in diameter. Each testis weighs 10 - 15 grams. The testicles are mostly secured by a serous film called the tunica vaginalis which is derived from the peritoneum and shapes during the descent of the testicles. Each of the 200 — 300 lobules contain one to three firmly coiled tubules called the seminiferous tubule; it is within the seminiferous tubule that spermatogenesis takes place (Kang *et al.*, 2022). At puberty, in reaction to gonadotrophic hormones discharged by the front pituitary organ, spermatogenesis is initiated and occurs continuously after that (Roggenbuck *et al.*, 2024). Follicle-stimulating hormone (FSH) and testosterone from the interstitial cells of Leydig set in motion the process of sperm production (Lynda *et al.*, 2024). Moreover, lutenising hormone from the anterior lobe of the pituitary gland stimulates the interstitial cells of the testicles to extend the production of testosterone.

\*Corresponding Author: Ilegbedion Ikhide Godwin

Department of Medical Laboratory Science, Faculty of Basic Medical Science, College of Health Science, Niger Delta University, Wilberforce Island, Bayelsa State, Nigeria

Testosterone, the central hormone of the testes could be a C19 steroid, synthesized from cholesterol (Al-Suhaimi & Khan 2022). It has an OH group within the 17th position. It is also shaped by androstenedione secreted by the adrenal cortex. The emission of testosterone is beneath the control of the luteinizing hormone and the component by which the luteinizing hormone stimulates the Leydig cells includes the increased formation of cAMP through the serpentine luteinizing hormone receptor and the Gs cyclic AMP increases the formation of Cholesterol from cholesteryl esters and the change of cholesterol to pregnenolone utilizing the activation of protein kinase A. Contraceptives are substances used to prevent conception. Plants like *Ricinus communis* and *Asparagus pubescens* have been used for centuries to limit population development (Akbar 2020). Rabbits, being vertebrates and endothermic, maintain their body temperature over that of their surroundings within certain limits using inner physiological control components (Shrivels, & Cooper 2023). *Asparagus pubescens* which belong to the family Liliacea, is a perennial bush that develops in the rough region of Jos Plateau State. It has

little green, needle-like leaves and flowers, they are arranged in tufts on the branches and contain asparagine, which exerts a powerful effect on the urinary system and lowers breast milk volume in animals (Sobhy *et al.*, 2022). In this study, the effects of methanolic leaf extract of *ASPARAGUS PUBESCENS* were assessed on the male reproductive organs of rabbits.

## MATERIALS AND METHODS

### SUBJECTS

14 male rabbits (4.5-5.5kg) were obtained from the small animal unit of the National Veterinary Research Institute Vom. They were kept and observed for one week for any sign of illness and for stabilization during this period, they were fed with commercially prepared rabbit feed containing the necessary carbohydrate, protein and vitamins with clean water for a healthy up keep. The animals were grouped into five categories comprising of three rabbit in each group as shown in the experimental design below.

**Table 1: Schedule of treatment of the experimental animal**

Experimental Number of Group	Treatment Animals	Extract Treatment Dose Group	Number of Days
12	Control	Distilled water	21 days
23	Low dose	<i>Asparagus pubescens</i>	14 days
33	Low dose	<i>Asparagus pubescens</i>	21 days
43	Normal dose	<i>Asparagus pubescens</i>	14 days
53	Normal dose	<i>Asparagus pubescens</i>	21 days

### SOURCE OF PLANT AND PREPARATION OF EXTRACT

The roots of the plants were provided by Dr. Mrs Azija, a traditional *doctor attached with the Pharmacology Department, University of Jos*. The roots were then taken for extraction at the Biochemistry Department, National Veterinary Research Institute, Vom.

The dried roots were pulverized by grinding, using pestle and mortar and then extracted by the Soxhlet Extraction Method using methanol as the extraction solvent.

### ADMINISTRATION OF EXTRACT

The rabbits were administered with different doses of the extract as follows:

**Table 2: Administration of extract**

Dose	Mg/kg	Duration of administration
Low dose	250	14 days
Low dose	250	21 days
Normal dose	500	14 days
Normal dose	500	21 days

From a pharmacological research done by Okwuasaba & Nwafor *et al.*, 1998, they indicated that the normal dose per Kg of rabbit is 500mg.

### SAMPLE COLLECTION

After 14 days and 21 days of administering the extract, the rabbits were sacrificed and their testes removed and fixed in 10% formol saline.

### PROCESSING OF SAMPLE

The sample was processed using the manual processing schedule (Dibal *et al.*, 2022). The schedule is as follows;

10% formol saline	-	30 minutes
10% formol saline	-	30 minutes
Absolute alcohol I	-	2 Hours
Absolute alcohol II	-	Hours
Absolute alcohol III	-	3 Hours
Xylene I	-	30 minute
Xylene II	-	30 minute
Paraffin wax I	-	1 hour
Paraffin wax II	-	1 hour
Paraffin wax III	-	1 hour

### STAINING OF SAMPLE

Haematoxylin and Eosin staining method for general tissue structure was employed (Dibal *et al.*, 2022).

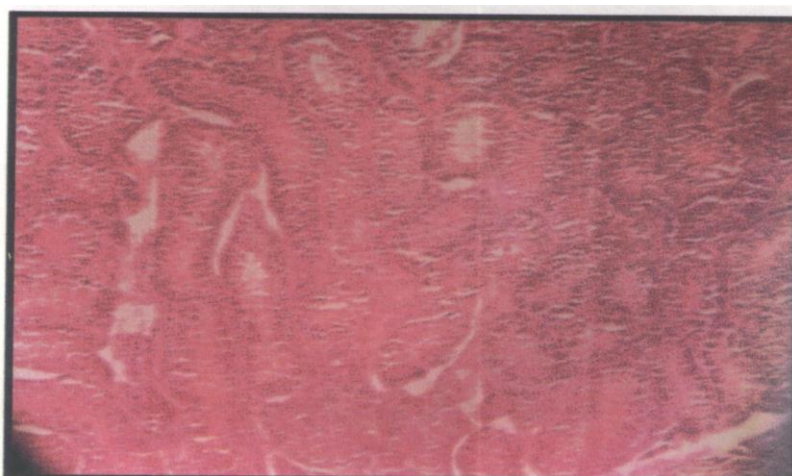
### PRINCIPLE OF THE STAIN

The Metallic salt or mordant is combined with haematoxylin which will confer a net positive charge to the dye. The cationic dye metal complex will bind to the anionic nuclear chromatin and stain it blue; the counter stain Eosin is an anionic dye and combines electrostatically with the cytoplasm and other tissues like collagen and muscle.

- i. Section was taken through xylene and alcohol
- ii. It was stained with Harris alum haematoxylin for 5min
- iii. Washed thoroughly in running tap water.
- iv. Differentiated in 1% acid-alcohol briefly
- v. Washed in tap water
- vi. Blued in scott tap water for 5 min
- vii. Washed in tap water
- viii. Counterstained in 1% aqueous eosin for 3 min
- ix. Washed in water
- x. Dehydrated in alcohol, cleared in xylene and mounted in DI
- xi. Labeled and examined microscopically, using the low-power microscope objective.

### PROCEDURE

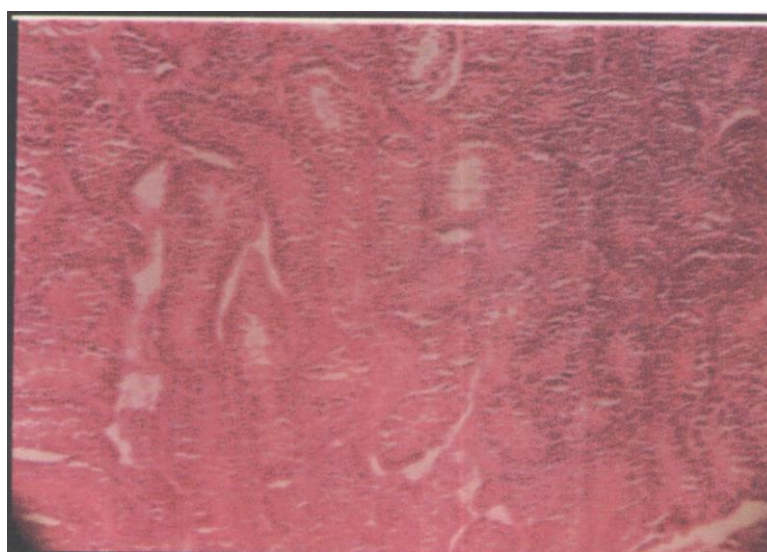
### RESULTS



**Plate One: Low Dose (250mg/kg) at 14 days Administration**

Plate 1 belongs to the low dose (250mg/kg) at 14 days of administration. The testes in this treatment group showed no pathological changes, the normal

testicular architecture was preserved and spermatogenesis occurred.

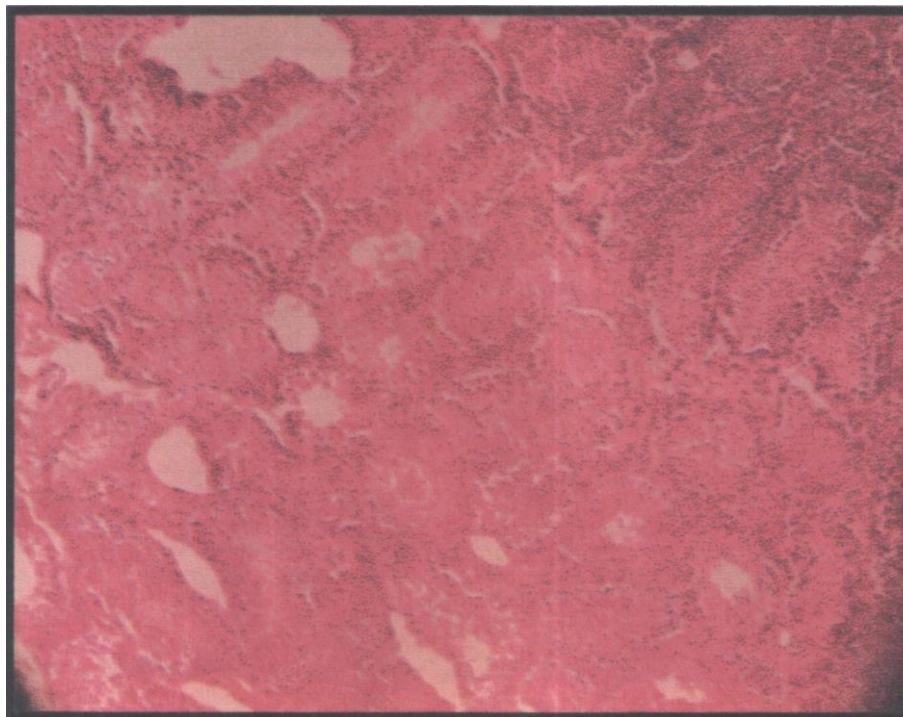


**Plate Two: Low Dose (250mg/kg) at 21 days Administration**



Plate 2 belongs to the low dose (250mg/kg) at 14 days of administration. The testicular cells in this group showed no pathological changes, the normal

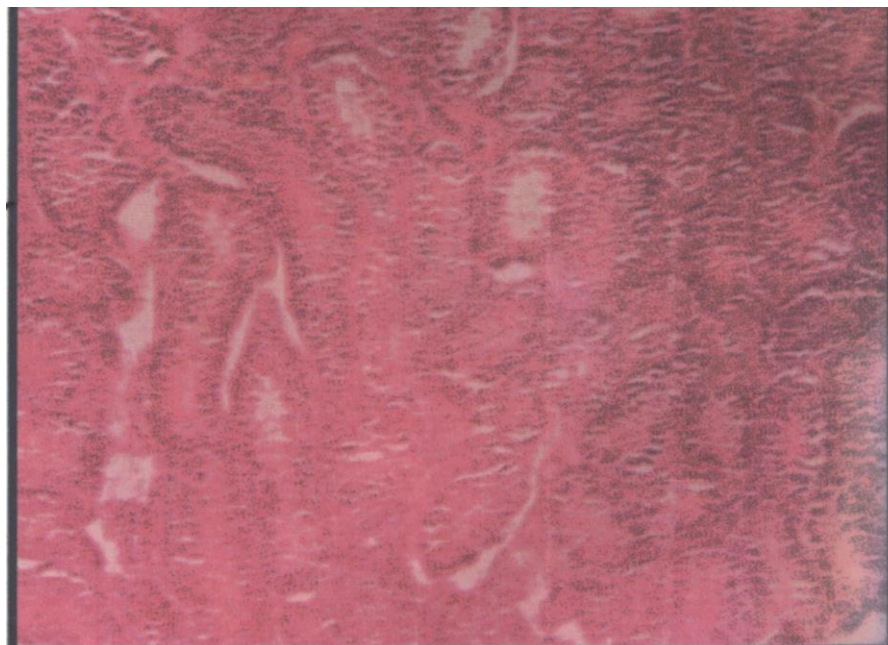
testicular architecture was preserved and spermatogenesis occurred.



**Plate Three: Normal Dose (500mg/kg) at 14 days Administration**

Plate 3 belongs to the normal dose (500mg/kg) at 21 days of administration. The testes in this group showed no pathological changes, the normal testicular

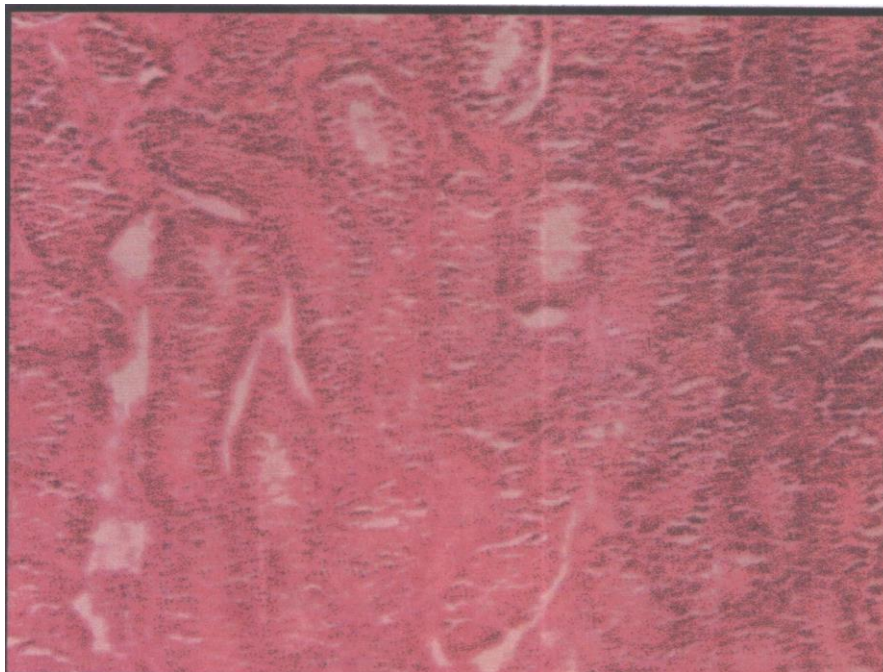
architecture was preserved and spermatogenesis occurred.



**Plate Four: Normal Dose (500mg/kg) at 21 days Administration**

Plate 4 belongs to the normal dose (500mg/kg) at 21 days of administration. The testes in this group showed no pathological changes, the normal testicular

architecture was preserved and spermatogenesis occurred.



**Plate Five: Control**

Plate 5 belongs to the normal dose (500mg/kg) at 21 days of administration. The testes in this group showed no pathological changes, the normal testicular architecture was preserved and spermatogenesis occurred.

## DISCUSSION

The experimental animals (rabbits) were divided into four treatment groups, each with a control group. The plant extract (root) was administered in low dose (250mg/kg) to the rabbits for 14 days and 21 days respectively and also in normal dose (500mg/kg) to the rabbits for 14 days and 21 days respectively. The control group to which no treatment was given showed no abnormal physical observation. The animals were also assayed for fertility and this was done by including female rabbits in the control. The female rabbits got pregnant indicating that the male rabbits used for the research were fertile. At post-mortem, the testes harvested from the animals in each of the treated groups showed no gross pathological changes.

The plates in Chapter Four are thin sections made from the testes of the animals in the different treated groups.

Plate 1 belongs to the low dose (250mg/kg) at 14 days of administration. The testes in this treatment group showed no pathological changes, the normal testicular architecture was preserved and spermatogenesis occurred as compared with the normal control plate (5).

Plate 2 belongs to the low dose (250mg/kg) at 21 days of administration. The testicular cells in this group showed no pathological changes, the normal

testicular architecture was preserved and spermatogenesis occurred as compared with the normal control plate (5).

Plate 4 belongs to the normal dose (500mg/kg) at 21 days of administration. The testes in this group showed no pathological changes, the normal testicular architecture was preserved and spermatogenesis occurred as compared with the control plate (plate 5). From the photomicrographs above, it is evident that plates 1-4 show no gross or microscopic pathological changes on administration of methanolic extract of *Asparagus pubescens*. It is evident that the contraceptive activity of the extract on the male reproductive organ is not visible by histological technique and thus the extract can be seen not to exert any contraceptive effect on the testes and as such may not be effective as a male-contraceptive-based on histological studies. However, the mechanism of action of the extract has been known to be through a non-hormonal mechanism, since the extract lacks progestational effects and also has an antiestrogenic activity (Genazzani *et al.*, 2021). Estrogen is known to regulate fluid reabsorption in the male reproductive tract by triggering a protein involved in sodium transport. The estrogen content in the fluid in the rete testes contains numerous ER - estrogen receptors, fluid is reabsorbed in this region, and sperm cells are concentrated. However, if this does not occur, the sperm entering the epididymis are diluted and infertility results (Hadi, & Deaibil, 2020).

The root extract of *Asparagus pubescens* has been known to have antiestrogenic activity, which infers that if the estrogen activity is blocked by the administration of this extract, it could produce a



contraceptive effect and thus could be used as a male contraceptive.

## CONCLUSION

From this research work, we discovered that the methanolic extract of *Asparagus pubescens* roots did not exert any contraceptive effect on the histologic architecture of the testes, it also did not induce any pathological change in the testes of all the animals in the treatment group.

However, due to the mechanism of action of this extract (ie, it lacks progestational effect and has antiestrogenic activity), further work would be required to find out its antiestrogenic activity so as to ascertain if it could be suitable as a male contraceptive.

## RECOMMENDATIONS

- Further work should be carried out on the antiestrogenic activity of *Asparagus pubescens* on Sperm cells.
- Experiments on the effect of the extract on sperm motility should also be carried out.
- Experiment also of the effect of the extract on sperm concentration should also be carried out.
- Moreso further research work should also be carried out to determine if its antiestrogenic activity can be reversible so as to determine its suitability as a male contraceptive.

**Conflict of Interest:** There is no conflict of interest.

## ACKNOWLEDGEMENT

We wish to acknowledge Mr Beeter Nicodemus Akange for his assistance in administration of all needed to maintain and keep the animals subjects alive through out the course of this work and Miss Treasure Igbogi for some Secretarial work.

## REFERENCES

- Akbar, S. (2020). Handbook of 200 medicinal plants: a comprehensive review of their traditional medical uses and scientific justifications. Cham: Springer International Publishing. 1<sup>st</sup> edition, ISBN: 9783030168063.
- Al-Suhaimi, E. A., & Khan, F. A. (2022). The pituitary gland: functional relationship with the hypothalamus, structure, and physiology.

- In *Emerging Concepts in Endocrine Structure and Functions*, Springer Nature Singapore. (pp. 73-131).
- Babakhanzadeh, E., Nazari, M., Ghasemifar, S., & Khodadadian, A. (2020). Some of the factors involved in male infertility: a prospective review. *International journal of general medicine*, 29-41.
- Dibal, N. I., Garba, S. H., & Jacks, T. W. (2022). Histological stains and their application in teaching and research. *Asian Journal of Health Sciences*, 8 (2), ID43-ID43.
- Genazzani, A. R., Monteleone, P., Giannini, A., & Simoncini, T. (2021). Pharmacotherapeutic options for the treatment of menopausal symptoms. *Expert Opinion on Pharmacotherapy*, 22 (13), 1773-1791.
- Hadi, A. H. A., & Deaibil, H. B. (2020). Effect of royal jelly on sperm parameters in aluminum-treated male rats. *The Journal of Applied Tissue Engineering*, 7 (1), 8-17.
- Kang, C., Punjani, N., Lee, R. K., Li, P. S., & Goldstein, M. (2022, January). Effect of varicoceles on spermatogenesis. In *Seminars in Cell & Developmental Biology* (Vol. 121, pp. 114-124). Academic Press.
- Lynda, E. O., Kingsley, N. E., Obukohwo, O. M., Benneth, B. A., Victor, E., Simon, O. I., & Oghenetega, O. B. (2024). Arjunolic acid reverses fluoxetine-induced alterations in testicular steroidogenic enzymes and membrane bound ionic pump imbalance through suppression of oxidoinflammatory stress and apoptosis. *JBRA Assisted Reproduction*, 28 (1) 66-76.
- Heinrich, A., & DeFalco, T. (2020). Essential roles of interstitial cells in testicular development and function. *Andrology*, 8(4), 903-914.
- Roggenbuck, E. C., Hall, E. A., Hanson, I. B., Roby, A. A., Zhang, K. K., Alkatib, K. A., & Clowney, E. J. (2024). Let's talk about sex: Mechanisms of neural sexual differentiation in Bilateria. *WIREs Mechanisms of Disease*, 16 (2) 1636-1640
- Sobhy, Y., Mady, M., Mina, S., & Abo-zeid, Y. (2022). Phytochemical and Pharmacological Values of Two Major Constituents of *Asparagus* Species and Their Nano Formulations: A Review. *Journal of Advanced Pharmacy Research*, 6 (3), 94-106.
- Withers, P. C., & Cooper, C. E. (2023). Energy and Water Balance of Marsupials. In *American and Australasian Marsupials: An Evolutionary, Biogeographical, and Ecological Approach* (pp. 1-42). Cham: Springer International Publishing.

**Cite This Article:** Ilegbedion, Ikhide Godwin, Babepere, Prosper Ikechukwu, Mirinn, Kenneth Ebiakpo, Chukwuedo, Judith Nkechi (2024). Histologic, Progestational and Antiestrogenic Effects of Methanolic Extract of *Asparagus pubescens* (Roots) on the Male Reproductive Organs of Rabbit. *East African Scholars Multidiscip Bull*, 7(5), 91-96.