

## Case Report

## Laparoscopic Drainage of Liver Abscesses Case Report and Literature Review

Sarah Abbas Mohamed, MBBS, MRCS<sup>1</sup> and Abbas AR Mohamed, MBBS, FRCSI, FICS, FACS, FMRC<sup>2\*</sup>

<sup>1</sup>Specialty training registrar, general surgery, Wrexham Maelor Hospital–Wrexham –UK

<sup>2</sup>Consultant General and Laparoscopic Surgeon, Head of General Surgery Department, NGH –Madinah –KSA Saudi Arabia

\*Corresponding Author

Abbas AR Mohamed, MBBS, FRCSI, FICS, FACS, FMRC

**Abstract:** Pyogenic liver abscess is a suppurative infection of the hepatic parenchyma which usually associated with high morbidity and mortality if not diagnosed early and treated properly. We present a case of pyogenic liver abscess in an immunosuppressed patient who was treated with laparoscopic drainage and antibiotic therapy as first-line treatment without the need for other perioperative procedures.

**Keywords:** Pyogenic liver abscess, Laparoscopy.

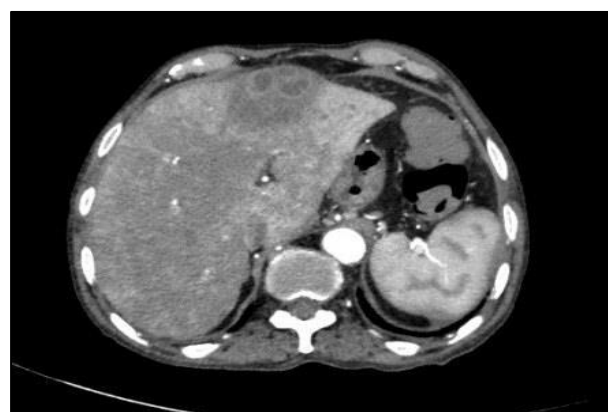
### INTRODUCTION

Modern imaging techniques have revolutionized the diagnosis and management of liver abscesses (Attar, B. *et al.*, 1986). At present percutaneous aspiration and drainage is considered as the most less invasive, safe and effective method of drainage with minimal morbidity and mortality. Laparoscopic drainage stands halfway between open surgical and percutaneous drainage and usually reserved for selected cases such as those in which percutaneous option has failed or patients with large multiloculated abscesses. We report a case of 81-years old man who presented with multiloculated left lobe liver abscess treated with laparoscopic drainage and antibiotic therapy as first-line treatment. We also review the literature for the role of laparoscopic drainage as first-line treatment in patients with a pyogenic liver abscess in comparison with percutaneous drainage.

### Case Report

A 81years old man was admitted to the surgical ward complaining of left hypochondrium pain and fever of two days duration. He was a known case of chronic myelomonocytic leukemia on immunosuppressive therapy. On admission, he was anemic, febrile and tachycardiac. His pulse rate was 108/minute, temperature 38.3°C and PB 85/55mm of Hg. Systemic examination was normal apart of mild tenderness over left hypochondrium. Laboratory

investigations revealed hemoglobin of (9.6 g/dl), WBCC 14.8x10<sup>9</sup> per L (neutrophils 84%). Liver function test showed mild elevation of liver enzymes. Urea, creatinine, and electrolytes were within normal values. His abdominal CT scan showed a large multiloculated heterogeneous hypodense lesion with peripheral enhancement in the left lobe of the liver measuring about 6x5x4 cm, most likely represent liver abscess along with consequent periportal edema around the left hepatic segmental portal veins branches. There was no intra or extra biliary dilatation and main portal veins were patent (figure 1-4).



**Figure1:** CT scan axial view showing the superficial multiloculated part of the abscess.

Quick Response Code



Journal homepage:

<http://www.easpublisher.com/easms/>

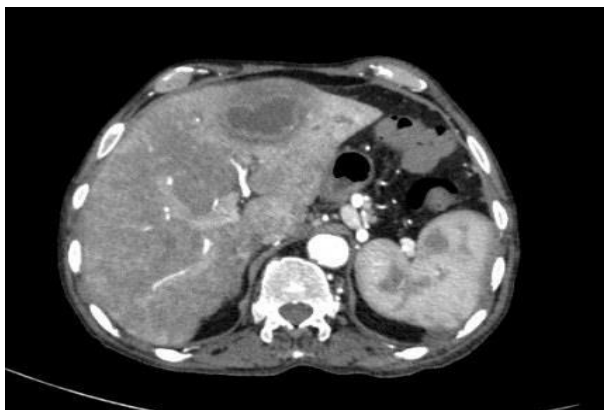
Article History

Received: 29.07.2019

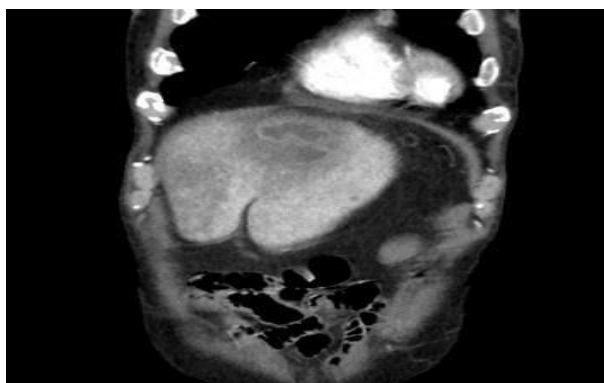
Accepted: 15.08.2019

Published: 31.08.2019

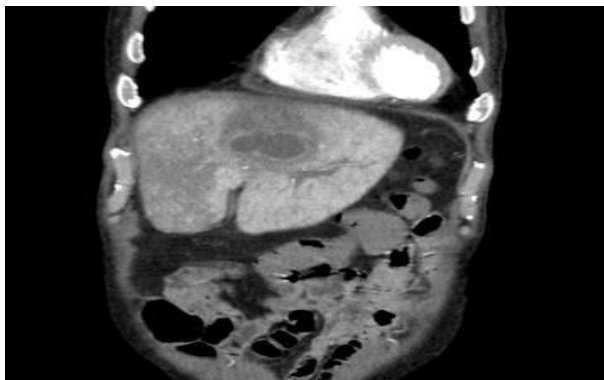
Copyright © 2019: This is an open-access article distributed under the terms of the Creative Commons Attribution license which permits unrestricted use, distribution, and reproduction in any medium for non commercial use (NonCommercial, or CC-BY-NC) provided the original author and source are credited.



**Figure2:** CT scan axial view showing the deep part of the abscess.



**Figure3:** CT scan coronary view showing the superficial part of the abscess.

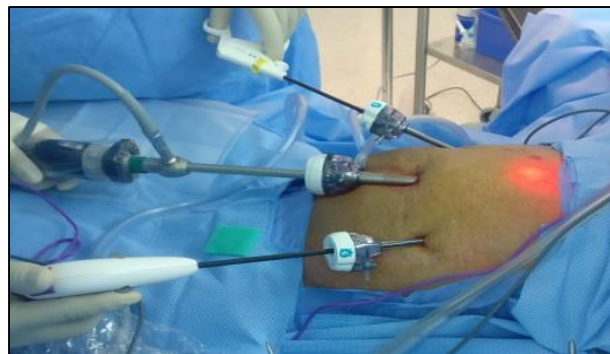

**Figure4:** CT scan coronary view showing the deep part of the abscess.

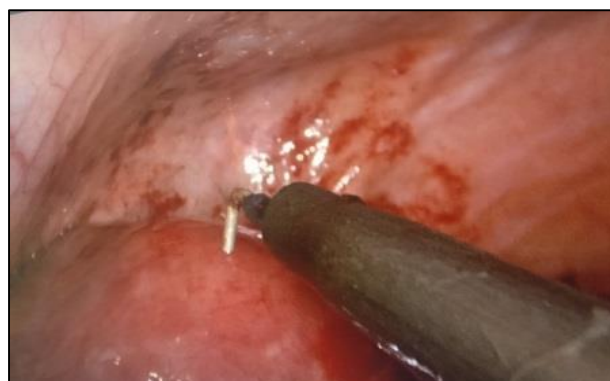Since the patient was in in septic shock in the presence of immunosuppression, and the multiloculation of the abscess on the CT scan we decided to proceed with laparoscopic drainage without initial trial of percutaneous drainage.

**Surgical technique:** under general anesthesia with endotracheal intubation, the patient was placed in a supine position, and pneumoperitoneum was introduced with a Verse's needle inserted through the umbilicus. A 10 mm camera was introduced through a 10 mm port introduced just below the umbilicus. Another 2 (5 mm torchers) were introduced about 10 cm lateral and 2- 5 cm above the level of the umbilicus (figure 5). The

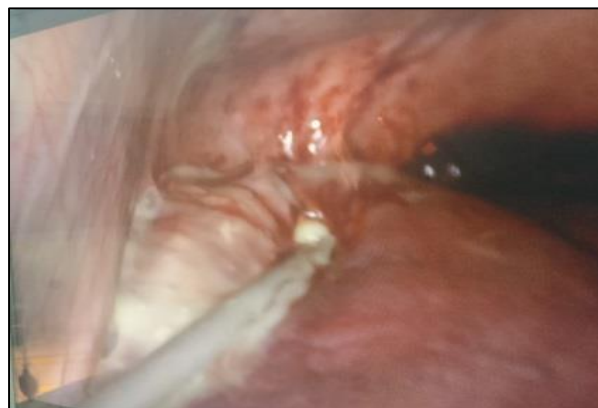abdomen was explored, and the abscess was seen as a bulge over the anterior surface of the left lobe of the liver just below the diaphragm (figure 6). The abscess cavity was entered by use of the diathermy and de roofed by use of the ultra-scission device. Debridement and irrigation of the abscess cavity were performed with an aspirator-irrigator apparatus (figure7). Two large-bored suction drain was placed into the abscess cavity and the subdiaphragmatic region and brought out from the 5 mm torcher sites (figure 8). The operative time was 45 minutes, and operative blood loss was minimal. The postoperative course was uneventful and the patient was discharged on the 7th postoperative day on oral antibiotic for another week. the pus culture revealed staphylococcus aureus infections.



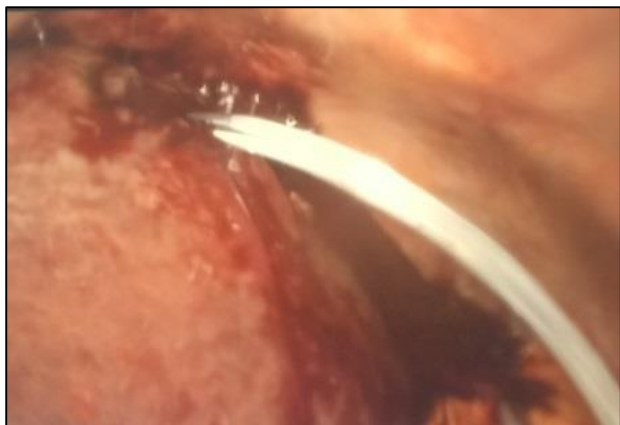**Figure 5:** torcher's position



**Figure 6:** the abscess seen as a bulge on the anterior surface of the liver just below the diaphragm.



**Figure 7:** Debridement and irrigation of the abscess cavity were performed with an aspirator-irrigator apparatus.



**Figure 8: placement of suction drain within the abscess cavity.**

#### **DISCUSSIONS: -**

Pyogenic liver abscess is a suppurative infection of the hepatic parenchyma. It is a rare, potentially fatal condition with a reported incidence of 20 per 100000 hospital admissions in western population (Pearce, N. W. *et al.*, 2003; Huang, C. J. *et al.*, 1996). When not diagnosed early and treated promptly, the pyogenic liver abscess can be fatal, with reported mortality rates as high as 80%-100% (Wong, K.P. 1990).

Early diagnosis and treatment are a crucial step in the management of patients with liver abscess and a high index of suspicion is the cornerstone of prevention for misdiagnosis and improvement of prognosis (Serraino, C. *et al.*, 2018; Ruiz-Hernandez, J. J. *et al.*, 2007). Ultrasonography and CT scan are important not only for confirmation of diagnosis but also for helping the decision for selection of the treatment option and guidance of percutaneous drainage.

Several methods are available to treat the pyogenic liver abscess. Patients presenting with multiple and small abscesses are the best candidates for antibiotic-alone therapy, but this therapy usually fails for a solitary liver abscess (Pearce, N. W. *et al.*, 2003).

Although small asymptomatic liver abscess can be treated conservatively with antibiotics alone, the mainstay of treatment of large and symptomatic abscesses is surgical drainage.

Historically, the treatment of choice for pyogenic liver abscess had been open surgical drainage (Ochsner, A. *et al.*, 1938).

Surgical drainage is associated with high therapeutic success rates and was the standard of care until the introduction of percutaneous drainage techniques (Heneghan, H. M. *et al.*, 2011). Introduction of modern imaging devices and radiological intervention techniques have revolutionized diagnosis and management of liver abscesses. At present, the

percutaneous approach to liver abscesses (which was initially described by MaFadzean *et al.*, (1953) from Hong Kong in 1953) is considered as the most less invasive, safe and effective method of drainage with minimal morbidity and mortality. Laparoscopic drainage stands halfway between open surgical drainage and percutaneous drainage and is usually reserved for selected cases as for patients with large multiloculated abscesses and when the percutaneous option has failed (Ekwunife, C. N. *et al.*, 2012).

Many authors (Swallow, C.J., & Rotstein, O.D. 1990; Ahmed, S. *et al.*, 2016; Xu, X.X. *et al.*, 2018) were reported percutaneous aspiration and percutaneous catheter drainage of liver abscesses are minimally invasive, safe and sufficient, however, they are not free of complications.

Serraino, Cristina *et al.*, (2018) in their study which included 109 case of liver abscess reported eleven deaths (10.1%), during the hospital admission, which resulted directly from the abscesses or the complication of their treatment. In their 85 patients who had to have ultrasound/CT guided percutaneous abscess drainage, They reported 2 cases of major complication: right pneumothorax, which resolved without drainage tube and one case of biliary fistulae which resolved after ERCP decompression and nose-biliary drainage.

The reported success rate of percutaneous drainage of pyogenic liver abscess range between 80–87% (Dominguez-Guzman, D.J. *et al.*, 2006). The failure of percutaneous drainage results from many factors including inappropriate catheter placement, multiple, large, or multiloculated abscess, thick-walled abscess with viscous pus and in immunocompromised patients.

Multilocation is the most difficult problem involved in the nonsurgical treatment of liver abscess and is regarded as one of the significant causes of failure in percutaneous catheter drainage or needle aspiration (Gerzof, S.G. *et al.*, 1985; Baek, S.Y. *et al.*, 1993).

The optimal treatment of multiloculated abscesses is still a subject of debate, as the multiloculated pyogenic liver abscesses are often contained viscid pus, or small locules of pus that are not communicating with each other, which may make percutaneous drainage difficult (Xu, X.X. *et al.*, 2018; Lai, K. C. *et al.*, 2013; Liao, W. I. *et al.*, 2012; Srivastava A. *et al.*, 2012).

Studies have been showed that the presence of multiloculated abscess lesions has been considered as one of the factors that increase the risk of percutaneous catheter drainage failure (Liu, C.-H. *et al.*, 2009; Chou, F.-F. *et al.*, 1997). And this literature showed that the mortality rates for multiloculated pyogenic liver

abscesses range from 44% to 22.1%, which was higher than single pyogenic liver abscess (Chou, F.-F. *et al.*, 1997; Giorgio, A. *et al.*, 2006). Besides, the multiloculated pyogenic liver abscess may need multiple percutaneous drains or surgical drainage.

Some authors (Liu, C.-H. *et al.*, 2009; Xu, X.X. *et al.*, 2018) tried to improve the success rate of percutaneous catheter drainage of multiloculated liver abscesses by using combination of catheter drainage and infusion of abscess cavity through the same drainage catheter with antiseptic agents and drugs that may reduce the viscosity of purulent material and cause lysis of fibrinous adhesions and loculations.

Li B, *et al.*, (2009) suggests a combination of catheter drainage and oxygen-ozone gas mixture (one of the best sterilization, antifungal, and antiviral agents) in management of patients with multiloculated pyogenic liver abscesses. They claimed that percutaneous catheter drainage combined with ozone improves the success rate from 86% in patients treated by percutaneous drainage alone to 96% in patients treated with combined percutaneous catheter drainage and oxygen-ozone gas mixture.

Few authors (Lohopa, J.M. *et al.*, 1993; Lee, J. M. *et al.*, 1997) reported the use of a combination of urokinase ( a fibrinolytic agent) and percutaneous catheter drainages for the treatment of a liver abscess is more effective than the use of percutaneous catheter drainage alone.

Theoretically, laparoscopic surgery provides better drainage than percutaneous drainage by allowing de roofing of the abscess cavity, suction of thick pus and irrigation of the abscess cavity, breaking the septa of multiloculated abscesses and placement of larger draining tubes within the abscess cavity and subdiaphragmatic and subhepatic space.

Although most of the problems associated with the percutaneous drainage can be solved by laparoscopic drainage, percutaneous techniques have been increasingly performed in place of surgical drainage as first-line treatment. This paradigm shift has been fueled by the drive for low-risk and less-invasive procedures and the surgical option being reserved for percutaneous failures (Tan, Y. M. *et al.*, 2005). Yet there is a lack of data to support percutaneous drainage over surgical drainage as first-line treatment (Tan, Y. M. *et al.*, 2005; Seeto, R.K., & Rockey, D.C. (1996).

Although many authors (Tay, K.H. *et al.*, 1998; Romano, G. *et al.*, 2013; Wang, W. *et al.*, 2004; Aydin, C. *et al.*, 2010) reported the high safety and success rates of laparoscopic drainage of liver abscesses as an alternative for patients requiring surgical drainage when others treatment has failed, unfortunately, there is a lack of sufficient published data to compare

percutaneous drainage to laparoscopic drainage as the first line of treatment. In such lack of published data, it seems that no confident verdict can be made without further studies in controlled trial setting. Nevertheless, in current good clinical practices, the choice of therapy needs to be individualized according to the patient's clinical status and abscess factors (Chung, Y.F. *et al.*, 2007). There is doubt that both techniques are complementary in the management of liver abscesses.

Aydin C, *et al.*, (2010) systematically reviewed the literature describing the experience with the laparoscopic approach and identified 53 cases of liver abscess treated by laparoscopy. The overall success rate was 90.5% and no reported case required conversion to open. From their review of this data, the authors concluded that laparoscopic surgery has the advantages of the high success rates of open surgery and the minimal invasiveness of percutaneous drainage (Heneghan, H. M. *et al.*, 2011).

Romano G, *et al.*, (2013) reported a case of a large, complex liver abscess treated successfully with laparoscopic drainage as first-line treatment. They reviewed the literature for laparoscopic drainage of liver abscess and concluded that not all liver abscesses can be treated with antibiotic therapy or percutaneous drainage. Laparoscopic drainage in association with systemic antibiotic therapy is a safe and effective minimally invasive approach that should be considered in selected patients.

Cioffi L, *et al.*, (2014) reported successfully treating ten patients with large multiloculated liver abscess by laparoscopic drainage without the need of other perioperative procedures. They claimed that laparoscopic drainage seems to be a safe and reproducible mini-invasive treatment for complex liver abscesses and it offers many advantages over percutaneous and surgical open approach.

Tay KH, *et al.*, reported treating twenty consecutive patients with liver abscesses by laparoscopic drainage in combination with intravenous antibiotics. They concluded that Laparoscopic drainage of liver abscesses, in combination with systemic antibiotics, is a safe and viable alternative in all patients who require surgical drainage following failed medical or percutaneous treatment, and in those with large abscesses (Tay, K.H. *et al.*, 1998).

Herman P, *et al.*, treated thirty-one patients with pyogenic liver abscesses by surgical drainage as first-line treatment. Their results suggest that surgical treatment is a good alternative as a first step not only for the treatment of the primary cause of the abscess but also in septic patients with a severe disease where a delay inadequate drainage, frequent in percutaneous management, can lead to high morbidity and mortality rates (Herman, P. *et al.*, 1997).

Tan, Yu-Meng *et al.*, compared between percutaneous drainage and surgical drainage as first-line treatment in 80 patients (percutaneous drainage was performed in 36 patients and surgical drainage in 44 patients). They concluded that surgical drainage should be considered as first-line treatment of large liver abscesses (> than 5 cm) as it provides better outcomes than percutaneous drainage in terms of treatment success, number of secondary procedures, and hospital stay with comparable morbidity and mortality rates (Tan, Y. M. *et al.*, 2005).

Barakate MS, *et al.*, (1999) suggested that multiloculation of liver abscesses contributes to poorer drainage reducing the effectiveness of percutaneous drainage. Surgical drainage allows for the breakdown of loculations and more complete drainage.

## CONCLUSION

Pyogenic liver abscess is usually associated with high morbidity and mortality if not diagnosed early and treated properly. Modern imaging techniques have revolutionized the diagnosis and management of liver abscesses. At present percutaneous aspiration and drainage is considered as the most less invasive, safe and effective method of drainage with minimal morbidity and mortality. Laparoscopic drainage stands halfway between open surgical drainage and percutaneous drainage and is usually reserved for selected cases as for patients with large multiloculated abscesses and when the percutaneous option has failed. Although many authors reported high safety and success rates of laparoscopic drainage of liver abscesses as an alternative for patients requiring surgical drainage when others treatment has failed, unfortunately, there is lack of sufficient published data to compare percutaneous drainage to laparoscopic drainage as first line treatment. Several studies suggested that the laparoscopic drainage is more effective than the percutaneous drainage in drainage of large abscesses, multiloculated abscesses and in immunosuppressed and septic patients, however, this has to be confirmed by further studies in a controlled trial setting. We believe that at present the choice of therapy needs to be individualized according to the patient's clinical status and abscess factors.

**Conflict of Interest:** None declared

## REFERENCES

1. Attar, B., Levendoglu, H., & Cuasay, N. S. (1986). CT--guided Percutaneous Aspiration and Catheter Drainage of Pyogenic Liver Abscesses. *American Journal of Gastroenterology*, 81(7).
2. Pearce, N. W., Knight, R., Irving, H., Menon, K., Prasad, K. R., Pollard, S. G., ... & Toogood, G. J. (2003). Non-operative management of pyogenic liver abscess. *HPB*, 5(2), 91-95.
3. Huang, C. J., Pitt, H. A., Lipsett, P. A., Osterman Jr, F. A., Lillemoe, K. D., Cameron, J. L., &

- Zuidema, G. D. (1996). Pyogenic hepatic abscess. Changing trends over 42 years. *Annals of surgery*, 223(5), 600.
4. Wong, K.P. (1990). Percutaneous drainage of pyogenic liver abscesses. *World J Surg*, 14, 492–497.
5. Serraino, C., Elia, C., Bracco, C., Rinaldi, G., Pomero, F., Silvestri, A., ... & Fenoglio, L. M. (2018). Characteristics and management of pyogenic liver abscess: A European experience. *Medicine*, 97(19).
6. Ruiz-Hernandez, J. J., León-Mazorra, M., Conde-Martel, A., Marchena-Gómez, J., Hemmersbach-Miller, M., & Betancor-León, P. (2007). Pyogenic liver abscesses: mortality-related factors. *European journal of gastroenterology & hepatology*, 19(10), 853-858.
7. Ochsner, A., DeBakey, M., & Murray, S. (1938). Pyogenic abscess of the liver. II: An analysis of forty-seven cases with review of the literature. *Am J Surg*, 40, 292–319.
8. Heneghan, H. M., Healy, N. A., Martin, S. T., Ryan, R. S., Nolan, N., Traynor, O., & Waldron, R. (2011). Modern management of pyogenic hepatic abscess: a case series and review of the literature. *BMC research notes*, 4(1), 80.
9. McFadzean, A.J.S., Chang, K.P.S., & Wong, C.C. (1953). Solitary pyogenic abscess treated by closed aspiration and antibiotics: fourteen consecutive cases with recovery. *Br J Surg*, (41), 141–152.
10. Ekwunife, C. N., Amadi, E. C., Amaechi, F. N., & Ukaha, I. C. (2012). Laparoscopy-guided liver abscess drainage: An additional use of veress needle. *Journal of surgical technique and case report*, 4(1), 36-38.
11. Swallow, C.J., & Rotstein, O.D. (1990). Management of pyogenic liver abscess in the era of computed tomography. *Can J Surg*. 1990 Oct; 33(5), 355-62.
12. Ahmed, S., Chia, C.L., Junnarkar, S.P., Woon, W., & Shelat, V.G. (2016). Percutaneous drainage for giant pyogenic liver abscess--is it safe and sufficient? *Am J Surg*. 2016 Jan;211(1), 95-101.
13. Xu, X.X., Liu, C., Wang, L., Li, Y., Yang, H.F., Du, Y., Zhang, C., & Li, B. (2018). Computed tomography-guided catheter drainage with ozone in management of pyogenic liver abscess. *Pol J Radiol*. 2018 Jun 12; 83:e275-e279.
14. Dominguez-Guzman, D.J., Moreno-Portillo, M., Garcia-Flores, C., et al. (2006). Laparoscopic drainage of liver abscess. Initial experience *Cir Cir* 2006May-Jun743189–94.
15. Gerzof, S.G., Johnson, W.C., Robbins, A.H., & Nabeth, D.C. (1985). Expanded criteria for percutaneous abscess drainage. *Arch Surg*, 120 227-232.
16. Baek, S.Y., Lee, M.G., Cho, K.S., Lee, S.C., Sung, K.B., & Auh, Y.H. (1993). Therapeutic percutaneous aspiration of hepatic abscess: effectiveness in 25 patients. *AJR*, 160, 799-802.

17. Lohota, J.M., Haaga, J.R., Stellato, T., Flanigan, T., & Graham, R. (1993). Safety of intracavitary urokinase with percutaneous abscess drainage. *AJR* 1993; 160, 171-174.
18. Lai, K. C., Cheng, K. S., Jeng, L. B., Huang, C. C., Lee, Y. T., Chang, H. R., ... & Lee, M. C. (2013). Factors associated with treatment failure of percutaneous catheter drainage for pyogenic liver abscess in patients with hepatobiliary-pancreatic cancer. *The American Journal of Surgery*, 205(1), 52-57.
19. Liao, W. I., Tsai, S. H., Yu, C. Y., Huang, G. S., Lin, Y. Y., Hsu, C. W., ... & Chang, W. C. (2012). Pyogenic liver abscess treated by percutaneous catheter drainage: MDCT measurement for treatment outcome. *European journal of radiology*, 81(4), 609-615.
20. Srivastava, A., Yachha, S. K., Arora, V., Poddar, U., Lal, R., & Baijal, S. S. (2012). Identification of high-risk group and therapeutic options in children with liver abscess. *European Journal of Pediatrics*, 171(1):33-41.
21. Liu, C.-H., Gervais, D. A., Hahn, P. F., Arellano, R. S., & Uppot, R. N. (2009). Mueller, P. R. Percutaneous Hepatic Abscess Drainage: Do Multiple Abscesses or Multiloculated Abscesses Preclude Drainage or Affect Outcome? *Journal of Vascular and Interventional Radiology*, 20(8), 1059-1065.
22. Chou, F.-F., Sheen-Chen, S.-M., Chen, Y.-S., & Chen, M.-C. (1997). Single and multiple pyogenic liver abscesses: Clinical course, etiology, and results of treatment. *World Journal of Surgery*, 21(4), 384-389.
23. Giorgio, A., De Stefano, G., Di Sarno, A., Liorre, G., & Ferraioli, G. (2006). Percutaneous needle aspiration of multiple pyogenic abscesses of the liver: 13-Year single-center experience. *American Journal of Roentgenology*, 187(6):1585-1590.
24. Lee, J. M., Lee, M. S., Lee, J. H., Ym, S. H., Kim, C. S., Han, Y. M., & Choi, K. C. (1997). Intracavitary urokinase in the treatment of multiloculated liver abscess: a case report. *Journal of the Korean Radiological Society*, 37(2), 317-320.
25. Tan, Y. M., Chung, A. Y. F., Chow, P. K. H., Cheow, P. C., Wong, W. K., Ooi, L. L., & Soo, K. C. (2005). An appraisal of surgical and percutaneous drainage for pyogenic liver abscesses larger than 5 cm. *Annals of surgery*, 241(3), 485.
26. Seeto, R.K., & Rockey, D.C. (1996). Pyogenic liver abscess: changes in etiology, management, and outcome. *Medicine (Baltimore)*, 75, 99-113.
27. Tay, K.H., Ravintharan, T., Hoe, M.N., See, A.C., & Chng, H.C. (1998). Laparoscopic drainage of liver abscesses. *Br J Surg*, Mar;85(3), 330-2.
28. Romano, G., Agrusa, A., Frazzetta, G., De Vita, G., Chianetta, D., Di Buono, G., Amato, G., & Gulotta, G. (2013). Laparoscopic drainage of liver abscess: case report and literature review. *G Chir*. 2013 May-Jun; 34 (5-6), 180-2.
29. Wang, W., Lee, W.J., Wei, P.L., Chen, T.C., & Huang, M.T. (2004). Laparoscopic drainage of pyogenic liver abscesses. *Surg Today*, 34(4), 323-5.
30. Aydin, C., Piskin, T., Sumer, F., Barut, B., & Kayaalp, C. (2010). Laparoscopic drainage of pyogenic liver abscess. *JLS*, Jul-Sep; 14(3), 418-20.
31. Chung, Y.F., Tan, Y.M., Lui, H.F., Tay, K.H., Lo, R.H., Kurup, A., & Tan, B.H. (2007). Management of pyogenic liver abscesses - percutaneous or open drainage? *Singapore Med J*. 2007.
32. Heneghan, H. M., Healy, N. A., Martin, S. T., Ryan, R. S., Nolan, N., Traynor, O., & Waldron, R. (2011). Modern management of pyogenic hepatic abscess: a case series and review of the literature. *BMC research notes*, 4(1), 80.
33. Cioffi, L., Belli, A., Limongelli, P., Russo, G., Arnold, M., D'Agostino, A., ... & Belli, G. (2014). Laparoscopic Drainage as First Line Treatment for Complex Pyogenic Liver Abscesses. *Hepato-gastroenterology*, 61(131), 771-775.
34. Tay, K.H., Ravintharan, T., Hoe, M.N., See, A.C., & Chng, H.C. (1998). Laparoscopic drainage of liver abscesses. *Br J Surg*. 1998 Mar, 85(3), 330-2.
35. Herman, P., Pugliese, V., Montagnini, A.L., Salem, M.Z., Machado, M.A., da Cunha, J.E., Bacchella, T., Machado, M.C., & Pinotti, H.W. (1997). Pyogenic liver abscess: the role of surgical treatment. *Int Surg*. 1997 Jan-Mar;82(1):98-101.
36. Barakate, M. S., Stephen, M. S., Waugh, R. C., Gallagher, P. J., Solomon, M. J., Storey, D. W., & Sheldon, D. M. (1999). PYOGENIC LIVER Abscess: A Review Of 10 Years' experience in Management. *Australian And New Zealand Journal Of Surgery*, 69(3), 205-209.