

Case Report

A Rare Case of Lipomyelocele

Deepthi Ashok*, Kalaichezhian Mariappan, Venkatraman Indran, Prabakaran Marimuthu

Department of Radiodiagnosis, Sree Balaji Medical College and Hospital, Chennai, Tamilnadu, India

Article History

Received: 21.09.2020

Accepted: 11.10.2020

Published: 21.10.2020

Journal homepage:

<https://www.easpublisher.com/easjms>

Quick Response Code



Abstract: Gastrulation, primary neurulation and secondary neurulation are the stages of spinal cord development. Spinal dysraphisms are caused due to aberration in the stages. Lipomyelocele is an occult spinal dysraphism with an estimated incidence of 3.1 cases per 10,000 people. Early detection and prompt neurosurgical intervention is mandatory, for which spinal neuroimaging plays a critical role. Here, we present to a rare case of lipomyelocele with pilonidal sinus.

Keywords: Lipomyelocele, Spinal dysraphism, lipoma, Tract, Dorsal dermal sinus, Pilonidal sinus, Spinal cord neurulation.

Copyright © 2020 The Author(s): This is an open-access article distributed under the terms of the Creative Commons Attribution **4.0 International License (CC BY-NC 4.0)** which permits unrestricted use, distribution, and reproduction in any medium for non-commercial use provided the original author and source are credited.

INTRODUCTION

A 22-year-old complained of painless watery discharge with blood stain from the lower back for 2 months. The sinus was small in size initially, which progressively increased in size. On examination, there was dimpling of skin overlying the vertebra and an external opening [1]. Incidentally, the patient also had a pilonidal sinus with recurrent history of infections in the past. There was no localised tenderness or increase in temperature. There was no abnormal vessel at the external site. There was no co morbidities. The blood work was unremarkable [2].

EXPERIMENTAL SECTION

MRI findings revealed a cutaneous opening in the left para median region of the back at S1 level A

thick curvilinear tract measuring ~ 10-12 mm in cross section and about 9-10 cm in length seen in the subcutaneous plane extending anteriorly and medially from the cutaneous opening. The inferior end of the tract was seen in the intergluteal cleft. Adjacent inflammatory changes seen in the subcutaneous fat plane. There was a lipoma measuring ~ 42 x 23 mm in sacral region in subcutaneous plane at S3-S5 level with a component of about 21 x 16 mm located within the sacral canal at S3-S4 level. Posterior elements of S3 to fifth coccygeal vertebrae appear deficient. Conus medullaris appears low placed with tip at L4 level. Filum Terminale is tethered to the above-mentioned lipoma. Inferior aspect of the sinus tract is seen along and abutting the posterior aspect of the above-mentioned lipoma. No extension of the sinus tract was seen into the sacral canal.

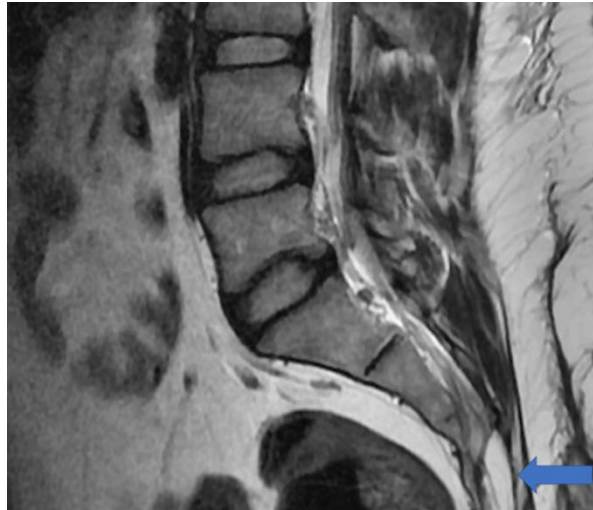


Fig-1: T1WI in sagittal plane shows a well-defined hyperintense ovoid lipoma in the subcutaneous plane of sacral region

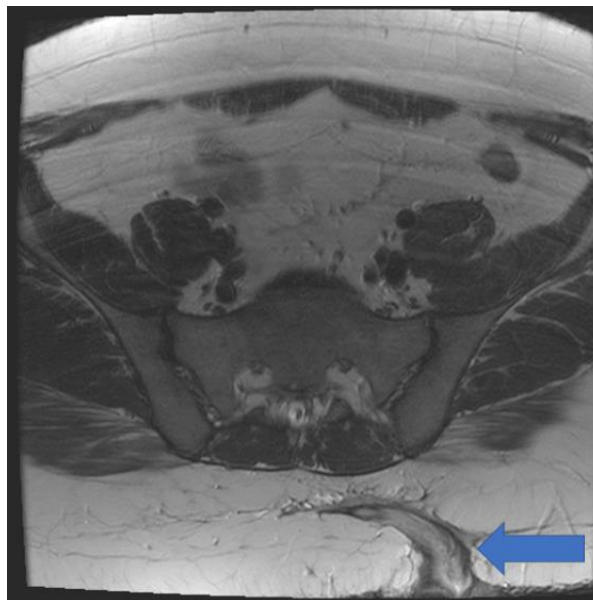


Fig-2: T1WI in axial section showing a thick curvilinear tract in the subcutaneous plane extending anteriorly and medially

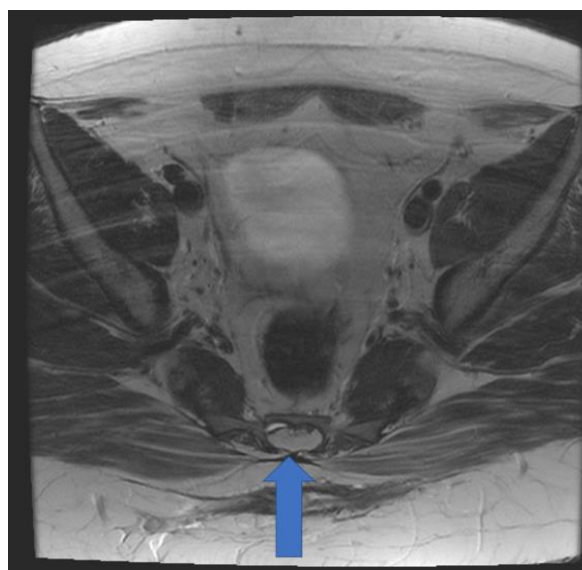


Fig-3: T1WI in axial section showing a well-defined round hyperintense intramedullary lipoma which is seen compressing the cauda equina nerve roots on the dorsal aspect

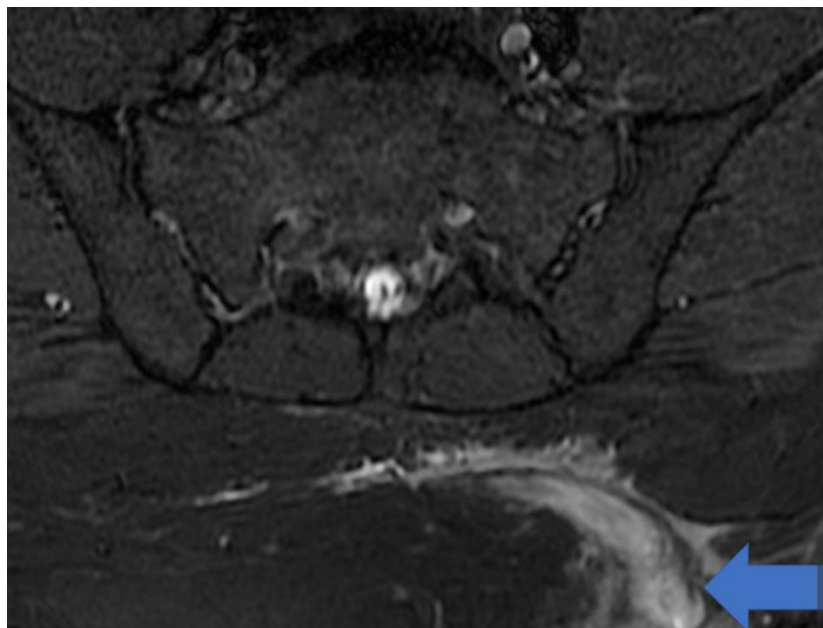


Fig-4: MR Fistulogram STIR T2 FSI showing the thick curvilinear T2 hyperintense tract curving anteriorly and medially with surrounding inflammatory changes

DISCUSSION

Lipomyelocele, Lipomyelomeningocele, dorsal dermal sinus and diastometamyelia comprise the most common occult spinal dysraphisms. Prevalence of spinal dysraphism is estimated to be 3.1 cases per 10,000 people [3].

Dural defect is a common feature seen in both lipomyelocele and lipomyelomeningocele, and the extension of the neural placode-lipoma interface outside the spinal canal decides the differentiation between the two which is seen in the latter. The main pathology in the two entities is defective primary neurulation, and the mesenchymal tissue, which normally is not seen here, forming lipomatous tissue after entering the neural tube. A low-lying spinal cord tethered by a lipoma is seen on ultrasound. The subcutaneous tissues at the back are contiguous with the lipoma and to insert on the cord, they extend through a posterior bone defect [4]. Low positioning of the conus, decreased / absent “to – and – fro” motion of the cord during real time imaging are few findings that suggest a tethered cord. The confirmation of lipoma is done by MRI (high signal on T1 and T2), and the subcutaneous tissues are seen contiguous with the lipoma, causing tethering and extending through a posterior spinal canal defect. If meningocele is present, it tends to extend to the opposite side of the lipoma and is asymmetric. Other issues like urinary infection, permanent neurological damage is common in patients with occult spinal dysraphism. Thus, early detection and prompt neurosurgical intervention is mandatory, for which spinal neuroimaging plays a critical role [5].

CONCLUSION

Due to the high risk of neurological impairment, occult spinal dysraphisms like lipomyelocele are an uncommon but clinically important diagnosis. After the discovery of skin stigmata on physical examination, they are detected initially on ultrasound. For further characterisation of ultrasound findings, MRI is useful.

REFERENCES

1. Medina, L. S., Crone, K., & Kuntz, K. M. (2001). Newborns with suspected occult spinal dysraphism: a cost-effectiveness analysis of diagnostic strategies. *Pediatrics*, *108*(6), e101-e101.
2. Shin, M., Besser, L. M., Siffel, C., Kucik, J. E., Shaw, G. M., Lu, C., ... & Prevalence, C. A. M. (2010). Prevalence of spina bifida among children and adolescents in 10 regions in the United States. *Pediatrics*, *126*(2), 274-279.
3. Rufener, S. L., Ibrahim, M., Raybaud, C. A., & Parmar, H. A. (2010). Congenital spine and spinal cord malformations—pictorial review. *American Journal of Roentgenology*, *194*(3_supplement), S26-S37.
4. Muthukumar, N. (2009). Congenital spinal lipomatous malformations. *Acta neurochirurgica*, *151*(3), 189-197.
5. Korsvik, H. E., & Keller, M. S. (1992). Sonography of occult dysraphism in neonates and infants with MR imaging correlation. *Radiographics*, *12*(2), 297-306.