

Case Report

Child with Rifampicin-Resistant Tuberculous Meningitis: A Case Report

Boudriiya Tamer^{1,2*}, El Mamoune Mostaine^{1,2}, Mejdoub Sara^{1,2}, Souly Karim^{1,2}, Zouhdi Mimoun^{1,2}¹Laboratory of Microbiology, Ibn Sina University Medical Center of Rabat, 10100, Morocco²Mohammed V University Faculty of Medicine and Pharmacy in Rabat, Morocco

Article History

Received: 14.01.2024

Accepted: 20.02.2024

Published: 29.11.2024

Journal homepage:

<https://www.easpublisher.com>

Quick Response Code



Abstract: Background: Tuberculosis remains a significant global health concern, with increasing incidence of drug-resistant strains posing challenges to effective treatment. We present a case of rifampicin-resistant tuberculous meningitis in an immunocompetent child, highlighting the severity and complexity of tuberculosis in pediatric populations. **Case report:** An 11-year-old child with a family history of tuberculosis was hospitalized for febrile meningeal syndrome. Symptoms included progressively developing headaches, vomiting, food refusal, and right hemiparesis over 10 days. Upon admission, the patient was conscious with a fever of 38.2°C and a stiff neck. Biological analyses revealed neutrophil-predominant hyperleukocytosis, lymphopenia, and hyponatremia. Cerebrospinal fluid analysis showed a predominance of lymphocytes and hypoglycorrhachia. The Xpert MTB/RIF ultra test confirmed tuberculous meningitis with detection of the rifampicin resistance gene. Imaging revealed active hydrocephalus. Second-line treatment was initiated, involving multiple medications over 24 months. This observation underscores the complexity of tuberculous meningitis in children, necessitating an individualized therapeutic approach. **Conclusion:** Drug-resistant tuberculous meningitis in children represents a complex and devastating medical challenge. Progress in diagnosis, while significant, underlines the need for a nuanced approach and ongoing research to improve screening tools.

Keywords: Immunocompetent, Meningitis, Tuberculosis, Drug resistance, Children, Diagnosis, Treatment.

Copyright © 2024 The Author(s): This is an open-access article distributed under the terms of the Creative Commons Attribution **4.0 International License (CC BY-NC 4.0)** which permits unrestricted use, distribution, and reproduction in any medium for non-commercial use provided the original author and source are credited.

INTRODUCTION

Tuberculosis is a chronic infectious disease of bacterial origin, primarily caused by *Mycobacterium tuberculosis*. This condition typically affects the lungs, although it can also spread to other parts of the body.

According to data from the World Health Organization (WHO) for the year 2021, the incidence of tuberculosis was 10.6 million cases, resulting in 1.6 million deaths during the same period. Globally, tuberculosis ranks thirteenth among causes of mortality, second only to COVID-19 among infectious diseases [1].

The increasing incidence of drug-resistant tuberculosis is a concerning reality. According to WHO estimates, the number of patients with drug-resistant tuberculosis reached 450,000 in 2021, marking a 3.1% increase compared to the 437,000 cases in 2020 [2].

Tuberculous meningitis (TBM) represents the most devastating and disabling form of tuberculosis in children and adolescents.

We report a case of rifampicin-resistant tuberculous meningitis in an immunocompetent child.

CASE PRESENTATION

An 11-year-old child was admitted to the pediatric department of the Children's Hospital in Rabat for febrile meningeal syndrome.

The patient has a history of hospitalization in the neonatology department for maternal infection. Additionally, there is a family history of an uncle who passed away two months ago due to pulmonary tuberculosis.

*Corresponding Author: Boudriiya Tamer

Laboratory of Microbiology, Ibn Sina University Medical Center of Rabat, 10100, Morocco

The disease history dates back 10 days with the progressive onset of fever, headaches, projectile vomiting, food refusal, and right hemiparesis.

Upon admission, the clinical examination reveals a conscious patient (Glasgow Coma Scale 15/15), with a fever of 38.2 degrees Celsius. Neurological examination shows a stiff neck with a positive Kernig sign. There is an absence of night sweats and purpura spots. The rest of the clinical examination was unremarkable.

Upon admission, the laboratory findings showed a hemoglobin level of 14 g/dl, hyperleukocytosis at 11,460/mm³ predominantly composed of neutrophilic granulocytes (9,530/mm³, 83%), and lymphopenia at 1,000/mm³. The erythrocyte sedimentation rate (ESR) was 24 mm in the first hour, C-reactive protein (CRP) was 12 mg/l, and there was hyponatremia at 128 mmol/l. Blood glucose, liver function, and renal function were within normal ranges.

The cerebrospinal fluid (CSF) cyto-bacteriological examination revealed a clear appearance with the presence of 170 white blood cells per mm³ (90% lymphocytes). Direct examination after Gram staining was negative, and cultures on chocolate polyvitex agar and blood agar, incubated at 35°C in a 5% CO₂ atmosphere, yielded negative results.

The biochemical analysis of the CSF revealed elevated protein levels at 0.74 g/l, decreased glucose levels at 0.3 g/l (with a concomitant blood glucose level of 0.85 g/l), and reduced chloride levels at 106 mmol/l.

This clinico-biological picture led to the suspicion of tuberculous meningitis, and a test for Mycobacterium tuberculosis complex DNA using the

Xpert MTB/RIF ultra (GeneXpert ®) was positive, with the presence of the rifampicin resistance gene.

Direct CSF examination after Ziehl Neelsen staining was negative, Culture on Lowenstein-Jensen medium became positive after one month (Fig 1).

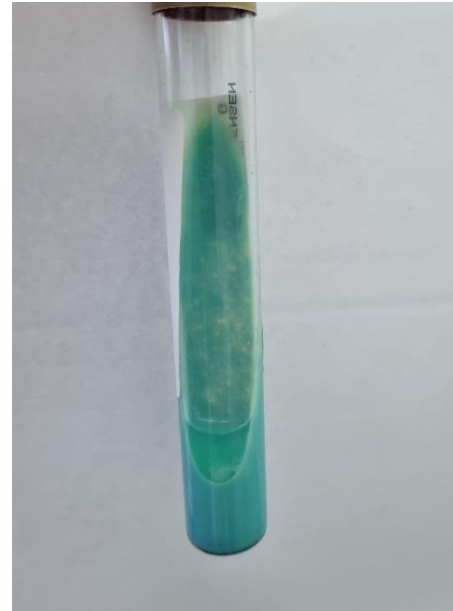

Figure 1: Mycobacterium tuberculosis colonies on Löwenstein-Jensen medium

The search for Mycobacterium tuberculosis in three-day sputum samples was negative. Chest X-ray and thoracic computed tomography (CT) scans were unremarkable.

Brain magnetic resonance imaging (MRI) revealed active ventricular hydrocephalus (Fig 2).

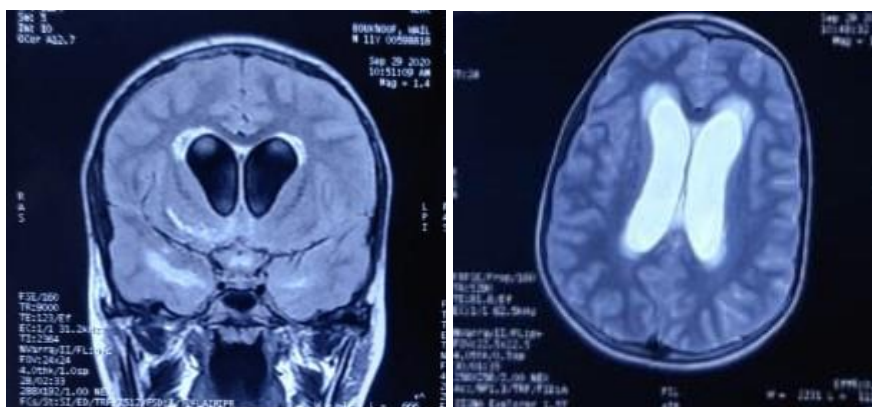


Figure 2: MRI images showing active ventricular hydrocephalus

Immunoglobulin (IgG, IgM, and IgA) levels were normal, and HIV screening test results were negative.

Specialist advice was sought from the pneumology/phthisiology department at Moulay

Youssef Hospital in Rabat, and second-line treatment was initiated with: Amikacin 500mg IVL 6 days /7 for 40 days. Levofloxacin 500mg for 24 months, Linezolid 300mg per day for 24 months, Bedaquiline 100mg/day for 14 days, then 1 tablet every other day for 6 months, Clofazimine 50mg per day for 24 months, Cycloserine 1

capsule per day for 24 months and vitamin B6 1 tablet per day for 24 months.

DISCUSSION

Tuberculosis remains one of the infectious diseases that threaten the health of children. This population is often different from adults in terms of clinical manifestations, diagnosis and treatment.

It is a disease that most often affects the lungs, but some of the most devastating clinical consequences result from the ability of *Mycobacterium tuberculosis* to spread from the lung to other organs. The transfer of bacteria from the initial site of infection (the pulmonary alveoli) to regional lymph nodes and other sites has two contradictory consequences. Firstly, it facilitates the presentation of *M. tuberculosis* antigens in regional lymph nodes, essential for the development of a protective T-cell-mediated immune response. Secondly, it leads to the dissemination of bacteria from the lung to other organs, and can result in severe forms of the disease, such as miliary and meningeal tuberculosis [3].

The pathogenesis of TBM continues to be a subject of debate. A key feature of mycobacterial virulence is the ability to invade the blood-brain and blood-cerebrospinal fluid barriers. The mechanisms of invasion are not entirely clear, although *in vitro* and animal data suggest that *M. tuberculosis* may rearrange the actin in the layers of endothelial cells of cerebral microvessels, facilitating its penetration [4, 5].

It is also possible that a "Trojan horse" mechanism, wherein *M. tuberculosis* is transported across the blood-brain barrier by infected monocytes and neutrophils, might occur [6]. Rich and McCordock described the development of a "Rich focus" in the context of TBM pathogenesis [7, 8]. It is suggested that the Rich focus forms through the activation of microglial cells and astrocytes once the bacilli have gained access to the brain. Once formed, Rich foci can become active rapidly or months to years later, leading to the release of *M. tuberculosis* into the subarachnoid space, triggering an inflammatory cascade [8].

The resulting inflammatory changes may explain some of the clinical characteristics associated with TBM. Firstly, peri-vascular inflammation, especially of the middle cerebral artery, leads to reduced perfusion and cerebral infarction. Secondly, the extension of exudative material to the basal cisterns and midbrain results in disruption of CSF flow, hydrocephalus, and elevated intracranial pressure. Thirdly, exudates envelop cranial nerves, causing cranial nerve palsies. Finally, expanding parenchymal tubercles may form tuberculomas and, less frequently, brain abscesses.

The symptomatology of TBM can be acute, subacute, or progressive and is characterized by

nonspecific symptoms in the early stages, such as malaise, mild fever, symptoms related to pulmonary tuberculosis, and/or flu-like syndrome. About half of TBM patients are exposed to someone with sputum-smear positive pulmonary tuberculosis [9]. Children with more advanced diseases may exhibit signs of meningeal irritation, cranial nerve palsies, neurological deficits, altered perception, and movement disorders [10].

The biochemical analysis of CSF reveals a clear appearance, a low level of glucose (hypoglycorrhachia) or a glucose/serum glucose ratio <50%, a generally elevated protein concentration ranging from 0.45 to 3.60 g/L, and often high levels of lactate at 5–10 mmol/L (normal range, 1.2–2.1 mmol/L) [11, 12].

The cytobacteriological diagnosis of TBM relies on conventional microscopy after Ziehl-Neelsen (ZN) staining of CSF to detect acid-fast bacilli (AFB), mycobacterial culture of CSF, and, if available, detection of mycobacterial DNA in CSF.

In cytobacteriological terms, the total number of leukocytes in CSF can vary from 5 to 1,000 x 10³/mL with a predominance of lymphocytes over neutrophils. Neutrophils may dominate early in the pathological process, and their presence is associated with better survival, as suggested by a retrospective study involving 84 cases of tuberculous meningitis conducted by Jeren T *et al.*, [13].

The Ziehl-Neelsen staining for smear examination has a sensitivity of approximately 50%, whereas bacterial culture ranges from 60% to 70% [14]. This limitation is likely due to the fact that TBM is a paucibacillary infection [9].

The yield of cerebrospinal fluid examination can be increased by implementing simple measures such as collecting at least 10 ml of CSF, conducting repeated examinations of samples, and performing a lumbar puncture before or shortly after initiating treatment. Additionally, it should be centrifuged at a high centrifugal force for 20 minutes, followed by a thorough examination for at least 20 minutes [15].

Considering the relatively low sensitivity of direct examination and the inherent delay in culture, molecular diagnostic methods for tuberculosis have been developed. Xpert MTB/RIF is a fully automated PCR test on a cartridge that enables rapid diagnosis (in less than 2 hours) of tuberculosis and the detection of rifampicin resistance.

For TBM specifically, Xpert MTB/RIF demonstrated a sensitivity of 80.5% (95% CI 59.0–92.2%) and specificity of 97.8% (95% CI 95.2–99.0%) compared to culture results. Based on these findings, the WHO recommended the use of Xpert MTB/RIF as the

preferred initial test for the diagnosis of tuberculous meningitis [16].

More recently, a Cochrane review on the diagnostic utility of Xpert MTB/RIF for extrapulmonary tuberculosis has been conducted. This study found a sensitivity of 71.1% (95% CI 60.9–80.4%) and specificity of 98% (95% CI 97.0–98.8%) for CSF samples evaluated for TBM [17].

An improved version of the Xpert MTB/RIF test, called Xpert MTB/RIF Ultra (Xpert Ultra), has recently been developed with the aim of enhancing the sensitivity of Mycobacterium tuberculosis detection and increasing the ability to detect rifampicin resistance [18]. This technique is used in our central bacteriology laboratory at Ibn Sina University Hospital in Rabat.

The improved limit of detection (LOD) of Xpert Ultra exceeds that of Xpert MTB/RIF, reaching approximately 15.6 colony-forming units per milliliter (cfu/mL) compared to 116 cfu/mL for the latter. Research by Dorman et al revealed that Xpert Ultra demonstrated higher sensitivity than Xpert MTB/RIF in HIV-positive patients with paucibacillary disease. These findings led to the current update of the WHO recommendation, advocating for the primary use of Xpert Ultra for TBM diagnosis [9].

According to a recent meta-analysis including data from 20 studies, the adenosine deaminase assay, which is classically used in the diagnosis of pleural, pericardial and peritoneal tuberculosis, can be performed on CSF with a sensitivity of 89% (CI: 84 to 92%) and a specificity of 91% (CI: 87 to 93%) [19-21].

Hyponatremia is highly prevalent in TBM, found in 50% of patients. Initially, this anomaly was attributed to the cerebral salt-wasting syndrome [22]. More recently, patients have been diagnosed with the syndrome of inappropriate antidiuretic hormone secretion (SIADH); however, many patients have been found with normal levels of antidiuretic hormone [23]. Evolving understanding suggests that both mechanisms could play a role in the occurrence of hyponatremia in TBM, highlighting the complexity of the condition and the need for a nuanced approach to diagnosis and treatment.

Imaging also plays a crucial role in the diagnosis of tuberculous meningitis. In various studies, it has been demonstrated that magnetic resonance imaging (MRI) has higher sensitivity than computed tomography (CT). CT itself may be initially normal in almost 30% of cases. Therefore, an initially normal neuroimaging does not exclude the possibility of tuberculous meningitis. The most frequent neuroradiological abnormalities include hydrocephalus (80%), basal meningeal enhancement (75%), infarcts (8%–44%), and tuberculomas (8%–31%) [15].

In addition to diagnostic challenges, managing multidrug-resistant tuberculosis is a significant challenge. The tests currently available in our center (Xpert® MTB/RIF Ultra) can relatively and easily detect rifampicin resistance but not isoniazid resistance. Therefore, cases of rifampicin-resistant tuberculosis are treated as multidrug-resistant cases.

Therapeutic regimens should be based on the study of sensitivity to various antibiotics, particularly fluoroquinolones, which play a crucial role in the treatment of multidrug-resistant tuberculosis. After more than 40 years of exploration, old drugs such as Linezolid and two new agents (bedaquiline and delamanid) are available for the treatment of MDR/XDR-TB [24, 25].

Different antitubercular drugs exhibit distinct pharmacokinetics in children compared to adults, and some have low permeability in CSF due to the blood-brain barrier. Therefore, when developing a treatment regimen for multidrug-resistant tuberculosis with central nervous system involvement, it is necessary to include at least four effective drugs, with two or three having moderate permeability into the CSF [26].

CONCLUSION

Drug-resistant tuberculous meningitis in children represents a complex and devastating medical challenge. Progress in diagnosis, while significant, underlines the need for a nuanced approach and ongoing research to improve screening tools. Although molecular biology techniques represent a step forward, they cannot completely exclude the disease, hence the need to reinforce training for healthcare professionals in early diagnosis and rapid management.

REFERENCES

1. Tuberculose [Internet]. [cité 4 déc 2023]. Disponible sur: <https://www.who.int/fr/news-room/fact-sheets/detail/tuberculosis>
2. Augmentation du nombre de cas de tuberculose et de décès dus à la maladie pendant la pandémie de COVID-19 [Internet]. [cité 4 déc 2023]. Disponible sur: <https://www.who.int/fr/news/item/27-10-2022-tuberculosis-deaths-and-disease-increase-during-the-covid-19-pandemic>
3. Krishnan, N., Robertson, B. D., & Thwaites, G. (2010). The mechanisms and consequences of the extra-pulmonary dissemination of Mycobacterium tuberculosis. *Tuberculosis*, 90(6), 361-366.
4. Jain, S. K., Paul-Satyaseela, M., Lamichhane, G., Kim, K. S., & Bishai, W. R. (2006). Mycobacterium tuberculosis invasion and traversal across an in vitro human blood-brain barrier as a pathogenic mechanism for central nervous system tuberculosis. *The Journal of infectious diseases*, 193(9), 1287-1295.
5. Be, N. A., Kim, K. S., Bishai, W. R., & Jain, S. K. (2009). Pathogenesis of central nervous system

- tuberculosis. *Current molecular medicine*, 9(2), 94-99.
6. Nguyen, L., & Pieters, J. (2005). The Trojan horse: survival tactics of pathogenic mycobacteria in macrophages. *Trends in cell biology*, 15(5), 269-276.
 7. Hektoen, L. (1896). The Vascular Changes of Tuberculous Meningitis, Especially the Tuberculous Endarterities. *J Exp Med*, 1(1), 112-63.
 8. Davis, A. G., Rohlwink, U. K., Proust, A., Figaji, A. A., & Wilkinson, R. J. (2019). The pathogenesis of tuberculous meningitis. *Journal of leukocyte biology*, 105(2), 267-280.
 9. Palacios, C. F., & Saleeb, P. G. (2020). Challenges in the diagnosis of tuberculous meningitis. *Journal of Clinical Tuberculosis and Other Mycobacterial Diseases*, 20, 100164.
 10. Colosimo, M., Caruso, A., Nisticò, S., Minchella, P., Cutruzzolà, A., Tiburzi, S. P., ... & Gallelli, L. (2022). A Fatal Case of Tuberculosis Meningitis in Previously Healthy Children. *Pediatric Reports*, 14(2), 175-180.
 11. van Laarhoven, A., Dian, S., Ruesen, C., Hayati, E., Damen, M. S., Annisa, J., ... & van Crevel, R. (2017). Clinical parameters, routine inflammatory markers, and LTA4H genotype as predictors of mortality among 608 patients with tuberculous meningitis in Indonesia. *The Journal of infectious diseases*, 215(7), 1029-1039.
 12. Holbrook, I., Beetham, R., Cruickshank, A., Egner, W., Fahie-Wilson, M., Keir, G., ... & White, P. (2007). National audit of cerebrospinal fluid testing. *Annals of clinical biochemistry*, 44(5), 443-448.
 13. Jeren, T., & Beus, I. (1982). Characteristics of cerebrospinal fluid in tuberculous meningitis. *Acta cytologica*, 26(5), 678-680.
 14. Thwaites, G. E., Chau, T. T. H., & Farrar, J. J. (2004). Improving the bacteriological diagnosis of tuberculous meningitis. *Journal of clinical microbiology*, 42(1), 378-379.
 15. Aulakh, R., & Chopra, S. (2018). Pediatric tubercular meningitis: a review. *Journal of Pediatric Neurosciences*, 13(4), 373-382.
 16. Diallo, A. B., Kollo, A. I., Camara, M., Lo, S., Ossoga, G. W., Mbow, M., ... & Diallo, A. G. (2016). Performance du GeneXpert MTB/RIF® dans le diagnostic de la tuberculose extrapulmonaire à Dakar: 2010-2015. *The Pan African Medical Journal*, 25, 129.
 17. Kohli, M., Schiller, I., Dendukuri, N., Dheda, K., Denkinger, C. M., Schumacher, S. G., & Steingart, K. R. (2018). Xpert® MTB/RIF assay for extrapulmonary tuberculosis and rifampicin resistance. *Cochrane Database of Systematic Reviews*, 8(8), CD012768.
 18. Chakravorty, S., Simmons, A. M., Rowneki, M., Parmar, H., Cao, Y., Ryan, J., ... & Alland, D. (2017). The new Xpert MTB/RIF Ultra: improving detection of Mycobacterium tuberculosis and resistance to rifampin in an assay suitable for point-of-care testing. *MBio*, 8(4), 10-1128. 10.1128/mbio.00812-17.
 19. Tuon, F. F., Higashino, H. R., Lopes, M. I. B. F., Litvoc, M. N., Atomiya, A. N., Antonangelo, L., & Leite, O. M. (2010). Adenosine deaminase and tuberculous meningitis—a systematic review with meta-analysis. *Scandinavian journal of infectious diseases*, 42(3), 198-207.
 20. Xu, H. B., Jiang, R. H., Li, L., Sha, W., & Xiao, H. P. (2010). Diagnostic value of adenosine deaminase in cerebrospinal fluid for tuberculous meningitis: a meta-analysis. *The International journal of tuberculosis and lung disease*, 14(11), 1382-1387.
 21. Pormohammad, A., Riahi, S. M., Nasiri, M. J., Fallah, F., Aghazadeh, M., Doustdar, F., & Pouriran, R. (2017). Diagnostic test accuracy of adenosine deaminase for tuberculous meningitis: A systematic review and meta-analysis. *Journal of Infection*, 74(6), 545-554.
 22. Cort, J. H. (1954). Cerebral salt wasting. *Lancet Lond Engl*, 266(6815), 752-754.
 23. Narotam, P. K., Kemp, M., Buck, R., Gouws, E., van Dellen, J. R., & Bhoola, K. D. (1994). Hyponatremic natriuretic syndrome in tuberculous meningitis: the probable role of atrial natriuretic peptide. *Neurosurgery*, 34(6), 982-988.
 24. Lange, C., Chesov, D., Heyckendorf, J., Leung, C. C., Udawadia, Z., & Dheda, K. (2018). Drug-resistant tuberculosis: an update on disease burden, diagnosis and treatment. *Respirology*, 23(7), 656-673.
 25. Tucker, E. W., Pieterse, L., Zimmerman, M. D., Udawadia, Z. F., Peloquin, C. A., Gler, M. T., ... & Dooley, K. E. (2019). Delamanid central nervous system pharmacokinetics in tuberculous meningitis in rabbits and humans. *Antimicrobial agents and chemotherapy*, 63(10), 10-1128.
 26. Tong, J., Gao, M., Chen, Y., & Wang, J. (2023). A case report about a child with drug-resistant tuberculous meningitis. *BMC Infectious Diseases*, 23(1), 1-6.

Cite This Article: Boudriiya Tamer, El Mamoune Mostaine, Mejdoub Sara, Souly Karim, Zouhdi Mimoun (2024). Child with Rifampicin-Resistant Tuberculous Meningitis: A Case Report. *East African Scholars J Med Sci*, 7(11), 498-502.